

## Cavernous sinus thrombosis caused by Wisdom tooth extraction: a case report.

DrKanishkaNavin Guru<sup>1</sup>, Dr. Rashmi Guru<sup>2</sup>, DrKapil Malviya<sup>3</sup>,  
Dr. Pramod Sharma<sup>4</sup>, Dr Ajay Pillai<sup>5</sup>, DrShreshth Sharma<sup>6</sup>.

<sup>1</sup>Associate Professor, Dept. of Dentistry, Chirayu Medical College & Hospital

<sup>2</sup>Consultant ophthalmologist, Guru's Eye and Dental Surgical Centre

<sup>3</sup>Consultant dental surgeon, Dr. Guru's Eye & Dental Surgical Center

<sup>4</sup>Professor & Head, Department of Dentistry, Chirayu Medical College & Hospital

<sup>5</sup>Professor & Head, Department of Oral and Maxillo-Facial Surgery, PDA

<sup>6</sup>Post graduate resident. Department of Oral and Maxillo-facial Surgery, PDA

Corresponding Author: DrKanishkaNavin Guru

**Abstract:** Cavernous sinus thrombosis (CST) secondary related to maxillofacial infection is a rare clinical squalor. The CST is a rare disease which is reported to have a high rate of morbidity and mortality. Cavernous sinus thrombosis not only presents with symptoms of infections which includes fever, pain and swelling but also with specific findings such as proptosis, chemosis, periorbital swelling, and cranial nerve palsies. The prompt diagnosis and timely treatment of CST is very important for successful outcome. The infection in the maxillofacial region should be given due attention, as to prevent CST. In this case report, we highlighted the role of odontogenic abscess leads to CST, facial palsy, and loss of vision. The odontogenic infection should never be neglected as in rare instances it may cause serious intracranial complication like CST.

**Key words:** Cavernous sinus thrombosis, Cavernous sinus, Sepsis, Dental focal infection

Date of Submission: 10-07-2018

Date of acceptance: 27-07-2018

### I. Introduction

The Cavernous sinus is bilaterally symmetrical sinus located laterally to sella turcica of the sphenoid bone. Many important anatomical structures are related to cavernous sinus such as internal carotid artery, trigeminal ganglion, oculomotor nerve, ophthalmic nerve and abducent nerve<sup>1</sup>.

It's an important sinus for drainage of the brain and communicates with facial veins via angular and ophthalmic veins.<sup>1</sup> As the veins of maxillofacial region and cerebral veins don't have valves, hence any odontogenic or non odontogenic infection in the maxillofacial region can essence to the cavernous sinus.

Cavernous sinus thrombosis was first described by Bright al in 1831. If not treated in the early stage cavernous sinus thrombosis can potentially be fatal.<sup>2,3</sup> As cavernous sinus thrombosis is fatal disease and if not aggressively managed, the mortality rate of cavernous sinus thrombosis is less than 30%. As per the literature review, many pathological conditions like sinusitis, orbital cellulites, para pharyngeal abscess are the main causes of cavernous sinus thrombosis. Odontogenic cause of cavernous sinus thrombosis has been reported low<sup>3</sup> in the literature. In this article, we present an unusual and rare case of cavernous sinus thrombosis after surgical disimpaction of the maxillary third molar<sup>3</sup>.

### Clinical Case

21 year old male, reported with chief complaint of swelling and pain over left side of face, orbit and submandibular region. (Fig.1)

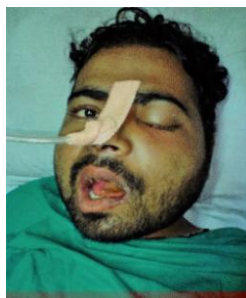
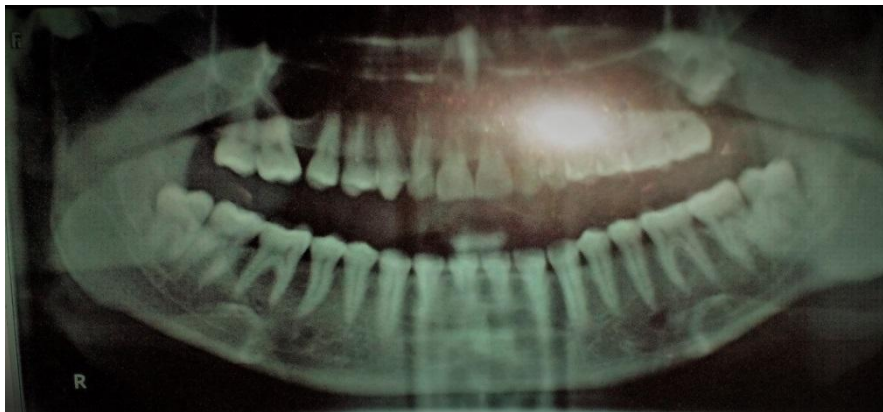
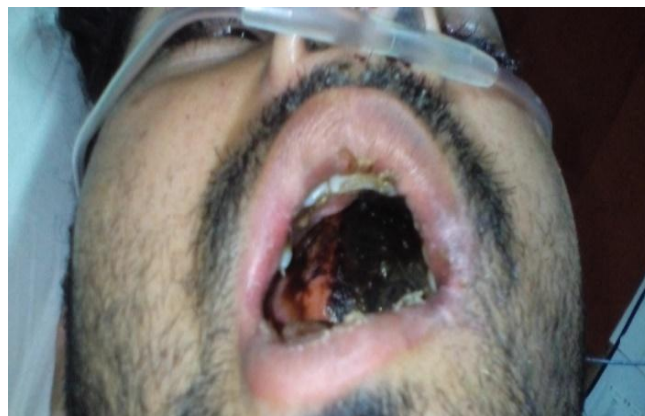Figure 1 : Facial palsy

Circum orbital edema was to a extent that the patient was not even able to open the left eye. Patient gives history of surgically extracted left impacted maxillary third molar in a local clinic one week ago. Preoperative OPG was available with the patient which was showing left impacted maxillary third molar.(Fig 2)



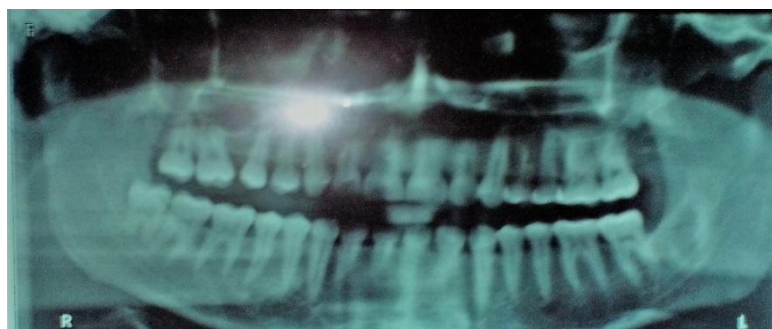
**Figure 2 : showing impacted left maxillary third molar**

On clinical examination the swelling was hard, generalized in the left check region and was febrile. On intraoral examination purulent discharge was present from the surgical socket and mucosal necrosis was present at the posterior region of hard palatal .(Fig. 3)with foul smell.



**Figure 3 : palatal necrosis**

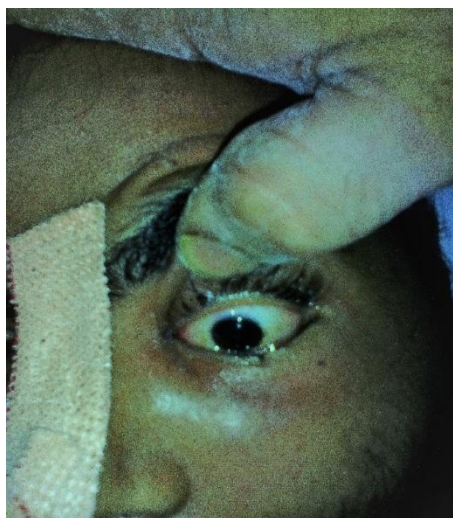As per our surgical center protocol we have taken a sample of pus discharge for culture and antibiotic sensitivity and sample was immediately sent. Post-operative OPG was taken where we noticed that the impacted maxillary third molar was indeed surgically removed(Fig 4).



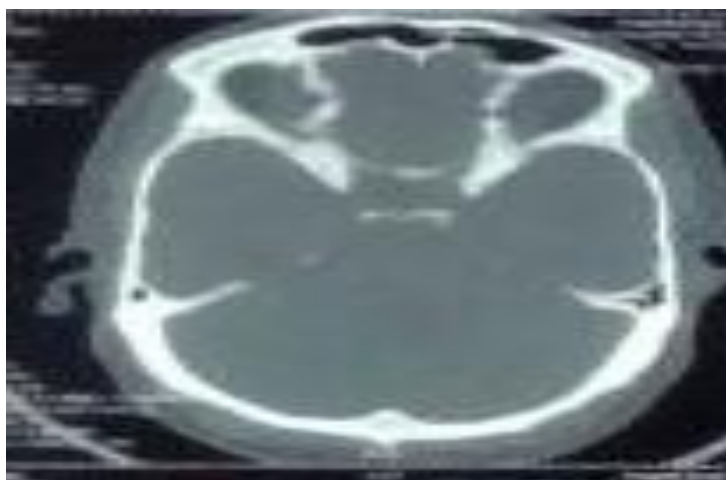
**Figure 4 :Post-operative OPG**

Empirical antibiotics, analgesics, antipyretic medications and i.v fluids were started and a reference was made to the ophthalmologist for opinion. Ophthalmologist inspected the patient and vision was found to be 6/6, chemosis, proptosis, with unilateral periorbital edema and ophthalmoplegia was present. Later on the patient presented with left sided facial palsy. Ophthalmologist reviewed the patient and she noted that the patient

developed diplopia, IOP was raised and vision was decreased as 4/6 in left eye. (Fig 5). Soon we concluded that patient developed secondary complication as CST. A call was made to neurologist who took a CT SCAN showing elevated Intra-cranial pressure and upon correlated with other symptoms, he confirmed that patient has developed CST. Awaiting culture and antibiotic sensitivity report reveals presence of *Pseudomonas Klebsiella*. Routine Blood lab findings revealed the following results: CBC, Total leukocyte count: 20,000/mm<sup>3</sup>, Differential Leukocyte Count P80L18E1M1, ESR:46 mm/h and Complete Metabolic Panel with serum sodium 136 meq/l, serum potassium 3.4 meq/l, BUN20 mg/dl, serum creatinine 1.6 mg/dl, and random blood glucose 106 mg/dl. This report parameter reveals that patient going into septic shock.



**Figure 5**



**Figure 6**

**Figure 5 Diplopia, Dilated pupil, proptosis, periorbital ecchymosis, and diplopia of the left eye.  
Figure 6: CT SCAN showing elevated Intra-cranial pressure**

As the disease was diagnosed, the patient was immediately taken up for debridement and curettage of the infected socket under general anesthesia. Postoperatively patient was admitted under intensive care unit under the emergency medicine department. Unfortunately, latter on the patient died due to complications of the disease, which included meningitis, sepsis, and shock.

## II. Discussion

Septic cavernous sinus thrombosis can be defined as thrombophlebitis involving the cavernous sinus which is secondary to Odontogenic and non Odontogenic infection origin.<sup>4</sup> The primary source of infection can be odontogenic or non odontogenic origin in the maxillofacial region. It has been reported that to the average of 7% of cavernous sinus thrombosis is of Odontogenic origin<sup>1</sup>, as there is direct communication with facial veins and pterygoid plexus of vein to the cavernous sinus. As these veins don't have any valves, hence any infection in the maxilla facial region can easily ascends towards the cavernous sinuous. Hence the Dentist or maxillofacial surgeon or any surgeons operating in the maxillofacial region should be very careful, not to cause any trauma during the procedure in maxilla or giving posterior superior alveolar nerve block.<sup>1</sup> Any use of contaminated needle or any instrument can cause secondary infection in this region. The surgeons must use extreme care to manage a open wound of road traffic accident in this region. In our study the primary source of infection was surgical removal of left impacted maxillary third molar.<sup>1</sup> The patient develops swelling following second day of the extraction. The signs of cavernous sinus thrombosis usually is a result of congestion in venous drainage and usually the mode of onset is acute, proptosis, headache and unilateral periorbital edema. All signs of inflammation can also be noticed in this disease. The diagnosis of cavernous sinus thrombosis is usually done on clinical symptoms, pus culture and radio graphical investigations. Compared to CT scan, MRI and MR venography are more sensitive for proper diagnosis of Cavernous sinus thrombosis.<sup>4</sup> Usually the patient with cavernous sinus thrombosis, have leucocytosis and in this present case leukocyte count: 20,000 cub/mm<sup>3</sup>. As soon as we achieve diagnosis, under empirical antibiotics coverage, surgery to remove primary source of infection should be initiated.

To conclude, after the breakthrough of antibiotics and imaging techniques still the mortality rate of cavernous sinus thrombosis remains high and when prompt management is not initiated can lead severe life threatening complications.

As soon as the disease is diagnosed the primary step of management is to immediately initiate aerobic and anaerobic antibiotics and to identify the primary source of infection. Surgery should immediately be performed to remove the primary source of infection.

Take home message:

1. Cavernous sinus thrombosis is a rare disease.
2. The morbidity and mortality rate remains high.
3. Unethical practices or not following proper principles of sterilisation and wound management by practitioners and a lack of awareness of dental health in rural areas can lead to severe life threatening.
4. Empirical antibiotic therapy and emergency surgical management must be considered as soon as the disease is diagnosed.

#### References:

- [1]. Alves N, Deana NF. *Int J ClinExp Med* 2016; 9(3):5301-5307. Available from: <http://www.ijcem.com/files/ijcem0018632.pdf> (Accessed on March 2, 2018).
- [2]. Yeo G-S, Kim HY, Kwak E-J, Jung Y-S, Park H-S, Jung H-D, et al. Corrigendum. Cavernous sinus thrombosis caused by a dental infection: a case report. *J of the Korean Assoc of Oral and Maxillofac Surg.* 2014 Oct; 40(4):195-198. (Accessed on Feb 2, 2018). doi:10.5125/jkaoms.2014.40.4.195.
- [3]. Verma R, Junewar V, Singh RK, Ram H, Pal US. Bilateral cavernous sinus thrombosis and facial palsy as complications of dental abscess. *Natl J Maxillofac Surg* 2013;4:252-255. Available from: <https://www.njms.in>, accessed on March 12, 2017). doi:10.4103/0975-5950.127664.
- [4]. Dagher GA, Harmouche E, Jabbour E, Bachir R, Zebian D, Chebl RB, et al. Sepsis in hemodialysis patient. *BMCEmergeMed* 2015; 15(30). Available from: [https://www.researchgate.net/publication/283247114\\_Sepsis\\_in\\_hemodialysis\\_patients](https://www.researchgate.net/publication/283247114_Sepsis_in_hemodialysis_patients), accessed on May 5, 2018). doi:10.1186/s12873-015-0057-y.
- [5]. Aggrawal K, Rastogi S, Joshi A, Kumar A, Chaurasia A, Prakash R, et al. Cavernous sinus thrombosis following dental extraction: a rare case report and forgotten entity. *J Korean Assoc Oral Maxillofac Surg* 2017; 43(5). Available from: <http://www.jkaoms.org/journal/view.html?volume=43&number=5&page=351>, (accessed on April 2, 2018).
- [6]. Umamaheswara RV, Agrawal A, Hegde KV, Srikanth V and Sahith RK. Massive infarction and cavernous sinus thrombosis: an uncommon complication of tooth extraction. *Romanian Neurosurg* 2014; 21: 501-505.

DrKanishkaNavin Guru " Cavernous sinus thrombosis caused by Wisdom tooth extraction: a case report. "IOSR Journal of Dental and Medical Sciences (IOSR-JDMS), vol. 17, no. 7, 2018, pp 44-47.