

Correlation Of Cytology, Radiology And Histopathology In Suspected Cases Of Breast Cancer

Dr Rajiv Kamal Gupta

Corresponding Author: Dr Neetika Kaushal

Abstract

Background: Breast cancer is the most common cancer in females all around the world.. It is of utmost importance that all positive cases are diagnosed at the earliest to decrease its morbidity and mortality. Different techniques including mammography/sonomammography, fine needle aspiration cytology and biopsy are used to diagnose breast cancers. With an early diagnosis the management can be early and hence effective.

Objectives: 1.To evaluate the role of cytology and radiology in evaluating patient with breast mass.

2.Cytological, Radiological and Histopathological correlation in diagnosis of suspected breast cancer cases.

3.To compare efficacy of individual diagnostic modality- cytology, histopathology and radiology.

Material and Methods: The study was conducted in 100 patients suspected of breast cancer. In each patient clinical presentation, cytology findings, radiology findings and biopsy findings were compared with the final diagnosis of histopathology of received mastectomy specimen or lumpectomy. Physical and clinical examination of lesion was performed in all cases.

Keywords: Breast cancer, FNAC, Biopsy, mammography and sonomammography.

Date of Submission: 10-07-2018

Date of acceptance: 27-07-2018

I. Introduction

Breast cancer is the most common cancer in females in the world and one of the leading cause of death in women worldwide. It affects about 12% of women worldwide.⁽¹⁾ Breast cancers usually are epithelial tumors of ductal or lobular origin.⁽²⁾ Most breast cancer suspected cases present as palpable lump, inflammatory lesions, nipple secretions or mammographic abnormalities. For preoperative radiological diagnosis in breast cancer suspected patients by mammography and sonomammography is done which is useful, easy and early diagnostic tool of mammary carcinoma in conjugation with clinical examination and fine needle aspiration cytology which is also one of the best, easy, economical and reliable diagnostic.⁽³⁾ Though radiology and cytology findings are reliable but biopsy of the lump is to be done for definitive diagnosis. Combined diagnostic approach is followed comprising of clinical examination, radiology, FNAC and biopsy in suspected cases of breast cancers which improves the diagnostic efficiency of breast cancers and reduce morbidity and mortality.

II. Material And Methods

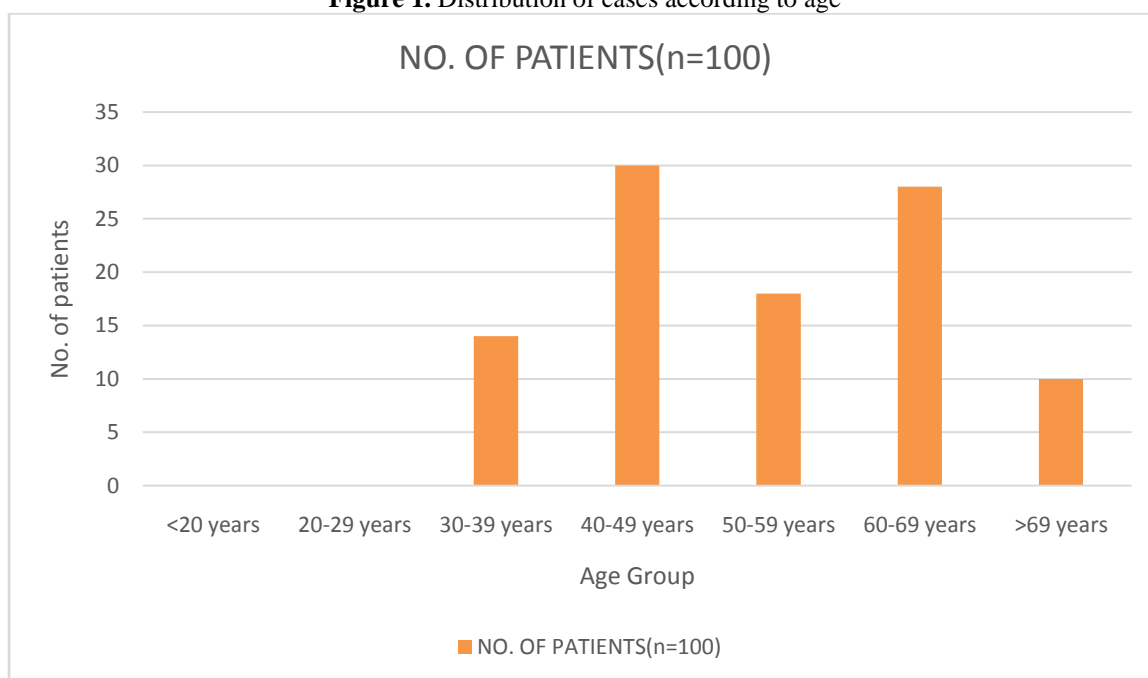
A study was carried out in 100 patients attending outpatient department or admitted in wards of Rajindra Hospital, Patiala who were suspected of breast cancer clinically. Each patient was evaluated for the clinical presentation, radiological findings, FNAC findings and biopsy findings. In each case history was recorded with an emphasis on family history, history of hormonal intake and reproductive history. Physical and clinical examination of lesion was done. The patients underwent Mammography on allergens MAM-VENUS mammography machine. The standard mammographic examination consisted of Mediolateral view and Craniocaudal view of breast. Ultrasonomammography was also done of the patients. The scans included information regarding four features of breast (1) shape- round/oval or irregular (2) margins- circumscribed or non circumscribed (3) width- AP ratio > 1.4 or =1.4 (4) echogenicity- hypoechoic/isoechoic or hyperechoic. Provisional diagnosis was made and mass lesion was categorized according to BIRADS criteria⁽⁴⁾. In this study BIRADS IV was taken suspicious. Fine needle aspiration was performed inserting a 22 gauge needle in breast lump on a 10 cc syringe and Franzenhandle Needle containing aspirated material was quickly detached from the syringe. Air was drawn into the syringe and the aspirated material was expressed on clean glass slides. Smears were prepared, air dried and then fixed in methanol and stained with MGG. One slide was immediately fixed in 95% alcohol and stained with PAP⁽⁵⁾. Malignancy was reported on cytology based on various morphological characteristics of cells (1) abnormal grouping of cells (2) decreased mutual adhesiveness (3) changes in nucleus (4) increased/abnormal mitosis (5) variation in size and shape of cells (6) abnormal cytoplasmic inclusions. For histopathology examination specimen received as core biopsy or excisional biopsies were examined macroscopically and for microscopic examination blocks of tissue were made and processed and stained with

routine hematoxylin and eosin stain. The final surgically resected lumpectomy or mastectomy specimen was also examined macroscopically. Any lesion, ulcer, growth was identified, overlying skin, posterior surgical margin and nipple areola complex was also grossly examined and intramammary lymph node status was also noted. Modified Bloom Richardson Scoring was done of final mastectomy specimen and grading was done. The Cytology, Mammography/ Sonomammography and biopsy findings and efficacy were evaluated individually and correlated with each other. The histopathology finding of mastectomy specimen was compared with individual diagnostic modality findings.

III. Results

In this study 100 patients were taken who were clinically suspected of breast cancer. All cases were evaluated clinically. Age of the patients ranged from 30-90 years. Out of 100 cases studied most of the breast lesions i.e. 30% were seen in age group 40-49 years, 28% in 60-69 years, 18% in age group 50-59 years, 14% in 30-39 years and 10% in >69 years .

Figure 1. Distribution of cases according to age



In all patients family history of breast cancer, history of intake of hormonal intake, reproductive history was taken. Out of 100 cases 11% had family history of breast cancer in first degree relatives out of which 5 were mothers and 6 were sisters and 6% had history of hormone intake mainly in form of oral contraceptive pills.

In this study , patients presented with multiple complaints. Most common presenting symptom was breast lump seen in 95 cases followed by pain in breast in 18 cases. Nipple discharge was seen in 12 cases, ulcer over the breast in 08 cases and fungating growth over breast in 2 cases.

Table-1. Distribution of cases according to their chief complaints/ clinical presentations(multiple responses) (N= 135)

CLINICAL PRESENTATION	NO. OF PATIENTS(n=100)	PERCENTAGE
LUMP	95	95%
NIPPLE DISCHARGE	12	12%
PAIN	18	18%
ULCER	08	08%
FUNGAL GROWTH	02	02%

Figure 2. Distribution of cases according to clinical presentation in suspected cases of breast cancers

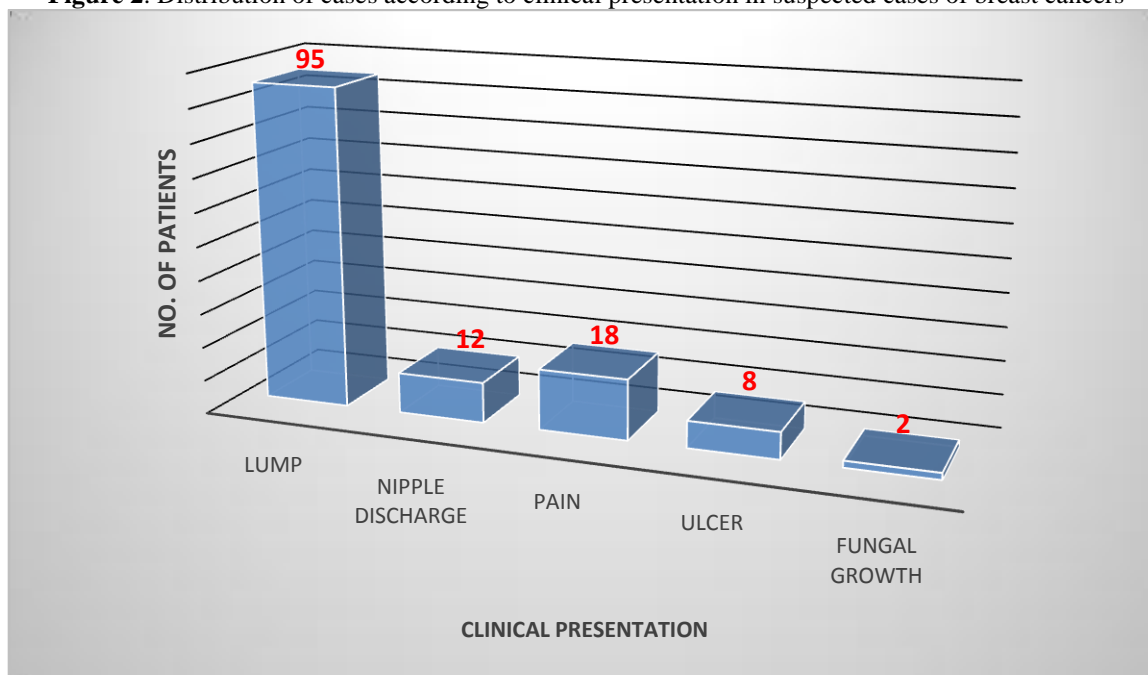


Table-2. Distribution of cases according to side of breast involved

SIDE	NO. OF CASES	PERCENTAGE
RIGHT BREAST	53	53%
LEFT BREAST	47	47%
BLATERAL	00	0%
TOTAL	100	100%

In this study right side of breast was involved in 53 cases and left side in 47 cases.

Table – 3. Distribution of cases according to the radiological diagnosis

RADIOLOGICAL DIAGNOSIS	NO. OF PATIENTS	PERCENTAGE
BENIGN	09	09%
SUSPICIOUS	39	39%
MALIGNANT	47	47%
INADEQUATE	05	05%
TOTAL	100	100%

In this study in radiological diagnosis by mammography and sonomammography in 100 cases, 9% cases were diagnosed benign out of which 1 case in category BIRADS II and 8 cases in BIRADS III. Thirty nine cases in BIRADS IV which were diagnosed suspicious of malignancy and 47% diagnosed malignant out of which 45 cases under BIRADS V and 2 in BIRADS VI. In 5% cases sonomammography/ mammography was not done and this category was labeled inadequate.

Table -4 Distribution of cases on the basis of Cytological diagnosis

CYTOLOGICAL DIAGNOSIS	NO. OF PATIENTS	PERCENTAGE
BENIGN	13	13%
SUSPICIOUS	12	12%
MALIGNANT	71	71%
INADEQUATE	02	02%
TOTAL	100	100%

In this study, FNAC diagnosed 13% cases benign with findings of inflammatory pathology in 2 cases, 2 were fibroadenoma breast and 5 cases diagnosed fibrocystic disease of breast, 2 cases of duct ectasia and 2 cases of Phyllodes tumor. Malignancy was reported in 71% cases on FNAC, 9 cases under premalignant category diagnosed as ductal carcinoma in situ (DCIS), Ductal carcinoma in 63 cases and lobular carcinoma in 1 case. Premalignant lesions were taken under malignant category for this study. In 12% cases diagnosis was suspicious out of which 11 cases were diagnosed Atypical ductal hyperplasia and 1 case of ductal dysplasia. Out of 100 cases, 2% cases were diagnosed inadequate due to improper sampling or excessive inflammation, the smears were inconclusive.

Table -5.Distribution of cases according to the biopsy findings

BIOPSY DIAGNOSIS	NO. OF PATIENTS	PERCENTAGE
BENIGN	06	06%
SUSPICIOUS	05	05%
MALIGNANT	85	85%
INADEQUATE	04	04%
TOTAL	100	

In this study , on biopsy 5% cases were diagnosed suspicious due to few atypical cells seen on microscopy. Benign cases were reported in 6% cases comprising of 4 cases of proliferative breast disease, duct ectasia in 1 case and benign Phyllodes tumor in 1 case. Malignancy was diagnosed in 85% cases out of which 81% cases were diagnosed infiltrating ductal carcinoma, 1 was diagnosed medullary carcinoma and 1 case of premalignant condition DCIS and 2% cases were diagnosed Malignant Phyllodes tumor. Biopsy was labeled inadequate in 4% cases.

In this study , on histopathological examination of lumpectomy or mastectomy specimen, 6% cases were diagnosed benign , out of which 2 cases were Fibrocystic disease with adenosis, 1 case of duct ectasia, 1 cases of Fibroadenosis with intraductal papilloma , 1 case of proliferative breast disease and 1 case reported as benign Phyllodes tumor. Malignancy was reported in 94% cases, 83% were diagnosed Ductal carcinoma breast, 2 % diagnosed of Lobular carcinoma breast , Medullary carcinoma in 2% cases. Invasive papillary carcinoma was diagnosed in 1%, Mucinous carcinoma in 1% and Apocrine carcinoma in 2% cases. Malignant Phyllodes tumor in 2% cases and DCIS in 1% case were also considered in malignant lesions of breast.

Table-6.Distribution of cases on the basis of final diagnosis obtained from post operative surgical resection

FINAL DIAGNOSIS	NO. OF PATIENTS	PERCENTAGE
FIBROCYSTIC DIEASE WITH ADENOSIS	02	02%
DUCT ECTASIA	01	01%
PROLIFERATIVE BREAST DISEASE	01	01%
FIBROADENOSIS WITH INTRADUCTAL PAPILLOMA	01	01%
BENIGN PHYILLODES	01	01%
MALIGNANT PHYILLODES	02	02%
DCIS	01	01%
DUCTAL CA	83	83%
LOBULAR CA	02	02%
MUCINOUS CARCINOMA	01	01%
APOCRINE CARCINOMA	02	02%
MEDULLARY CARCINOMA	02	02%
INVASIVE PAPILLARY CARCINOMA	01	01%
TOTAL	100	

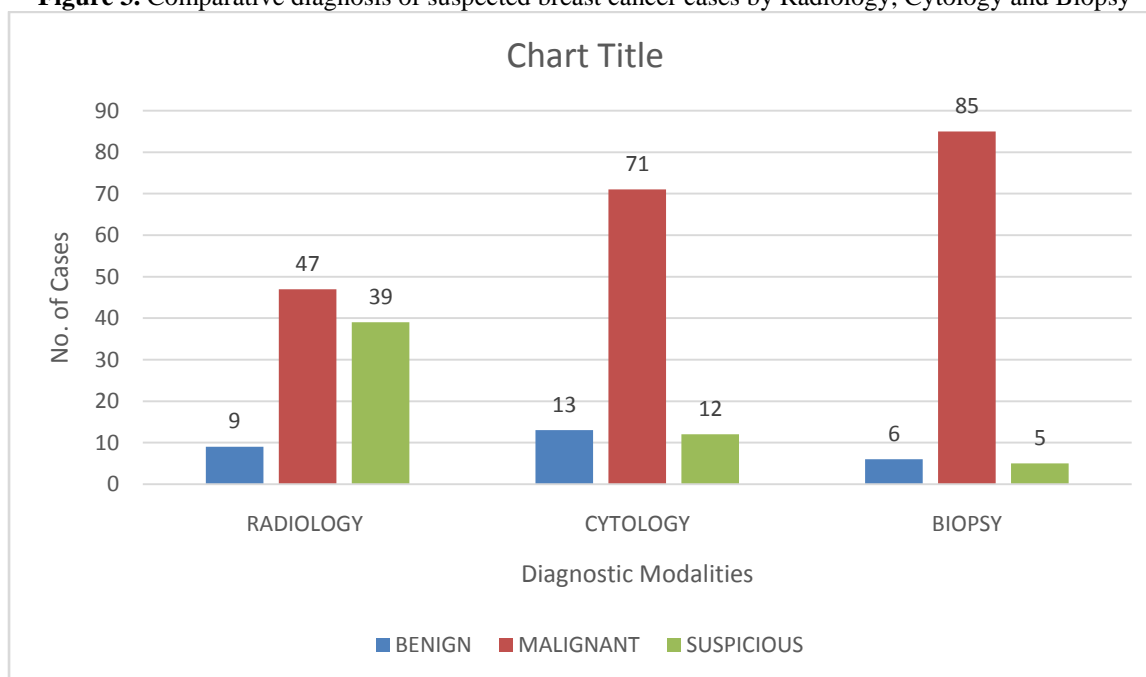
In this study in mastectomy specimens on histopathogy, Modified Bloom Richardson grading was done. Out of 100 cases ,24% in MBR grade I, 48% in MBR grade II, 08% in MBR grade III and in 20% cases MBR was not calculated.

Table-6.Comparison of Diagnostic Modality with final diagnosis of histopathology

DIAGNOSTIC MODALITY	BENIGN	MALIGNANT	SUSPICIOUS	INADEQUATE	TOTAL
RADIOLOGY	9	47	39	5	100
CYTOLOGY	13	71	12	2	100
BIOPSY	06	85	5	4	100

Chi square value was 50.45 with degree of freedom 6 and p value of <0.000001(highly significant).

Figure 3. Comparative diagnosis of suspected breast cancer cases by Radiology, Cytology and Biopsy



In this study , out of 100 cases , 47 were diagnosed malignant on radiology, 71 on cytology and 85cases diagnosed malignant on biopsy. Six cases were identified benign on biopsy whereas 9 cases on radiology and 13 on cytology were diagnosed benign. On radiology 39 cases were diagnosed suspicious whereas on cytology 12 cases were suspicious and 5 were suspicious of malignancy on biopsy. Biopsy was highly efficacious modality followed by cytology and radiology was less efficacious. Chi square value was 50.45 with degree of freedom 6 and p value of <0.000001 (highly significant). Ninety four cases were diagnosed malignant after lumpectomy or mastectomy. Efficacy of radiology was 50%, FNAC was 75.5% and biopsy was 90.4% in suspected cases of breast cancers.

IV. Discussion

Breast cancer is one of the most prevalent cancer in the world among women. FNAC of breast lumps is an accepted and established method of determining the nature of breast lumps with a high degree of accuracy. Application of Fine Needle Aspiration Cytology for the diagnosis of palpable breast masses was first introduced by Martin and Ellis in 1930.⁽⁶⁾ Ultrasound is also helpful in guiding FNAC or biopsies and more reliable in evaluation of dense breasts. The purpose of the this study was to correlate cytological, radiological and biopsy findings in breast lesions suspected to be breast cancer. In this study the age range of patients was 30-90 years which was in correlation to age range of 35-86 years conducted in study by Sarangan et al.⁽⁷⁾ In the study conducted by Tiwari et al⁽⁸⁾ 35 patients complained of mobile breast lump, 12 with breast pain, 5 patients felt lump, 3 with nipple discharge and nipple retraction and lump with fever in two patient each which was in correlation with this study.

In the study by Sarangan et al ⁽⁷⁾cytologically there were 15 case of malignancy and suspicious for malignancy .Histopathologically they were reported as ductal carcinoma in situ, infiltrating ductal carcinoma, lobular and papillary carcinoma. There were 35 benign cases reported as simple cyst, duct ectasia , mastitis, galactoceles, phyllodes. On histopathology these cases turned out to be malignant. Out of 50 cases in the study 41 were detected benign (BIRADS I and II) by ultrasound. Carcinoma of the breast was histologically found in 14 cases out of which 9 are correctly diagnosed by radiology, thus sensitivity of 56.25%. there was significant difference between cytology and radiology in detecting breast disease. There is significant difference between individual modality of diagnosis and their combination. This is in correlation with the present study . In the study by Tikku et al ⁽⁹⁾ ninety eight patients (91.58%) had a single lump in either breast . Nine patients (8.41%) had multiple lumps. Percent positivity on CNB was 44.85% while that on FNAC was 30.84%. Thus CNB detected 14.01% more malignant cases than FNAC. Suspicious cases on FNAC was 38.31% and on CNB was 2.80%

In the study conducted by Rupom et al ⁽¹⁰⁾ out of 54 ductal carcinoma (NOS), 11 were grade I, 43 were grade II. No cases diagnosed grade III. Statistically analysis by Chi Square test showed that cytological grade significantly correlated with histological grade, P<0.001. In study conducted byKanhoush et al⁽¹¹⁾ out of 7727,

489 aspirates(6%) were classified as cytologically 'atypical' or 'suspicious'. Among the 'atypical' aspirates, 118(52%) yielded malignant findings on histological evaluation most commonly infiltrating ductal carcinoma (n=87, 74%). Among suspicious aspirates 135(83%) yielded malignant findings on histological analysis. The most common benign diagnosis in both atypical and suspicious aspirates was proliferative fibrocystic change followed by fibroadenoma..this is in correlation with the present study.

In the study by Kim et al⁽¹²⁾ cases of FNAC was with pathologic confirmation .the results were ratios for malignant, suspicious, atypical, benign, and unsatisfactory cytological analysis were 98.71, 5.48, 1.09, 0.07 and 0.55 respectively. The absolute and complete sensitivities for malignant lesions were 64.5% and 90.3% respectively. The predictive value for malignant cytological diagnosis was 98.4%.

In the study conducted by Ibikunle et al⁽¹³⁾ FNAC correlation with histopathology findings in breast lumps in which 289 FNAC of breast lumps was done. There were 161 cases of FNAC with corresponding tissue for histopathology correlation giving biopsy rate of 55.7%. The sensitivity of FNAC in determining the final histologic diagnosis was found to be 99.4% while the specificity was 100%. FNAC was able to determine final histologic diagnosis in 86.3% of cases.

In the study by Shweta et al⁽¹³⁾ for correlation between cytological and histological diagnosis .Concordance rate between cytological and histological grade was 78%. The coefficient of correlation of cytology and histopathology grade was 0.804 and P value was <0.001 which indicated a strong correlation and significant association between the two grades. In the study by Michael et al⁽¹⁴⁾ for pathological diagnostic correlation with breast imaging findings. In aggregate , a radiological pathological correlation was found in 94.9% . Significant difference in the correlation rates were discussed at an interdepartmental , multidisciplinary conference (P<0.001). No significant difference was found in correlation rates whether surgeons or radiologist performed biopsy, weather cores with calcification were identified by any method, and whether lab had one or more pathologist.

References:

- [1]. American Cancer Society. Cancer Facts and Figures 2016. Atlanta, Ga Available as : <http://www.cancer.org.acsps>047079.pdf>
- [2]. Lester SC. The Breast. In: Kumar V, Abbas AK, Fausto N, editors. Robbins and Cotran Pathologic Basis of Disease. 7th ed. Philadelphia: Elsevier; 2004. p.1129.
- [3]. Wilson SL and Ehrmann RL. The cytological diagnosis of Breast Aspiration. Acta cytological 1978;22:6.
- [4]. Breast Imaging Reporting and Data System (BI-RADS) 4th edition. Reston Vo: American college of Radiology,2003. Available as-
<http://radiopaedia.org/articles/breast-imaging-reporting-and-data-system-birads>
- [5]. Linsk JA, Franzen S. Aspiration biopsy. In: Linsk JA, Franzen S, editors. Clinical aspiration cytology. 2nd ed. Philadelphia: JB Lippincott: 1983.p-267-79.
- [6]. Martin HE, Ellis EB. Biopsy by needle puncture and aspiration. Ann Surg 1930;92:169.
- [7]. Sarangan.A.R.Geetha, Sahaya, B. Pushpa- Study of histopathology correlation of breast mass with radiology and cytology findings. IOSR. e-ISSN:2279-0853,p-ISSN: 2279-0861. Volume 16, Issue 3 vers.IX(March 2017).
- [8]. Tiwari P, Ghosh S and Aggarwal V .Diagnostic accuracy of mammography and ultrasonography in assessment of breast cancer.International journal of contemporary medical research 2017;4(1):81-83.
- [9]. Rupom T, Choudhary T, Banu S. Correlation of cytologically malignant cases with their respective histopathological findings. BSMMU J 2011; 4(2):60-64
- [10]. Kanhoush R, Jorda M, Gome 2- Fernandez C, Wang H, Mirza beige M, Ghorab Z et al. 'atypical' and 'suspicious' diagnosis in breast aspiration cytology. Cancer .2004;102(3):164-7.
- [11]. Kim A, Lee J, Choi JS, Won NH, Koo BH. FNAC of Breast. Experience at an outpatient basic clinic. ActaCyto. 2000;44(3):361-7.
- [12]. Ibikunle D, Omotayo J, Ariyibi O .FNAC correlation with histopathology findings. Ghana Med J.2017 Mar; 51(1):1-5.
- [13]. Pal S and Gupta M. Study of correlation between cytological and histological grade. J Cytol.2016 Oct Dec:33(4):182-186.
- [14]. Michael O. Idowu, Linday Bonner Hardy, Rhona J. Souers, Raouf E. Nakhleh. Pathologic diagnostic correlation with breast imaging findings: A College of American Pathologists Q – Probes study of 48 institutes. Archives of Pathology and Laboratory Medicine : January 2012, Vol .136, No. 1,pp . 53-60.

Dr Rajiv Kamal Gupta ,DrNeetikaKaushal"Correlation Of Cytology, Radiology And Histopathology In Suspected Cases Of Breast Cancer."IOSR Journal of Dental and Medical Sciences (IOSR-JDMS), vol. 17, no. 7, 2018, pp48-53.