

## Observational Study of Clinical & Epidemiological Profile of Patients with Proposes At RIMS, Ranchi.

Umesh kumar<sup>1</sup>, Sindhu kumari<sup>2</sup>

<sup>1</sup>(Ophthalmology, RIMS/Ranchi University, India)

<sup>2</sup>(Ophthalmology, RIMS/Ranchi University, India)

Corresponding Author: Umesh kumar

### Abstract:

**Aim:** - To study the clinical and epidemiological profile of patients with proptosis at RIMS,Ranchi.

**Methods:**-A total of 43 patients presenting in emergency & outpatient department of RIO, RIMS, Ranchi were included. All patients were evaluated for detailed history and clinical examination. The evaluation were done including the demographic data of the patient, complete history, general examination, detailed ophthalmological examination of both eyes, slit lamp examination, non-invasive & special investigations.

Final diagnosis was based on clinical, histopathological, laboratory & radiological findings.

**Results:** - Proptosis is most common in males & tribal populations. Diminished vision was most common presenting symptom. The most common cause of proptosis was inflammatory diseases seen in 46.5% of cases. CT scan was most common modality of investigation seen in 67.5% of cases.

**Conclusion:**-Proptosis is a multidisciplinary problem &requires collaboration of different specialities. There are challenges related to patients high default rate. There should be proper education and counselling to the patient about possible outcomes, to reduce default rate & encourage them for proper management.

Date of Submission: 11-08-2018

Date Of Acceptance: 25-08-2018

### I. Introduction

Proptosis by definition means → passive forward protrusion of the eyeball beyond the orbital margin. Proptosis of more than 21mm or more than 2mm asymmetry between the two eyes is abnormal.

The condition presents a diagnostic challenge requiring deliberate and thoughtful investigation. Clinical findings may provide clues to possible etiology with radiological imaging playing a pivotal role in arriving at a diagnosis and histology providing the definitive diagnosis in relevant cases.

Great majority of cases of proptosis are unilateral where local pathology is the primary cause whereas bilateral cases usually are the manifestations of systemic diseases. Based on direction of proptosis, the proptosis may be axial or non-axial. After taking history and a thorough clinical examination, there invariably remain enough uncertainties to require consultation from other specialists.

This study is undertaken to know the clinical & epidemiological profile of patient with proptosis at RIO, RIMS, Ranchi occurring in this eastern belt of India. This is a prospective observational hospital based study.

### II. Materials and Methods

This study is undertaken to know the clinical and epidemiological profile of patients with proptosis and various modalities for the diagnosis of patients with proptosis.

The present study was carried out on the patient attending emergency and outpatient department of Regional institute of Ophthalmology, Rajendra Institute of Medical Sciences, Ranchi. A total of 43 patients were taken up for the study, during the period from October 2015 to October 2017.

All the information was collected in a predesigned and pre-tested proforma. The data collected were analysed using statistical package for social studies (SPSS) version 20.0. Categorical and numerical variables were analysed as percentage. 52 eyes of 43 patients were evaluated.

All proptosis cases presenting in emergency and outpatient department of RIO, RIMS, Ranchi were included.

Cases with glaucoma, cataract, any systemic associations like diabetic retinopathy, hypertensive retinopathy, previous retinal detachment, all retinal pathologies affecting visual acuity and visual field, debilitated, bedridden & uncooperative patients were excluded from the study.

All patients were evaluated for detailed history and clinical examination. The evaluations were done including the demographic data of the patient, complete history, general examination, detailed ophthalmological

examination of both eyes. Slit lamp examination and investigation like detailed fundus examination, Tonometry, otorhinological examination, hematological and histopathological studies.

Non invasive techniques were plain x-ray of orbit and skull, orbital ultrasound (B-scan), CT & MRI of brain with special reference to orbits (in selected cases). No invasive investigations were done.

Proptosis was measured by a group of instruments called proptometer or exophthalmometer. Final diagnosis was based on clinical, histopathological, laboratory and radiological findings. Based on the final diagnosis, treatment was planned. Cases which required further evaluation and management were referred to higher centers and patient was asked to follow-up.

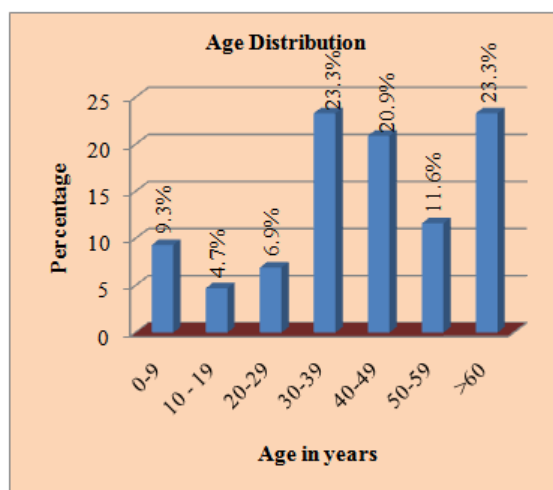
### III. Results

Out of approximately 49 thousands OPD and Emergency cases 43 cases of proptosis were seen in tertiary care centre, the reported incidence of proptosis is noted to be 0.8%.

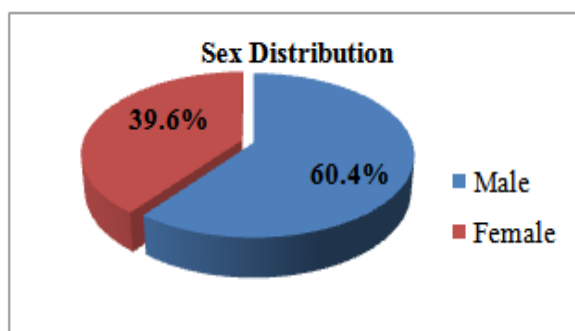
Distribution of patients based on age

**Table – I: Age distribution**

S. No.	Age in years	Number of cases	Percentage
1	0-9	4	9.3
2	10-19	2	4.7
3	20-29	3	6.9
4	30-39	10	23.3
5	40-49	9	20.9
6	50-59	5	11.6
7	>60	10	23.3
	Total	43	100



Distribution of patients based on sex



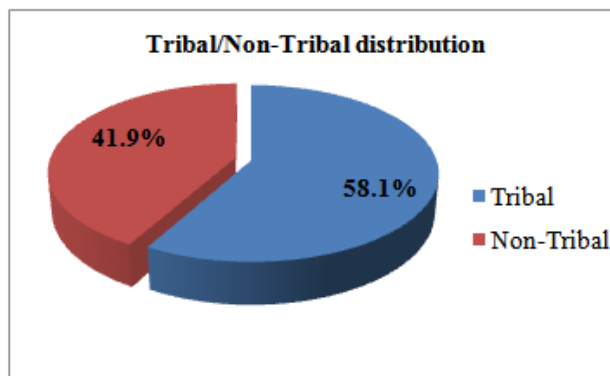
Distribution of patients based on sex

**Table –II: Sex Distribution**

S. No.	Sex	Number of cases	Percentage
1	Male	26	60.4
2	Female	17	39.6
	Total	43	100

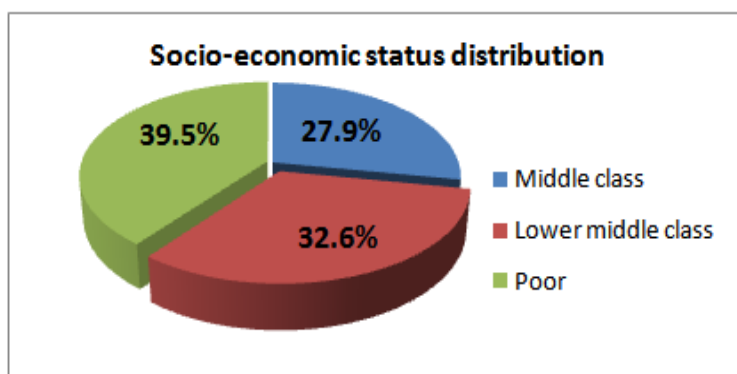
**Table – III: Tribal/Non-Tribal distribution**

S. No.	Patient	Number of cases	Percentage
1	Tribal	25	58.1
2	Non-Tribal	18	41.9
	Total	43	100



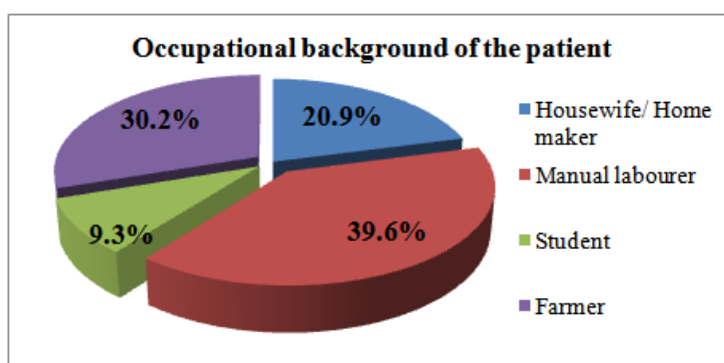
**Table – IV: Socio-economic status distribution**

S. No.	Socio-economic status	Number of cases	Percentage
1	Middle class	12	27.9
2	Lower middle class	14	32.6
3	Poor	17	39.5
	Total	43	100



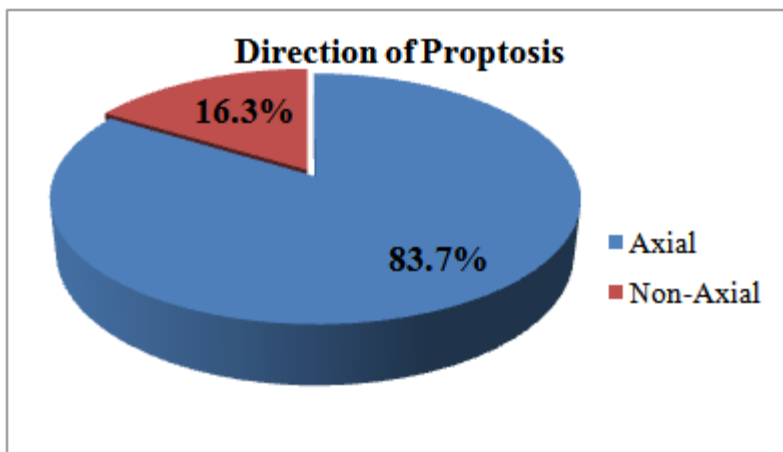
**Table – V: Occupational background of the patient.**

S. No.	Occupation	Number of cases	Percentage
1	Housewife/ Home maker	09	20.9
2	Manual labourer	17	39.6
3	Student	04	9.3
4	Farmer	13	30.2
	Total	43	100



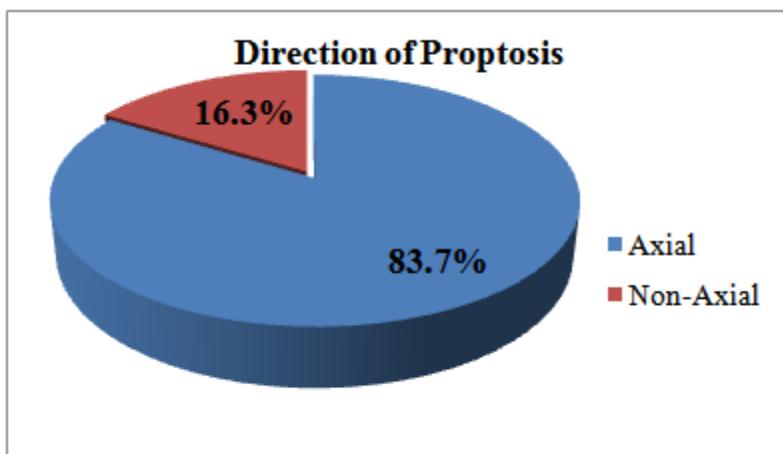
**Table – VI: Laterality distribution of proptosis.**

S. No.	Laterality	Number of cases	Percentage
1	Unilateral RE	20	46.5
2	Unilateral LE	14	32.6
3	Bilateral	09	20.9
	Total	43	100



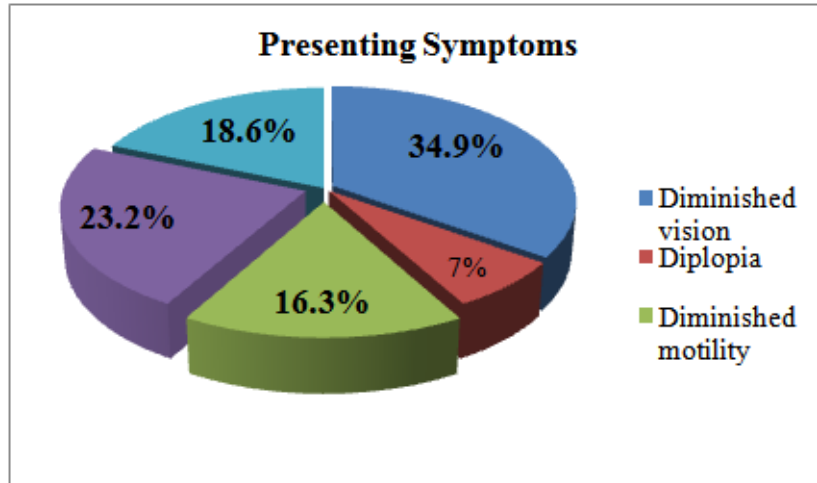
**Table – VII: Direction of Proptosis**

S. No.	Type of Proptosis	Number of cases	Percentage
1	Axial	36	83.7
2	Non-Axial	07	16.3
	Total	43	100



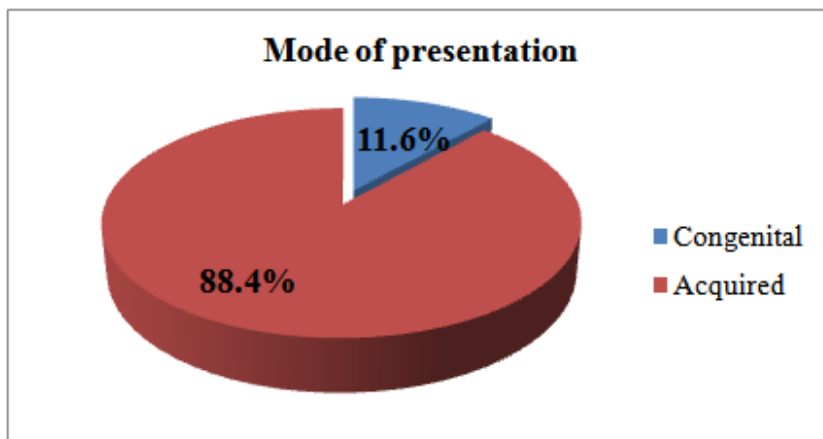
**Table – VIII: Presenting Symptoms**

S. No.	Presenting symptom	Number of cases	Percentage
1	Diminished vision	15	34.9
2	Diplopia	03	7.0
3	Diminished motility	07	16.3
4	Orbital mass	10	23.2
5	Eye pain	08	18.6
	Total	43	100



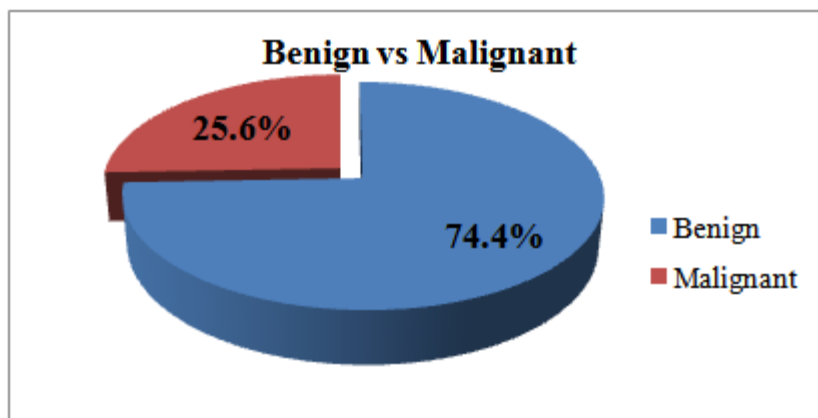
**Table – IX: Mode of presentation**

S. No.	Mode of presentation	Number of cases	Percentage
1	Congenital	05	11.6
2	Acquired	38	88.4
	Total	43	100



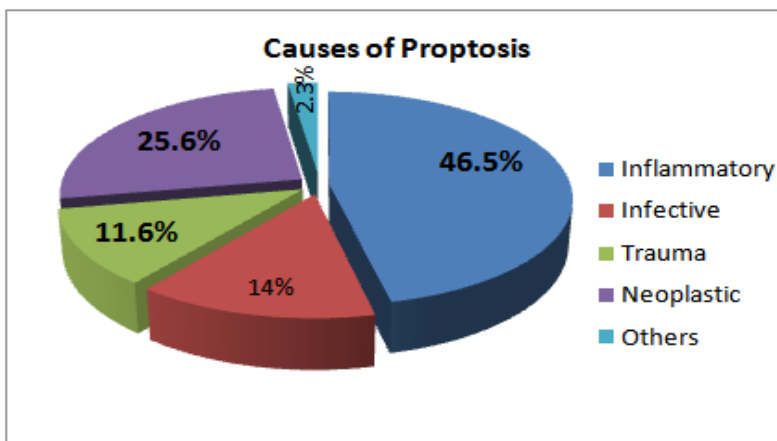
**Table – X: Benign vs Malignant**

S. No.	Type of proptosis	Number of cases	Percentage
1	Benign	32	74.4
2	Malignant	11	25.6
	Total	43	100



**Table – XI: Causes of Proptosis**

S. No.	Causes of proptosis	Number of cases	Percentage
1	Inflammatory	20	46.5
2	Infective	06	14.0
3	Trauma	05	11.6
4	Neoplastic	11	25.6
5	Others	01	2.3
	Total	43	100



**Table – XII: Investigation modalities**

S. No.	Investigation	Number of cases	Percentage
1	X-ray	05	11.6
2	B-Scan	05	11.6
3	CT Scan	29	67.5
4	MRI	04	9.3
	Total	43	100

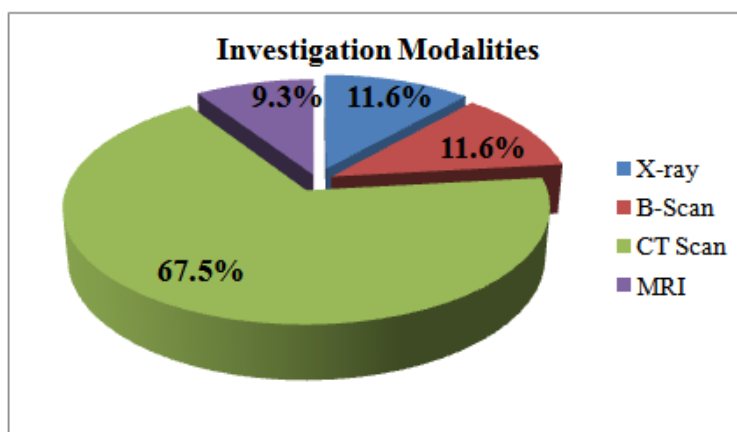


Table I shows maximum distribution in the age group of 30.39 years and >60 years followed by 40-49 years.

Table II, III, IV, V, VI, and VII showed predominance of proptosis in males (60.4%), tribals (58.1%), poor class (39.5%), amongst manual labourer (39.6%), 46.5% cases of unilateral right eye and more cases of axial proptosis (83.7%). According to table VIII and IX Diminished vision was most common presenting symptom in 34.9% cases and 88.4% cases were of acquired type, table X showed majority of cases were benign (74.4%), table XI and XII showed most common cause of proptosis was inflammatory (46.5%) and CT was most common investigation modality in 67.5% of cases.

#### IV. Discussion

Proptosis presents as both clinical symptoms and signs of orbital diseases.<sup>1</sup> There is diverse etiology ranging from local orbital problems to infiltrative diseases and spread from contiguous sites including the nasopharynx, paranasal sinuses and sometimes distant structures. It can also be a part of systemic illness

affecting multiple tissues and organs. Proptosis sometimes poses threat to vision from exposure Keratopathy and can actually lead to blindness due to compressive optic neuropathy.

A prospective cross-sectional hospital based study was done in the case of proptosis presented to emergency and outpatient department of ophthalmology in RIO, RIMS, Ranchi.

Age incidence showed bimodal distribution. The age of proptosis cases in this study that ranged from 16 months to 68 years coincides with the studies done by Naidu and Satya;<sup>2</sup> Khan et al;<sup>3</sup> Kishore and Chingsuingamba.<sup>4</sup>

This study showed male predominance which correlate with the studies done by Khan et al and Loganathan and Radha Krishnan.<sup>5</sup>

Axial proptosis was seen in 83.7% of cases which is similar to study done by Loganathan and Radha Krishnan.

88.4% cases were due to acquired causes. There were only 11.6% cases of congenital causes. Amongst 5 cases of congenital proptosis, Retinoblastoma was seen in 4 cases and dermoid cyst in only one case.

Malignant tumours comprises of Retinoblastoma, maxillary carcinoma & optic nerve meningioma, The most common cause of proptosis in the present study was inflammatory diseases seen in 46.5% of cases followed by neoplastic & 3<sup>rd</sup> common cause was infection. Similar to study by Masud et al. Amongst inflammatory, most common cause was thyroid eye disease seen in 34.88% of cases. Pseudotumour was seen in 9.30% of cases.

Malignancy of the nose & paranasal sinuses was the most common cause of ENT related proptosis followed by mucocele of the paranasal sinuses similar to studies by Venugopal & Sagesh.

In this study traumatic orbital injury mostly from road traffic accident was an important finding. The percentage of trauma related proptosis was 9.3%. In one of the patient there were multiple facial fracture & traumatic laceration of the globe.

Proptosis is multidisciplinary problem and required collaboration of different specialities of an ophthalmologist, along with an otorhinolaryngologist, neurosurgeon, oncologist and radiotherapist.

A thorough ENT examination is mandatory in proptosis. A small number of cases can never go noticed but in proptosis however, small the bulge, malignancy has to be ruled out.

There are also challenges related to patients high default rate. This has lead to inadequate and sometimes inappropriate diagnosis from follow-up assessment.

## V. Conclusion

Attending doctors should take pain to educate patients with proptosis, the possible outcome of their condition because knowing this might reduce the default rate also and also encourage them and their relatives to source for funds for their better management.

## Limitations

The number of patients in our study is relatively few considering the number of years under review. Some patients were excluded due to incomplete data and large number of our patients were unemployed and were dependent on their relatives for provision of livelihood including health care.

## References

- [1]. Dutton JJ. Orbital diseases. In Yanoff M , Duker J S. Ophthalmology . 2<sup>nd</sup> ed. Elsevier ; 2004 . p729
- [2]. Naidu APR, Satya Srinivas V , Murali Krishna V, Madhuri P. Proptosis- A clinical profile. Internationa journal of scientific research and management. 2015;3(3):2344-48.
- [3]. Khan NH, Moin M, Khan MA, Azhar Hameed. Unilateral proptosis: a local experience. Biomedical . 2004;20:114-116.
- [4]. Kishore K. Satpute , Chingsuingamba Y. A retrospective analysis of presentation and management outcome of proptosis in a tertiary care centre of North – East India – a case series. IOSR Journal of Dental and Medical Sciences. 2013; 5 (1):30-32.
- [5]. Loganathan M, Radhakrishnan M. An Etiological Analysis of childhood proptosis. Journal of Evolution of Medical and Dental Sciences 2014;3(22):6158-6162.
- [6]. Zaidi S H. unilateral Proptosis in ENT practices . j Pak Med Assoc (JPMA) 1991 ; 41 (10): 248-250
- [7]. Amudhavadi S , U. VijayaShanmugam. An aetio-epidemiological inquiry of proptosis. Int. J Intg Med Sci. 2016; 3(10):439-42.
- [8]. Venugopal M, Sagesh M. Proptosis: The ENT surgeon's perspective Indian J Otolaryngol Head Neck Surg 2013;65suppl 2:247-50.
- [9]. Zahir Shah Mahsud, Suraya Bano, Diagnostic role of CT scan in proptosis in pediatric age group. JPMI 2004; 18: 3: 439-446.
- [10]. Sabharwal KK, Chouhan AL, Jain S. CT evaluation of proptosis. Indian J Radiol Imaging 2006;16:683-8.

Umesh kumar "Observational Study of Clinical & Epidemiological Profile of Patients with Proposes At RIMS, Ranchi.."IOSR Journal of Dental and Medical Sciences (IOSR-JDMS), vol. 17, no. 8, 2018, pp 47-53.