

## Management of Severely Obliterated Canals-Case Series

Dr.Pavithra.Ravindra<sup>1</sup>, Dr.H.Murali<sup>2</sup>, Dr.B.S.Keshava Prasad<sup>3</sup>,  
Dr.K.Shashikala<sup>4</sup>,

<sup>1</sup>(Post Graduate Resident ,Department of Conservative Dentistry and Endodontics, D.A.P.M.R.V.Dental College, India)

<sup>2</sup>(Professor, Department of Conservative Dentistry and Endodontics, D.A.P.M.R.V.Dental College, India)

<sup>3</sup>(Professor and Head, Department of Conservative Dentistry and Endodontics, D.A.P.M.R.V.Dental College, India )

<sup>4</sup>(Professor, Department of Conservative Dentistry and Endodontics, D.A.P.M.R.V.Dental College, India)  
Corresponding Author: Dr.Pavithra.Ravindra

---

**Abstract:** Pulp canal obliteration commonly occurs after dental trauma. It causes complete or partial obliteration of the root canal system which poses challenge for endodontic treatment. It can be caused due to other factors such as age, systemic factors , long standing low grade stimulus. The various challenges in endodontic treatment is difficulty in identifying the canal orifice which can be achieved with the help of certain specialized burs such as Muller burs, Munce discovery burs .DG 16 can also be used in locating the orifice. Negotiating such canals is a very crucial step. Many new file systems such as C pilot files, C path finder files or even modification of K files can be used. Many iatrogenic errors occur during the negotiation or location of canals such as instrument fracture or root perforation.

This article presents 3 case reports of pulp canal obliteration due to long standing low grade stimulus, problems associated with locating and negotiating the canal and successful completion of the endodontic treatment.

---

Date of Submission: 05-01-2019

Date of acceptance: 21-01-2019

---

### I. Introduction

Pulp canal obliteration is defined as “A pulpal response to trauma characterized by rapid deposition of hard tissue within the canal space” by the American Association of Endodontists<sup>1</sup>. It is also known as Calcific metamorphosis, Dystrophic calcification, Diffuse calcification and Calcific Degeneration.

It can result due to dental trauma, caries, abfraction, abrasion, pulp capping, occlusal imbalance, orthodontic treatment, harmful oral habits or aging, any of which may manifest as a chronic low grade stimulus. The incidence of pulp canal obliteration after dental trauma has been reported to be approximately 4–24%<sup>1</sup>

This article presents 3 such cases and successful management of pulp canal obliteration caused due to long standing, low grade stimulus.

### II. Case report

A 41 yr old female patient reported to the Department of Conservative Dentistry and Endodontics with the chief complaint of pain in the lower left back tooth region since 4 months with no contributory medical history. On examination mandibular left second premolar (35) had deep distal caries which was tender to percussion. Thermal and electric tests showed delayed response.

Radiographic examination revealed caries involving enamel, dentin and pulp with breach in the lamina dura and widening of the periodontal ligament. A faint radiolucent line was visible which suggested an obliterated pulp canal (Fig.1). Diagnosis of Chronic irreversible pulpitis with symptomatic apical periodontitis was made and endodontic treatment was initiated with the consent of the patient.

LA was administered and access opening was done with a high speed bur under rubber dam isolation .The orifice was located using DG 16 endodontic explorer. Then a Path finder file was used to explore the canal (Fig.2). The file was used along with EDTA and teased further into the canal to establish patency.

With few more attempts the file reached the preoperative radiographic length. Working length was determined using #10 K file (Fig.3) .After establishing glide path cleaning and shaping was completed till 25.6%. Obturation was done by lateral condensation and access cavity was restored with interim cement (Fig.4 & 5). Patient was recalled after 3 months for a follow up (Fig.6). Patient was asymptomatic.

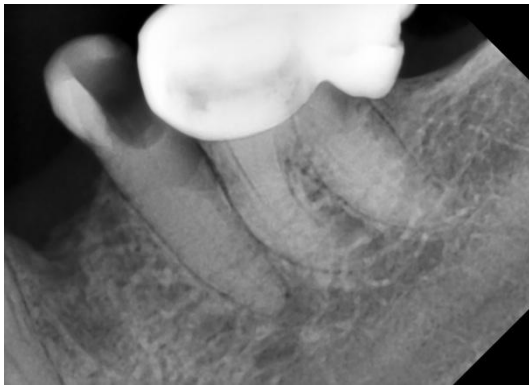


Fig.1 Preoperative radiograph

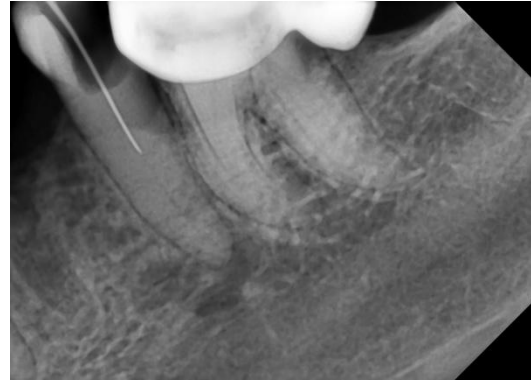


Fig.2 Path finder file used to negotiate canal

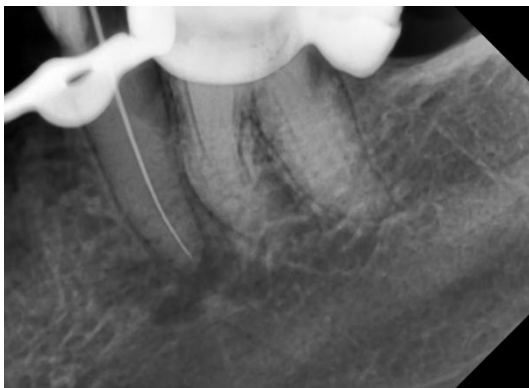

Fig.3 Working Length Radiograph

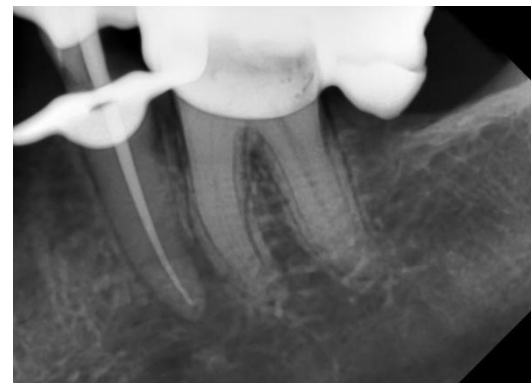

Fig.4 Master Cone Radiograph

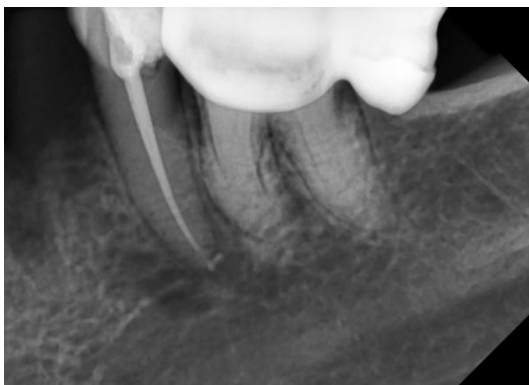

Fig.5 Obturation radiograph

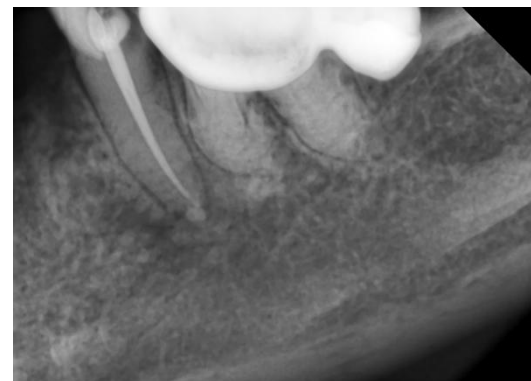

Fig.6 3 month follow up

### III. Case report 2-

A 50 yr old male patient reported to the Department of Conservative Dentistry and Endodontics with the chief complaint of pain in the lower front tooth region with no contributory medical history. On examination it was found that 31 had deep caries which tested positive to percussion.

Radiographic examination revealed involvement of pulp with widening of the periodontal ligament and discontinuity of the lamina dura (Fig.7). A diagnosis of Chronic irreversible pulpitis with symptomatic apical periodontitis was made and endodontic treatment was initiated.

L A was administered and access opening was done under rubber dam isolation. Since the clamps could not be retained because of anatomy of the tooth, rubber dam was stabilized using wedgets. The orifice could not be located, hence DG16 was used, followed by #10 file to negotiate the canal. The file was introduced into the canal in an attempt to advance inside the canal, it got separated in the coronal third (Fig.8). Another

instrument was separated during the negotiation. However the instrument was bypassed using EDTA successfully till it reached the apical stop.

The working length was determined (Fig.9), cleaning and shaping was done using hand K files and obturation was completed using lateral condensation (Fig.10 & 11). Periodic recall was done after 3months (Fig.12) and patient was asymptomatic.

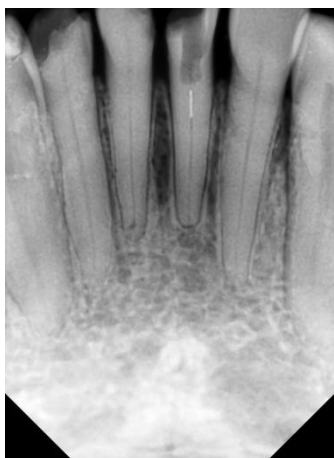


Fig.7 Separated Instrument In The Coronal Third

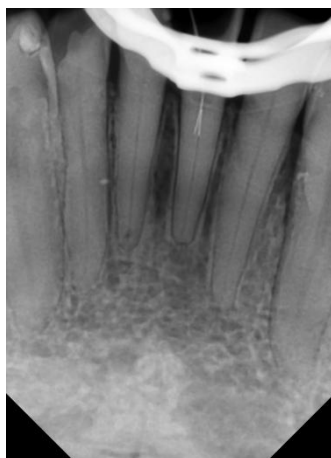


Fig.8 Instrument bypassed

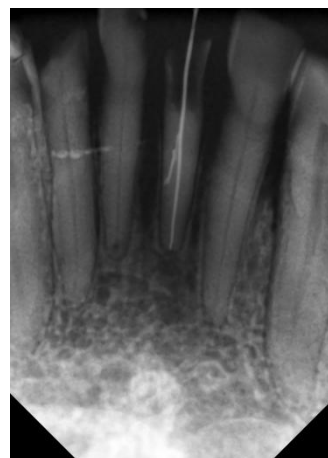


Fig.9 Working Length Radiograph

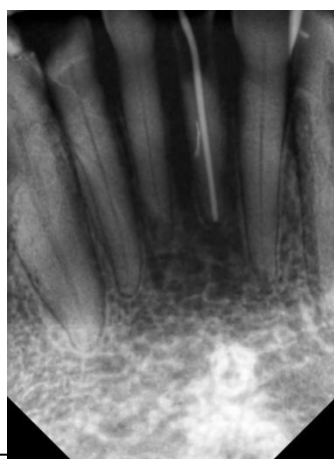


Fig.10 Master cone radiograph

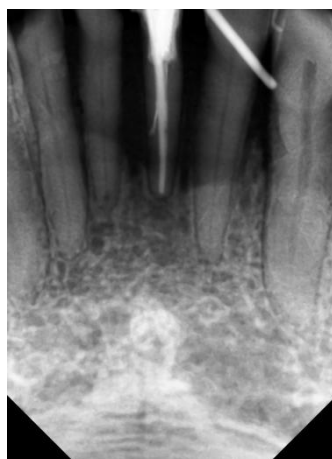


Fig.11 Post obturation radiograph

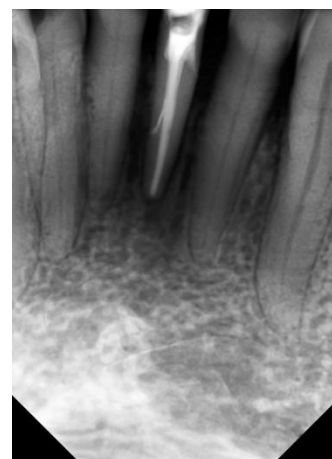


Fig.12 3 month Follow up

#### IV. Case report 3-

A 68 yr old female patient reported to the Department of Conservative Dentistry and Endodontics with the chief complaint of decay in the lower front tooth .On examination it was found that 31 had deep caries .Thermal and electric tests showed no response. Radiographic examination revealed caries involving pulp (Fig.13). Hence diagnosis of Chronic irreversible pulpitis with normal periodontium was made. Hence with the patient's consent, endodontic treatment was initiated.

LA was administered and under rubber dam isolation access opening was done. The rubber dam was tried to be retained with clamps but later stabilized with wedgets. The canal orifice was located but it could not be negotiated. C + file was used to negotiate the canal but the apical one third could not be negotiated. Working length was determined (Fig.14), cleaning and shaping was done. Copious irrigation was done using 3% sodium hypochlorite and obturation was done using lateral condensation (Fig.15 & 16).

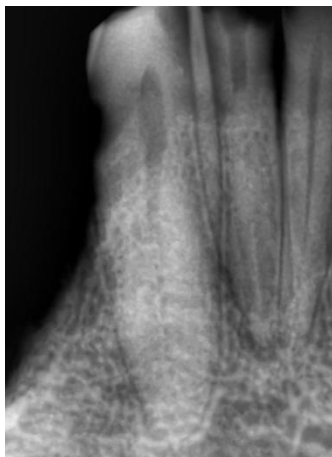


Fig.13 Pre operative radiograph

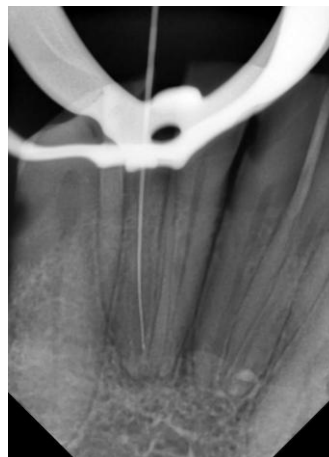


Fig.14 Working length radiograph

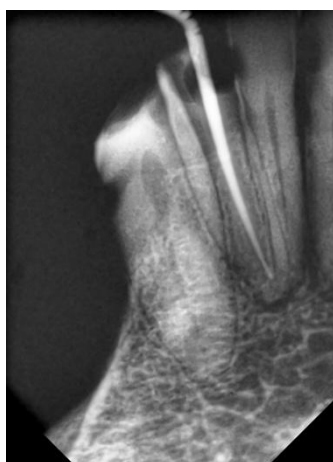

Fig.15 Master Cone Radiograph

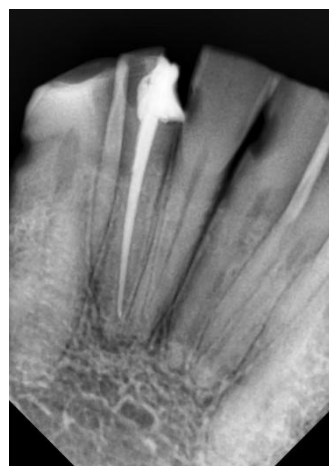

Fig.16 Post Obturation Radiograph

## V. Discussion

The success of endodontic treatment of calcified canals depends on careful location of orifice, complete negotiation of the canal, optimum cleaning and shaping and obturation of the root canal system. Pulp canal obliterations pose a challenge for an endodontist as it prevents access to the entrance of the canal, modified internal anatomy and diverted instruments. This increases the chances of iatrogenic complications and may affect the prognosis.

The etiology for pulp canal obliteration is not well understood but it is often attributed to age, trauma, deep restorations, long term standing trauma. Usually it is a sequelae of trauma.<sup>2</sup> Age related changes includes continued deposition of secondary dentin resulting in dentinal sclerosis and reducing the pulp canal space and width.

Certain systemic conditions such as Osteodystrophy and Atherosclerosis can also cause pulp canal obliteration. Soames and Southam suggested that Marfan syndrome can also cause pulp canal obliteration<sup>3</sup>.

It is also commonly found in cases with orthodontic intrusive movements which will cause compression of the apical blood vessels.<sup>3</sup>

The exact mechanism of formation of calcification is not clearly understood but can be attributed to two mechanisms-

a) The initial calcification of a component of pulp tissue (ground substance, necrotic cell remnants, collagen fibril), serves as a nidus upon which calcified material is eventually deposited.<sup>4</sup>

b) Baume et al. suggested that epithelial strands detached from the enamel organ during tooth development interact with the papilla mesenchyme, resulting in the physiologically normal differentiation of odontoblasts around the strands.

Another theory suggests that the bleeding in the canal leading to blood clot which could be a focal point for calcification in case the pulp remains vital following trauma. Hence, traumatic injury to the apical blood vessels, which may not be sufficient to cause pulpal necrosis and the pulp remains vital, could lead to calcification.<sup>4</sup>

**Clinical presentation**-It usually does not present symptoms but is characterized by the deposition of hard tissue within the root canal space and a yellow discoloration of the clinical crown. The tooth discoloration is not an usual finding.

Vital pulp testing may be unreliable (false negative) despite the presence of a vital pulp due to the increased thickness of dentin.<sup>4</sup> Partially obliterated tooth gives a delayed response whereas completely obliterated canal does not respond to the tests(as seen in case 1 and 3).

**Radiographic features**-It usually presents obliteration of the pulp canal space with absence of the pulp chamber.

Radiographically it can be classified as follows-

a) Partial Obliteration – the pulp chamber is not visible and the canal is markedly narrowed but visible

b) Total Obliteration – the pulp chamber and canal is hardly or not visible

The critical decision is whether to treat these teeth endodontically immediately upon detection of the pulpal obliteration or to wait until signs and symptoms of pulp or periapical disease occur. Only 1–16% of teeth with pulp canal obliteration will develop pulpal necrosis and only 7–27% of them will develop radiographic signs of periapical disease.

Pulpal necrosis and periapical disease are not a common finding of pulp canal obliteration. It has been advised to initiate the root canal treatment when the tooth is tender to percussion. Periapical index of 3 or more than 3 should also be considered to select the tooth for endodontic treatment.

Teeth with completely obliterated canal need not necessarily mean the complete absence of the pulp canal space. In majority of cases, pulp canal will be obtained with patent pulpal tissue. During the endodontic procedure many complications occur such as difficulty in orifice location, gouging, perforation, irretrievable instrument fracture<sup>1</sup> (as seen in case report 2)

#### **Orifice Location-**

Rubber dam isolation is an important factor to be included in the endodontic treatment. The distance between the occlusal surface and projected pulp chamber should be measured in the preoperative radiograph before initiating the access opening which will help in locating the canal.

Many dyes such as Methylene blue and champagne effect of sodium hypochlorite can be used. The use of dental operating microscope will help as the practitioner can visualize the pulp chamber floor. Burs such as Muller bur, Munce discovery bur, Endo guide burs which have long shank and better visibility help in locating the orifice of the highly calcified canal.

After initial access opening, 3 radiographs should be taken to confirm the relation of the bur to canal lumen in buccolingual direction. One straight angulation radiograph and the other two radiographs using SLOB technique need to be taken.

#### **Negotiation of the canal-**

Negotiation of the canal should also be done with utmost care and patience. Using small size files results in fracture when used in watch winding motion with apical pressure. Hence to avoid it #8 and # 10 size file are used alternatively with gentle watch winding motion only. Instruments such as C + files or Path finder files can be used as these files have cutting tip and engage the dentin.

K files can also be modified by cutting the tip of the file and making it stiff. The #6 and # 8 files should be precurved using Endo bender pliers which will allow the file to pass through the curvatures easily. Ultrasonic tips are very useful aids in such cases. After the initial negotiation is achieved the file should then be advanced in increments with copious irrigation.

EDTA (chelating agent) which is to be used routinely in endodontic treatment is mandatory while treating calcified canals. It replaces calcium ions of dentin with the sodium ions leading to soluble salts and thus helps in advancing the file passively further in the canal.

During the endodontic treatment certain iatrogenic errors happen such as excess removal of dentin resulting in perforation. The sudden sensation of entering a pulp space will not occur since the chamber is filled with calcified material. To avoid the perforation access opening must be done as incisal as possible and bur has to be kept parallel to the long axis.<sup>4</sup>

The treatment option other than endodontic treatment includes surgical management, bleaching techniques for aesthetic concerns.

## **VI. Conclusion**

The cases presented here are examples of radiographically unidentifiable root canal systems that are difficult to treat but managed by non surgical endodontic treatment. Good knowledge of tooth anatomy with use of appropriate instruments and patience will yield successful treatment outcome.

Conflict of interest- Nil

## **References**

- [1]. Dr Hugo Sousa Dias. Management of pulp canal obliteration: A clinical case report and tips and tricks, *Roots-International*. 2018;3:06-08.
- [2]. P. S. McCabe & P. M. H. Dummer. Pulp canal obliteration: an endodontic diagnosis and treatment challenge, *International Endodontic Journal*. 2012;45:177-197.
- [3]. Bernice Thomas, ManojChandak et al. Calcified Canals – A Review, *International Organization of Scientific Research*. 2014;13:38-43.
- [4]. Chandrakar Chaman et al. Root canals- from concretion to patency, *Saudi Endodontic Journal*. 2015 ; 5: 13-19.

Dr.Pavithra.Ravindra. “Management of Severely Obliterated Canals-Case Series”. *IOSR Journal of Dental and Medical Sciences (IOSR-JDMS)*, vol. 18, no. 1, 2019, pp 51-56.