

Fetal Abdominal Cyst

Dr. Mattegunta Sahiti ; Dr. Keerthy Rethiman M ; Prof . Chitra Andrew

Department of Obstetrics and Gynaecology, Sri Ramachandra University, Chennai, India.

Corresponding Author: Dr. Mattegunta Sahiti

Date of Submission: 07-01-2019

Date of acceptance: 22-01-2019

I. Introduction

The recent advances in Fetal diagnostic technologies and the widespread use of ultrasound in pregnancy has enabled early identification and more precise assessment of Fetal intra-abdominal cysts [1].The prenatal identification of intra-abdominal cyst is relatively common [2].The concept of abdominal cyst encompasses many cystic lesions developing from abdominal structures and representing varied pathologies. Regardless of the underlying pathology, the most common sonography presentation is that of a round, anechoic structure or variable size and position [2].

In clinical practice, these lesions are most frequently detected on 18-20 week routine anomaly scan. However some do not become apparent till the third trimester. In differential diagnosis ovarian cysts, enteric duplication cysts, mesenteric cysts, meconium pseudocysts and choledochal cysts should be considered apart from cysts with urinary origin. Less frequently seen are adrenal cysts, splenic cysts, hydrocolpos, urachal cysts and chylous ascitis[2,3,4].

The differential diagnosis can be aided by knowledge of the sex of the fetus, the location, the appearance and the relationship with the adjacent structures of the cyst. Serial monitoring is essential in the management of intra-abdominal cyst. In most cases, the cyst regress spontaneously. The aim of this study is to ascertain the postnatal outcome of fetuses detected with abdominal cyst during antenatal sonographic examination.

AIM

The aim of this study is to ascertain the post natal outcome of antenatally detected fetal abdominal cysts at a tertiary care medical center over a period of 38 months.

II. Materials and methods

A retrospective cohort study of all the fetus with intra-abdominal cyst, detected at our tertiary care center in the department of Obstetrics and Gynaecology over a period of 38 months i.e. from January 2014 to February 2017 was conducted. Fetuses with intra – abdominal cyst with most likely abdominal origin were included in this study . Fetuses with obvious retroperitoneal, urinary, spinal cyst origin were excluded from this study.

All the prenatal ultrasonographic examinations were performed by experienced obstetricians who has expertise in Fetal Medicine. All the ultra so no graphic examinations were done using Volus on v8 ultrasound machine .The criteria adopted in this study concerning the prenatal ultrasonographic features of intra – abdominal cyst are shown in Table 1.

A total of 23 cases were involved in the study. The different criteria, like gestational age, cyst location – abdomen, pelvis, kidney, nature of the cyst – cystic debris, vascularity, possible origin, mode of delivery and neonatal management were taken into account.

Cyst	Location	Size	US features	Prenatal complications	Outcome
Ovarian	<ul style="list-style-type: none"> • Pelvis • Female fetus 	May be large	Unilocular Thin walled Late 2 nd and 3 rd trimester	Haemorrhage prenatally	50% postnatal intervention Rest resolve No sequelae
Enteric duplication	40% ileum Colon, rectum	May be very large	-Anechoic -unilocular -double wall -Spherical or tubular	Assoc NTD Haemorrhage, perforation, bowel obstruction	May need resection for bowel obstruction
Mesenteric cyst	<ul style="list-style-type: none"> • Small bowel mesentery • Lymphangiomas 		Multilocular Thick walled No peristalsis	Nil usually	Mostly need surgery for bowel complications

Table1: Ultrasonographic features of intra abdominals cysts.

Database search of all cases and follow-up obtained from hospital records or telephone call.

III. Result

A total of 23 Fetuses with prenatally detected intra abdominal cyst were taken into this study. Serial ultrasonographic examination was done for all the cases. In utero resolution was noted in 3 fetuses. All the cases were followed up postnatally. Follow up was lost in 3 cases. Of the 17 cases, ovarian/mesenteric cysts were noted in 16 cases and hepatic cyst in 1. Male to female ratio -4:17.

No termination of pregnancy or intrauterine demise noted in any of the cases. Mode of delivery was Caesarean section in 70% of the cases (mostly due to Obstetrics indication) and spontaneous vaginal delivery in 30% of the cases.

All the cases were followed up postnatally by Serial ultrasonography. Of the 17 cases that required postnatal evaluation, 16 resolved without any need for surgical intervention. 1 case needed surgical intervention. In the case that required surgical intervention, the intra – abdominal cyst was detected at 34 weeks growth scan following a normal target scan [Figure 1] in a low risk multigravida with a previous normal delivery. Cyst seen of size 5.3 cms x 5.2 cms, clear, thin walled with no solid areas, no vascularity was noted in the Fetal abdomen [Figure 2]. A follow up scan done at 36 weeks showed an increase in the cyst size to 7.7 x 5.3 x 7.5 cms, probably mesenteric or ovarian cyst [Figure 3]. The Girl baby was delivered by Lower segment Caesarean section (due to maternal indication), weighed 3.9kgs.

Ultrasonography of abdomen done postnatally showed a mesenteric cyst. Laparoscopic cystectomy with ovarian preservation was done for the baby. Laproscopic finding was an ovarian cyst [Figure 4]. Histopathology report showed a simple cyst .

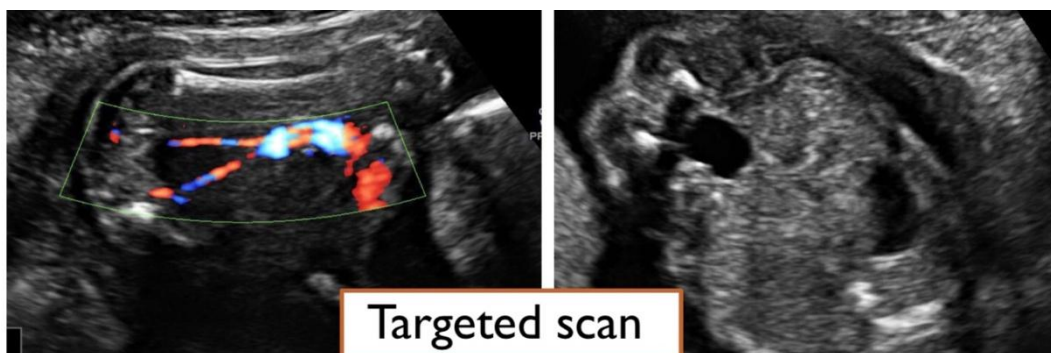


Figure1: normal target scan

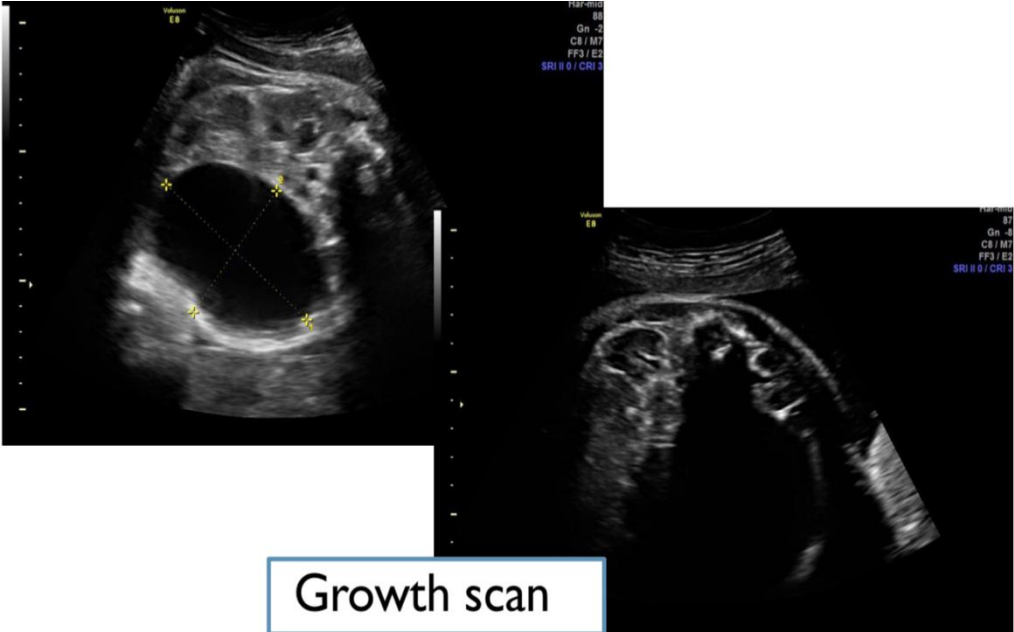


Figure2: Growth scan at 34 weeks of gestation

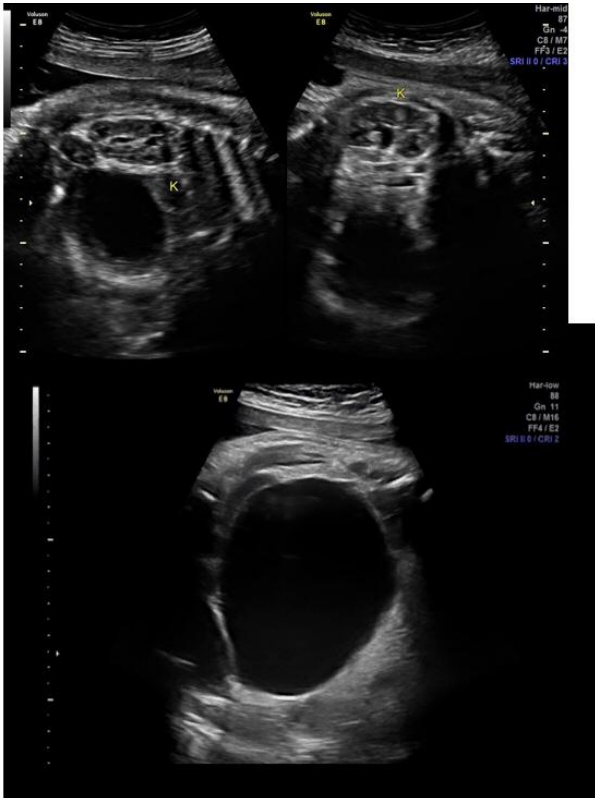

Figure 3: Growth scan at 36 weeks

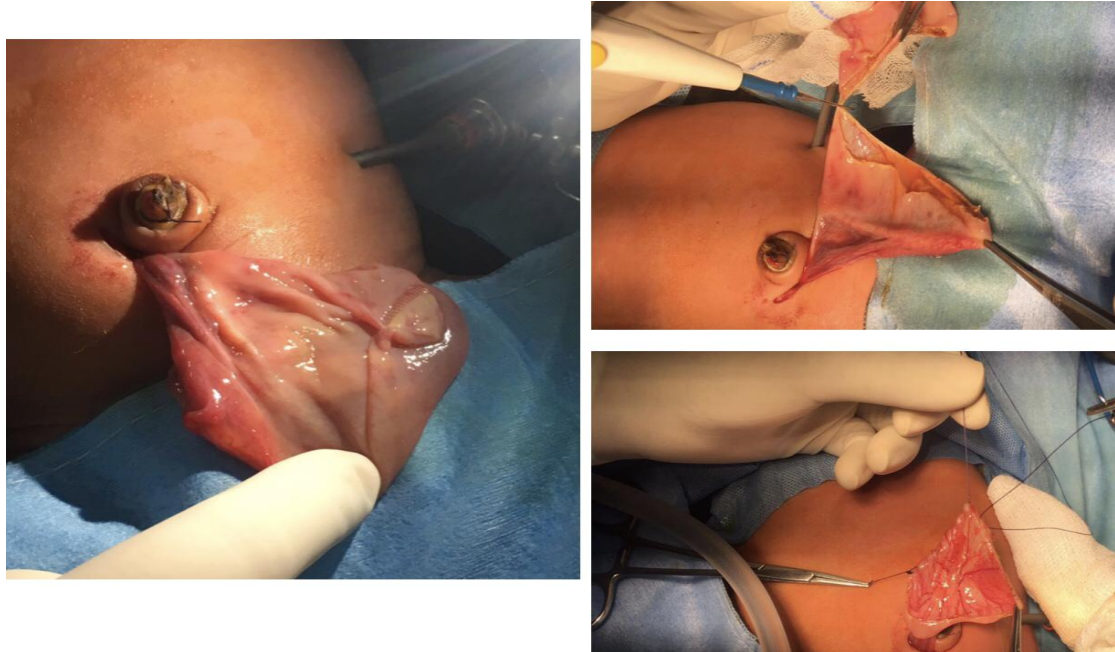


Figure 4: Laproscopic findings of ovarian cystectomy

IV. Discussion

Fetal intra abdominal cysts are relatively common. The differential diagnosis of Fetal intra abdominal cyst include ovarian cysts, mesenteric cysts, enteric duplication cysts, meconium cysts and choledochal cysts. The fetuses with prenatal diagnosis of intra abdominal cyst should undergo a detailed ultrasonographic examination to excluded other possible associated anomalies. In some cases ,other abnormalities like single umbilical artery and other soft markers for aneuploidy may be detected. Fetuses with these cysts should be followed for development of polyhydramios (a consequence of GI malformation),and the subsequent risk of preterm labour. Favourable outcome was the highest among fetuses with genital tract cysts, which mainly corresponded to ovarian cysts. More than 90% of the patients have good long term outcome. The majority of the cysts can be diagnosed accurately during pregnancy and the outcome of these fetuses is favourable in almost all of them.

V. Conclusion

Fetal abdominal cysts are more common in female fetuses. Frequently diagnosed in the third trimester of pregnancy. When presented as an isolated finding , they are associated with good postnatal outcome

References

- [1]. Kuroda T, Kitano Y, Honma T, et al. Prenatal diagnosis and management of abdominal diseases in pediatric surgery. *J Pediatr Surg* 2004;39:1819-22.
- [2]. McEwing R, Hayward C, Furness M. foetal cystic abdominal masses. *Austral Radiol* 2003;28:153-9.
- [3]. Twining P, McHugo J, Pilling D (2000) *Textbook of Fetal abnormalities*. Churchill Livingstone ,Edinburg.
- [4]. Khong PL, Cheong SC, Leong LL, Ooi CG (2003) Ultrasonography of intra-Abdominal cystic lesions in the newborn. *Clin Radiol* 58: 449-454.

Dr. Mattegunta Sahiti. "Fetal Abdominal Cyst." *IOSR Journal of Dental and Medical Sciences (IOSR-JDMS)*, vol. 18, no. 1, 2019, pp 01-04.