

A Comparative Study of the Fine Needle Aspiration versus Fine Needle Non-Aspiration Technique of Cytodiagnosis in the Lymph Nodes Swellings

Shafira Bharti¹, Alok Mohan², Meenakshi Tyagi³, Veena K Sharma⁴, Diksha⁵
1,2,3,4- (Department of Pathology, Muzaffarnagar Medical College, Muzaffarnagar)
5- (Department of TB & Chest, Muzaffarnagar Medical College, Muzaffarnagar)
Corresponding Author: Alok Mohan

Abstract:

Background: Fine Needle Aspiration cytology (FNAC) is the first line technique in the diagnosis of lymph node swellings. It is quick, simple, inexpensive, minimally invasive. Fine Needle Non aspiration technique (FNNAC) have also been introduced.

Objectives: To compare FNAC and FNNAC techniques in lymph node swellings.

Methods: The study was conducted in tertiary centre for one year of duration. Cases of lymph nodes were sampled using both FNAC and FNNAC techniques. They were compared using Mair's point scoring system. Statistically analysis was done using student's t- test.

Results: Most of the cases of lymph node swellings, 78/208 (37.50%), were falling in the age group of 20-29 years with male to female ratio of 1:1.7. All lymph nodes swellings were diagnostically categorized into non-neoplastic (n=183), metastatic tumors (n=19) and lymphoproliferative disorders (n=6). FNNAC were more likely to be diagnostically superior in 109/208 cases (52.40%). The FNAC smears were more likely to be diagnostically adequate in 131/208 cases (62.98%).

Conclusion: FNAC yielded better amount of cellular material than FNNAC but diagnostically superior specimen was obtained from FNNAC.

Keywords: Cytology, aspiration, non-aspiration, lymph node, lymphoma.

Date of Submission: 11-01-2019

Date of acceptance: 22-01-2019

I. Introduction

Fine Needle Aspiration Cytology (FNAC) is simple, rapid & cost- effective. It is relatively less traumatic, thus pathologist can provide the diagnosis to the clinician in a short period. Lymphadenopathy is a common clinical presentation in all age groups. FNAC is an excellent first line method for its evaluation. It is easily performed on enlarged lymph nodes. It is more economical & convenient alternative for open biopsy.

It also prevents a patient to undergo unnecessary surgery & thus offer conservative therapy. Grey and Gray performed aspiration of lymph node for the purpose of diagnosis in the patients with sleeping sickness in 1904. [1]

Brifford et al developed fine needle non-aspiration cytology in 1982. He used this technique in breast.[2] It is also called cytopuncture or fine needle capillary sampling. This present study was undertaken to study the advantage and disadvantage of both FNAC and FNNAC techniques.

II. Material and methods

This study was conducted in tertiary centre for a duration of one year, i.e. from May 2017 to April 2018. This study was a hospital-based study of prospective type. Institutional ethical clearance was obtained.

2.1 Inclusion criteria:

- Palpable superficial mass lesion in head and neck region.
- Cases coming within the specified period of time.

2.2 Exclusion criteria:

- Totally unsupportive patient
- Unpalpable lesion
- Deep seated swellings
- Ocular swellings

- Central nervous system swellings
- Pulsatile vascular lesions/ tumors of vascular origin
- Situation where both the techniques cannot be done

2.3 Sample size-Average minimum of 150 cases done.

A brief clinical history of the patient was taken and thorough physical examination of the lesion/lesions was done. Informed consent was taken. Recommended patients were subjected to aspiration and non-aspiration techniques.

20 ml disposable plastic syringe was used for suction in FNNAC cases. And syringe pistol was not employed for FNC. Half of the smears prepared by each sampling technique were sprayed immediately with alcohol for Papanicolaou staining and rest were allowed to air dried for staining by the May-GrünwaldGiemsa method. All smears were assessed using predetermined objective criteria by observers (A.M. & M.T.) who had no prior knowledge of the sampling technique used for any slide evaluated. The study was thus “single blind” preventing bias. A cytologic diagnosis was rendered for each cases seen, and each individual slide was objectively analyzed using a point scoring system, to enable accurate comparison between FNA and FNC techniques, using a predetermined as shown below:

MAIR’S POINT SCORING SYSTEM (Mair et al 1989)[12]- Characteristics Points

CRITERION	QUANTITATIVE DESCRIPTION	SCORE
Background blood or clot	Large amount; great compromise to diagnosis	0
	Moderate amount; diagnosis possible	1
	Minimal; diagnosis easy; specimen of text book quality	2
Amount of cellular material	Minimal or absent; diagnosis not possible	0
	Sufficient for cytodiagnosis	1
	Abundant; diagnosis simple	2
Degree of cellular degeneration	Marked; diagnosis impossible	0
	Moderate; diagnosis possible	1
	Minimal; good preservation; diagnosis easy	2
Degree of cellular trauma	Marked; diagnosis not possible	0
	Moderate; diagnosis possible	1
	Minimal; diagnosis obvious	2
Retention of appropriate architecture	Minimal to absent; non diagnostic	0
	Moderate; some preservation of e.g. follicles, papillae, acini, flat sheets, syncytia or single cell pattern	1
	Excellent architectural display closely reflecting histology, obvious diagnosis	2

2.4 Specimen Quality Analysis- On the basis of the five criteria, a cumulative score of between 0 and 10 points was allocated to each fine needle specimen which was then assign, accordingly, to one of three categories:-

- “**Diagnostically Unsuitable**” for cytodiagnosis (0 to 2 total points);
- “**Diagnostically Adequate**” for cytodiagnosis (3 to 6 total points);
- “**Diagnostically superior**” for cytodiagnosis (7 to 10 total points).

2.5 Analysis of results-

All values were interpreted statistically using, the Student’s t- test where appropriate. All results were analyzed considering statistical significance.

III. Observations And Results

A total of 208 cases of lymph node swellings were studied in the present study. These patients were subjected for both fine needle aspiration and fine needle aspiration without aspiration for cytodiagnosis.

Most of the cases of lymph node swellings, 78/208 (37.50%), were falling in the age group of 20-29 years while least number of case were seen in less than 10 years of age i.e 1/208 cases (0.48%). The mean age was calculated to be 32.92 years. Among 208 cases of various age group, 132 cases were females and 76 were male. It showed a female preponderance in our study with male to female ratio of 1:1.7

The swellings were cytologically categorized into two general categories: non-neoplastic and neoplastic malignant lesions which are further divided into metastatic and lymphoma.

In the present study non-neoplastic swellings includes Necrotizing granulomatous lymphadenitis 73/208 (35.10%), Reactive lymphadenitis 52/208 (25%), Non-Necrotizing Granulomatous Lymphadenitis 42/208 (20.19%), suppurative 16/208 (7.69%), Kikuchi disease 1/208 (0.48%) and RosaiDorfman disease 1/208 (0.48%).

In our study we observed 42 cases (20.19%) of non-necrotizing granulomatous lymphadenitis. (Image 1A-1E)

In the present study, out of 25 malignant cases, 06 cases of malignant lymphoma and 19 cases of metastatic carcinoma were reported.

Malignant lymphomas (6 cases) included a single case of Hodgkin disease and 5 cases of Non-Hodgkin Lymphoma.

Metastatic carcinoma (19 cases) which included 15 cases of squamous cell carcinoma, 03 cases of adenocarcinoma and one case of small cell carcinoma, which were diagnosed correctly by both FNAC and FNNAC. (Image 1F-1H)

3.1 FNAC versus FNNAC in lymph node swellings:

FNNAC were more likely to be diagnostically superior in 109/208 cases (52.40%) while diagnostically adequate in 99/208 cases (47.60%) and none of case was insufficient for diagnosis. When FNNAC smears were diagnostic they more frequently produced superior quality material. Many FNNAC smears showed text book quality with excellent architectural display.

The FNAC smears were more likely to be diagnostically adequate in 131/208 cases (62.98%) but diagnostically superior in only 76 cases (36.54%) and a single case (0.48%) was insufficient for diagnosis. Conventional fine needle aspiration technique although diagnostic in a greater number of cases mostly produced adequate rather than superior quality material.

Inadequate material for cytodiagnosis was more often produced with FNNAC than FNAC.

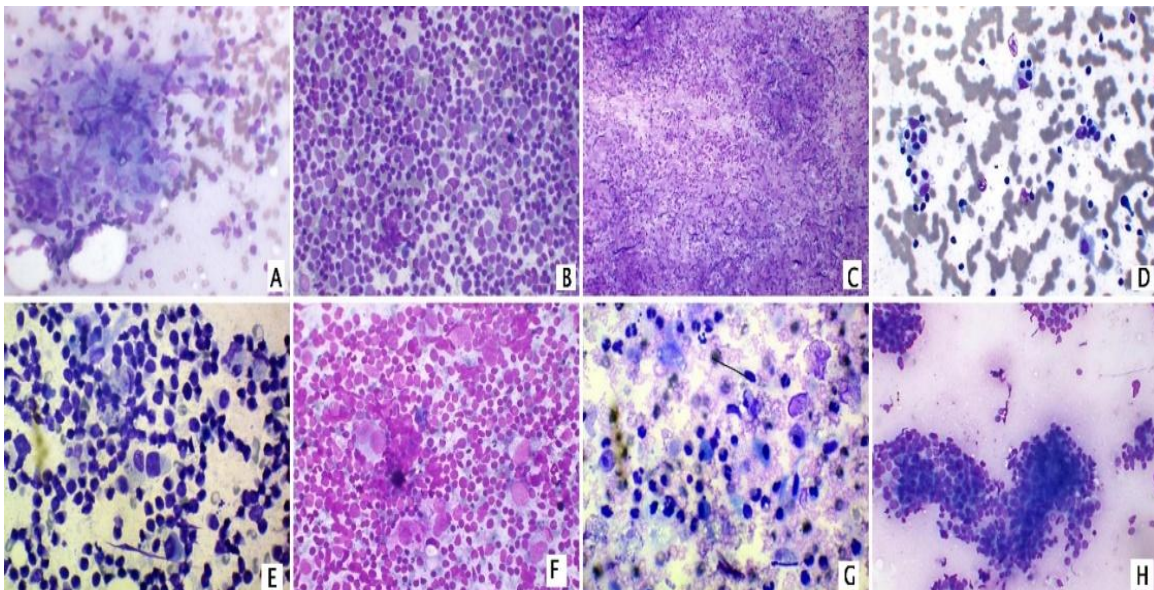


Image 1- A. Granulomatous Lymphadenitis showing epithelioid cell granuloma without necrosis.(Giemsa stain 400x) B. Reactive Lymphadenitis showing mixed lymphoid series cells. (Giemsa stain 400x). C.Supplicative Lymphadenitis showing degenerated and intact neutrophils over necrotic background. (Giemsa stain 100x) D.Rosai-Dorfman's disease. Large histiocyte with prominent nucleoli and lymphophagocytosis. (Giemsa stain 400x) E. Kikuchi's lymphadenitis with lymphocytes mixed with phagocytic histiocytes having vacuolated cytoplasm. (Giemsa stain 400x) F. Hodgkin's Lymphoma showing binucleated Reed-Sternberg cell over lymphoid cells. (Giemsa stain 400x). G. Metastatic Squamous cell carcinoma showing atypical cells with squamous differentiation. (Giemsa stain 400x) H. Metastatic Adenocarcinoma showing malignant cells arranged in 3 dimensional cluster. (Giemsa 200x)

IV. Discussion

In the present study, a total of 208 cases of lymph node swellings were studied, which were subjected to both fine needle capillary cytology (FNNAC) and fine needle aspiration cytology (FNAC).

In the present study, maximum number of 78/208 (37.50%) cases of lymph nodes swellings were of 20-29 years age group.

More SA et al[3] studied 200 patients of varied age (1 year to 85 years) with maximum number of patients following in 21-30 years age group.

Vats S et al[4] studied the spectrum of lymphadenopathies on fine needle aspiration cytology with the age of the patients ranged from 2 years to 78 years, maximum number of cases in the age group of 21–30 year. There was a female preponderance.

In the present study, various lesions in lymph nodes were classified into non-neoplastic (183 cases) and neoplastic (25 cases). Non-neoplastic lesions included reactive lymphadenitis (52 cases), granulomatous lymphadenitis without necrosis (42 cases), necrotizing granulomatous lymphadenitis (73 cases; 55 cases were positive for ZN stain), suppurative (16 cases) whereas neoplastic lesions included metastatic (19 cases) and lymphoproliferative disorders (6 cases).

Sreedevi Pet al[5] studied in their study, out of 153 cases of lymph node lesions, reactive lymphadenitis (51.63%) was the predominant cause of lymphadenopathy followed by tubercular lymphadenitis in 42 (27.4%) cases. Metastatic lesions and lymphomas constituted 9 cases (5.88%) each.

Vats S et al[4] studied the spectrum of lymphadenopathies on fine needle aspiration cytology and found the most common lesion encountered was reactive lymphadenitis (36.33%) followed by granulomatous lymphadenitis (22.10%), tubercular lymphadenitis (17.98%), metastatic lesion (10.49%), acute lymphadenitis (8.61%) and lymphoma (4.12%).

In Manjula et al[6] study, in the lymph node aspirates, tuberculosis (51 cases) was the commonest lesion followed by reactive hyperplasia, metastatic malignancy, non-specific lymphadenitis and acute suppurative lymphadenitis

Kate et al[7] observed 52.1% cases of granulomatous lymphadenitis followed by reactive hyperplasia in 21.6% cases.

Mandava et al[8], in their cytological study on non-neoplastic lymph node lesions studied 49 cases of necrotizing granulomatous lymphadenitis. In non-necrotizing granulomatous lymphadenitis they observed 22 cases (7.7%).

In the present study, we studied idiopathic necrotizing lymphadenitis (Kikuchi disease) in a single case. The patient was 17 years old female with swelling in posterior triangle of neck of left side.

Mandava et al[8] studied 5 cases of Kikuchi disease in their study. All the patients were below the age of 25 years. In four cases cervical lymph nodes were involved and in one case submandibular lymph node was involved. Age group was similar to our study.

In reactive lymphadenitis we observed 52 cases (25%). Duraiswami R et al[9] studied during the period of 2014 to 2016, a diagnosis of reactive lymph node hyperplasia was given in 126 aspirates out of 253 (49.8%) and was the most common diagnosis offered. Granulomatous lymphadenitis, caseating or non-caseating, was diagnosed in 94 aspirates out of 253 (37.15%) and was the second most common diagnosis offered.

In the present study, a case of Rosai-Dorfman disease was also studied. The patient presented with massive lymphadenopathy of size 5 x 4 cm on left side of neck. The cytomorphological features were showing sinus histiocytosis.

Mandava et al[8] also observed a single case of Rosai-Dorfman disease with massive lymphadenopathy of size of 6 x 4 cms. Thus the findings were similar to this study.

In this group, out of 25 cases, 6 cases were lymphoma and 19 cases were of metastasis to lymph node.

In metastatic lymphadenitis 15/19 cases (7.21%) were of metastatic squamous cell carcinoma.

Mohan et al[10] observed that most common subtype of metastatic carcinoma was squamous cell carcinoma in 66 cases (52.8%) out of 125 cases. The metastasis had occurred from primary carcinomas in buccal mucosa, cheek, tongue, alveolus and palate.

Cervin et al[11], Linderberg et al[12] and Sinha et al[13] also studied lymph node metastasis in cervical and supraclavicular region. Cervical lymph nodes were the sites for primaries in upper aero-digestive tract.

Sinha et al [13], in their study found that squamous cell carcinoma was the most common cause of lymph node metastasis seen in 58.6% cases. In our study it was seen in 63.15% cases.

In the present study three cases of metastatic adenocarcinoma were found out of 208 cases (1.44%). Sinha et al [13] and Mohan et al[10] in their study found 30.8% cases and 25.6% cases of metastatic adenocarcinoma respectively, which were higher than the present study.

In the present study, a single case of metastatic small cell carcinoma was found out of 19 cases (5.26%). The patient was 53 years old male.

Mohan et al[10] in their study found 3 cases (2.4%) of metastatic small cell carcinoma whereas in the study we found 5.26% cases. They observed cells with scant cytoplasm with nuclei 2-3 times larger than small lymphocytes. Malignant lymphomas (6 cases) included a single case of Hodgkin disease and 5 cases of Non-Hodgkin Lymphoma. A single case of Hodgkin lymphoma in 28 years old male with left cervical swelling. All the remaining five cases were diagnosed as Non-Hodgkin Lymphoma.

In the study by Duraiswami R et al[9], lymphoproliferative disorders were diagnosed in only 4 out of 253 aspirates analysed (1.6%); three cases were diagnosed as non-Hodgkin lymphoma and one as Hodgkin lymphoma.

Various studies	Fine needle aspiration cytology (FNAC)			Fine needle non aspiration cytology (FNNAC)		
	Diagnostically Superior	Diagnostically Adequate	Diagnostically inferior	Diagnostically Superior	Diagnostically Adequate	Diagnostically Inferior
ManjulaCP (2017) ⁶	103 (76.9%)	28 (20.9%)	03 (2.2 %)	124 (92.5%)	09 (6.7%)	01 (0.7%)
Garg M(2014) ⁹	08 (18%)	40 (80%)	02 (4%)	19 (38%)	29 (58%)	02 (4%)
Present Study	76 (36.54%)	131 (62.98%)	01 (0.48%)	109 (52.40%)	99 (47.60%)	00 (00)

4.1 FNAC versus FNNAC in lymph node swellings:

A total cases of lymph node swellings (n=208) underwent both techniques and scored. In the present study the total score for FNAC was 1259 (6.05 average score per case) was lower than the total score for FNNAC was 1362 (6.55 average score per case), which was statistically significant. Mair et al[14] also made observations that for lymph nodes site sampled, there was no significant difference between FNAC and FNNAC techniques. Their total score for FNAC sampling was 134 (6.70 average score per case) and 129 (6.45 average score case) for FNNAC sampling technique. For background blood or clot, the average score per case for FNAC 1.05 was lower than the average score for FNNAC 1.25. For amount of cellular material, the average score per case for 1.50 was higher than the average score for FNNAC 1.35. For degree of cellular degeneration, the average score per case for FNAC 1.35 & for FNNAC was 1.15. For degree of cellular trauma the average score for FNAC was 1.40 & the average score FNNAC was 1.30. For retention of appropriate architecture the average score per case for FNAC 1.35 & the average score per case for FNNAC 1.25. Manjula et al[6] observed that FNNAC was better than FNAC for lymph node lesions with respect to all the five parameters. Statistically significant difference was noted in background blood, amount of cellular material and retention of appropriate architecture. In a study by Misra et al[15], FNNAC showed statistically significant difference in the parameter background blood. Similar results have been obtained by Gosh et al in lymph node lesions. In the present study aspiration technique yielded good amount of cellular material with statistically insignificant difference. Discordant results were noted in the study of superficial lymphadenopathy by Akhtar et al[16]. When compared for degree of cellular trauma better results were obtained by FNNAC, though the differences were marginal, similar to studies by Ghosh et al[17] and Misra et al [15]. In cellular degeneration, the mean score of both techniques was equal. Misra et al[15] found retention of architecture to be better in the non aspiration technique. These findings are in concordance with the present study, though the difference were marginal. Out of 208 cases, on FNAC 76 cases was diagnostically superior, 131 cases were diagnostically adequate & 1 case was diagnostically inferior whereas on FNNAC 109 cases were diagnostically superior, 99 cases were diagnostically adequate & none of the case was diagnostically inferior.

Various studies	Fine needle aspiration cytology (FNAC)					Fine needle non aspiration cytology (FNNAC)				
	Background	Amount of cellular material	Architecture	Cellular degeneration	Cellular Trauma	Background	Amount of cellular material	Architecture	Cellular degeneration	Cellular Trauma
Mair (1989) ¹⁴	1.05	1.50	1.35	1.40	1.35	1.25	1.35	1.15	1.30	1.25
Manjula CP (2017) ⁶	1.26	1.49	1.25	1.67	1.54	1.90	1.78	1.67	1.73	1.60
Present study	1.13	1.76	1.19	1.02	0.97	1.95	1.41	1.20	1.02	0.98

V. Conclusion

FNAC and FNNAC are simple outpatient department procedures. The main advantages of these procedures over biopsy are faster diagnosis, minimal invasive and less expensive to the patients. Both the techniques have their own advantages and disadvantages.

FNAC yields better amount of cellular material than FNNAC but diagnostically superior specimen was obtained from FNNAC. There was statistically significant differences between them as FNNAC yielded better results. But still, it is best to be decided by the cytopathologist as to which technique one would choose for yielding better results and aiding in accurate diagnosis.

References

- [1]. Cohen MB, Miller TR, Bottles K. classics in cytology: note on fine needle aspiration of the lymphatic glands in sleeping sickness. *ActaCytol* 1986;30(4):451-2.
- [2]. Briffod M, Gentile A, Hebert H. Cytopuncture in the follow-up of breast carcinoma. *ActaCytol.* 1982;26:195-200.
- [3]. More SA, Bhalara RV, Shah PM, Talwelkar SR, Dhruva GA. FNACC of cervical lymph nodes. *Asia Pacific Journal of Research Vol: I Issue XXIV.* 2014 Nov.
- [4]. Vats S, Manchanda B, Gupta K, Sharma P, Kansal R, Goel S, Sharma VK. Spectrum of Lymphadenopathies on Fine Needle Aspiration Cytology in and around Muzaffarnagar. *Indian Journal of Public Health Research & Development.* 2018 Jan 1;9(1).
- [5]. Sreedevi P, K Kumar, Parankusa N C. Diagnostic Role of FNACC in Evaluation of Head and Neck LesionI *IOSR Journal of Dental and Medical Sciences (IOSR-JDMS)* 2016;15(9)11-13.
- [6]. Manjula CP, Code QR. Accuracy of diagnosis by Fine Needle Non Aspiration Cytology technique in head and neck swellings: Its advantages and disadvantages in comparison to Fine Needle Aspiration Cytology. *International Journal of biomedical research.* 2017;8(05):280288.
- [7]. Kate MS, Kamal MM, Bobhate SK, Kher AV. Evaluation of fine needle capillary sampling in superficial and deep-seated lesions. *Actacytologica.* 1998;42(3):679-84.
- [8]. Mandava H, Hiremath S.S, Inamdar S.S, Gopinath D. Cytomorphological Features in Fine Needle Aspiration Cytology of Non-Neoplastic Lymph Node Lesions. *Indian Journal of Pathology: Research and Practice.* 2018;7(4)488-492.
- [9]. Garg M, Kaur J, Bindroo S, Mahajan N. Comparative and Evaluative Study of Fine Needle Aspiration Versus Capillary Sampling Techniques in Superficial Lymph Nodes. *National Journal of laboratory medicine.* 2014 Jun; 3(2):1-7.
- [10]. Mohan A, Thakral R, Kaur S, Singh S. "Fine Needle Aspiration Cytology in Metastatic Lymphadenopathy--A Five Year Experience in Muzaffarnagar Region". *Journal Of Advance Researches In Medical Sciences (Formerly Journal of Advance Researches in Biological Sciences).* 2013;5(2):172-6.
- [11]. Cervin JR, Silverman JF, Loggie BW, Geisinger KR. Virchow's node revisited. Analysis with clinicopathologic correlation of 152 fine-needle aspiration biopsies of supraclavicular lymph nodes. *Archives of pathology & laboratory medicine.* 1995 Aug;119(8):727-30.
- [12]. Lindberg R. Distribution of cervical lymph node metastases from squamous cell carcinoma of the upper respiratory and digestive tracts. *Cancer.* 1972 Jun;29(6):1446-9.
- [13]. Sinha SK, Basu K, Bhattacharya A, Banerjee U, Banerjee D. Aspiration cytodiagnosis of metastatic lesions with special reference to primary sites. *Journal of cytology.* 2003 Jan 1;20(1):16.
- [14]. Mair S, Dunbar F, Becker PJ, Du WP. Fine needle cytology--is aspiration suction necessary? A study of 100 masses in various sites. *Actacytologica.* 1989;33(6):809-13.
- [15]. Misra RK, Sharma SP, Nanda A, Rai SP. Diagnostic utility of fine needle sampling without aspiration in comparison to fine needle aspiration in head and neck swellings-A prospective study. *Journal of Cytology.* 2000 Apr 1;17(2):103.
- [16]. Akhtar M, Ashraf M, Huq M and Paul Kner C : Comparison of cellular yield with and without aspiration. *Diagnostic Cytology* 1989; 6 : 162165.
- [17]. Ghosh A, Misra RK, Sharma SP, Singh HN, Chaturvedi AK. Aspiration vsnonaspiration technique of cytodiagnosis--a critical evaluation in 160 cases. *Indian journal of pathology & microbiology.* 2000 Apr;43(2):107-12.

Shafira Bharti. "A Comparative Study of the Fine Needle Aspiration versus Fine Needle Non-Aspiration Technique of Cytodiagnosis in the Lymph Nodes Swellings." *IOSR Journal of Dental and Medical Sciences (IOSR-JDMS)*, vol. 18, no. 1, 2019, pp 04-09.