

Cholecystocolic Fistula: A Rare Complication of Gallstones

Dr.Ranga H.R.¹, Dr. Jain Udit², Dr.Kumar Ritesh³, Dr.Tayal Nikhil⁴

^{1,2,3,4}(Department of General Surgery,PT.B.D.Sharma,PGIMS,Rohtak/UHSR,India)

Corresponding Author: Dr.Ranga H.R.

Abstract: Cholecystocolic fistula is a rare but possible complication of cholelithiasis. Symptoms of cholecystocolic fistula are usually minimal and/or non-specific, and preoperative diagnostic tools often fail to show such a rare condition, hence diagnosis is often achieved intraoperatively. We report a case of 54-year male presented to us with complaints of right upper abdomen pain. Provisional diagnosis of cholelithiasis was made and intraoperatively a cholecystocolic fistula was found for which cholecystectomy and primary repair of colonic opening of the fistula was done. Post-operative stay of patient was uneventful and patient was discharged successfully. Cholecystocolic fistula is a rare entity which requires a high degree of suspicion to diagnose it preoperatively. Even if it is diagnosed intraoperatively, it can be managed appropriately with surgery.

Keywords: Cholecystocolic fistula, cholelithiasis

Date of Submission: 11-01-2019

Date of acceptance: 24-01-2019

I. Introduction

Cholecystocolic fistula is a rare but possible complication of cholelithiasis. The most common type of biliary enteric fistula is Cholecystoduodenal fistula (70%) followed by cholecystocolic fistula (10-20%) and the least common cholecystogastric fistula (1-3%). Symptoms of cholecystocolic fistula are usually minimal and/or non-specific, and preoperative diagnostic tools often fail to show such a rare condition, hence diagnosis is often achieved intraoperatively.

II. Case Report

A 54-year male presented with right upper abdomen pain for 7-8 years. Pain was often aggravated by taking fatty meals. There was no history of previous hospitalization for the same and patient did not have any jaundice. On hematological and biochemical investigation hisHb was 10.1g, TLC were 10000, platelets were 2.5 lacs, blood urea – 23, random blood sugar – 76, serum sodium – 144, serum potassium – 3.9, SGOT/PT – 57/88, serum ALP – 135 and viral markers were non-reactive. His chest X-ray was normal. His abdominal ultrasound showed a contracted gall bladder with mild thickening of the wall and show wall echo shadow complex, CBD was normal measuring 7mm. Pre-operative checkup was done and patient was admitted and planned for elective laparoscopic cholecystectomy.

Standard four ports for cholecystectomy were inserted and a laparoscope of 30 degrees was used. Dense adhesions were present between gall bladder and omentum and transverse colon. We converted it to open cholecystectomy. On further dissection, a cholecystocolic fistula was found as shown in Fig. 1 & 2. We proceeded with cholecystectomy and primary closure of colonic opening of the fistula. A drain was put in subhepatic space.

Post-operatively the patient remained stable. Abdominal drain and nasogastric tube were taken out on fifth post-operative day when clear water sips were started followed by semisolid and solid diet as the patient tolerated them. Patient was discharged on 8th post-op day under all satisfactory conditions.

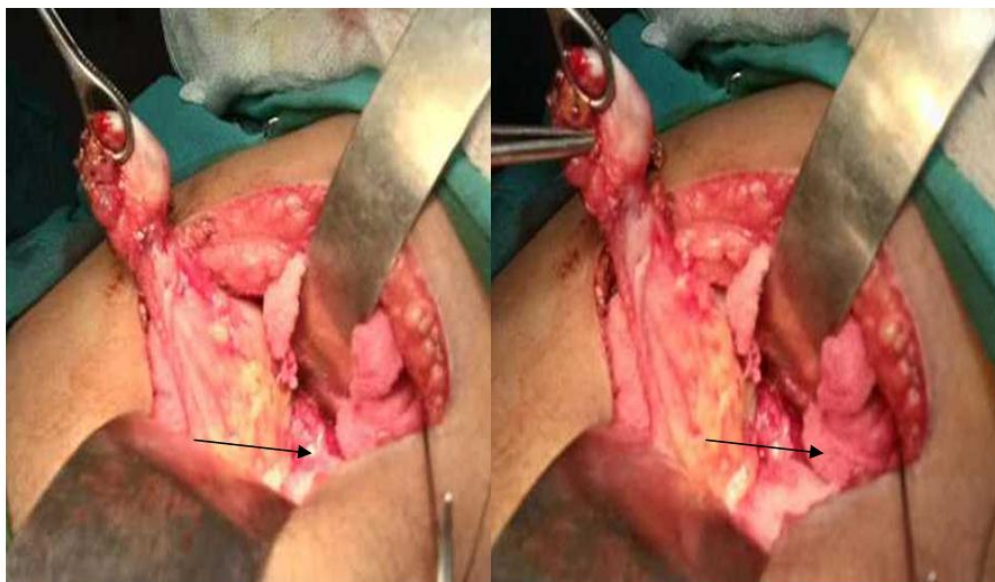


fig 1 cholecystocolic fistula

fig 2 cholecystocolic fistula

III. Discussion

Gall stones are the most common afflictions of the hepatobiliary system. Most often they remain asymptomatic or they may cause multiple problems. Biliary fistulas occur in 3-5% of patients with gallstones [1]. The most common type of biliary enteric fistula is cholecystoduodenal fistula(70%) followed by cholecystocolic fistula (10-20%) and the least commoncholecystogastric fistula (1-3%). The most common cause is pressure necrosis due to an impacted gallstone usually in the neck of gallbladder, which may erode into duodenum, colon or stomach[2]. The most common aids in diagnosis are plain film abdomen which reveals pneumobilia, ultrasonography and ERCP[3]. Although a diagnosis of cholecystoenteric fistula is rarely suspected clinically but it should be considered in patients with recurrent attacks of acute cholecystitis and the evidence of pneumobilia.

IV. Conclusion

Cholecystocolic fistula is a rare entity which requires a high degree of suspicion to diagnose it preoperatively. Even if it is diagnosed intraoperatively, it can be managed appropriately with surgery.

References

- [1]. AngrisaniL,CorcioneF,TartagliaA et al.Cholecystoenteric fistula (CF) is not a contraindication for laparoscopic surgery, *SurgEndosc.*2001;15:1038-41.
- [2]. Glenn F, Reed C, Grafe WR.Biliary enteric fistula.*SurgGynecol Obstet.*1981;153:527-31.
- [3]. Arvanitidis D, Anagnostopoulos GK, Tsiakos S, Margantinis G, Kostopoulos P.Cholecystocolic fistula demonstrated by endoscopic retrograde cholangiopancreatography. *Postgrad Med J.*2004;80:526.

Dr.Ranga H.R.. “Cholecystocolic Fistula: A Rare Complication of Gallstones.” *IOSR Journal of Dental and Medical Sciences (IOSR-JDMS)*, vol. 18, no. 1, 2019, pp 50-51.