

Arthrocentric Lavage with Piroxicam Injection in the Treatment of Anterior Disc Displaced TMJ with Closed Lock

Dr. Pranshu Kumar Pathak¹, Prof. Awadhesh Kumar Singh²,

Dr. Sudhanshu Agrawal³, Dr. Dipti Singh⁴, Dr. Dhananjay Kumar Mali⁵, Dr. Uday Kumar⁶

¹(Sr. Lecturer, Dept. of Oral Surgery, Purvanchal Institute of Dental Sciences, Gorakhpur, U.P., India)

²(Professor, Dept. of Periodontology, Chandra Dental College & Hospital, Barabanki, U.P., India)

³(Assoc. Professor, Dept. of Periodontology, Chandra Dental College & Hospital, Barabanki, U.P., India)

⁴(Assoc. Professor, Dept. of Oral Medicine, Chandra Dental College & Hospital, Barabanki, U.P., India)

^{5,6}(Jr. Resident, Dept. of Periodontology, Chandra Dental College & Hospital, Barabanki, U.P., India)

Corresponding author: Prof. Awadhesh Kumar Singh

Abstract:

Background: Arthrocentesis is an effective mode of treatment for closed lock jaws of TMJ when conservative methods have failed. Mouth opening is seen to increase in patients with restricted mouth opening due to close lock. Arthrocentesis is a joint lavage which washes out the inflammatory mediators, provides instant relieve from pain and has long lasting effects.

Aim: The aim of this study was to evaluate the efficacy of arthrocentric lavage with piroxicam injection in the treatment of anterior disc displaced TMJ with closed lock.

Materials and Methods: A female patient 18 years old with clinical and radiological diagnosis of TMJ dysfunction (TMJD), based on clinical diagnostic criteria were included in the study and underwent arthrocentesis followed by injection of piroxicam. Patient was treated with piroxicam injection following arthrocentesis to benefit from its anti-inflammatory characteristics. Post-operative and after one month mouth opening was recorded.

Results: There was significant improvement in pain, range of motion, and joint sounds. Mouth opening was 34 mm immediately after surgery and 37 mm after one month of surgery.

Conclusion: Arthrocentric lavage with piroxicam injection is safe, simple, minimally invasive and effective for the treatment of anterior disc displaced temporomandibular joint with closed lock.

Key words: Arthrocentesis, intra-articular injection, piroxicam, temporomandibular joint dysfunction

Date of Submission: 12-01-2019

Date of acceptance: 27-01-2019

I. Introduction

Lysis and lavage of the TMJ were first done using arthroscopy by Ohnishi.¹ It was then found that the mechanical lysis of adhesions and lavage of the temporomandibular joint (TMJ) was often successful in treating various internal derangements. Lavage of the upper joint compartment forces the flexible disc apart from the fossa, washes away degraded particles and inflammatory components, and decreases the intra-articular pressure whenever the joint is inflamed. Arthrocentesis has been reported to reduce joint pain, improve function, and reduce clicking. It is most commonly used to treat patients with anterior disc displacement without reduction (closed lock) and disc adhesion. It is also used as a palliative for acute episodes of degenerative or rheumatoid arthritis.²

Temporomandibular joint (TMJ) is a compound joint, composing of temporal bone and mandible, numerous associated muscles and a specialised fibrous tissue the articular disk.^{3,4} Anatomically TMJ is a diarthrodial synovial joint, dictating and limiting the freedom of discontinuous articulation between two bones. Functionally TMJ is a compound joint composed of four articulating surfaces with articular disk separating the joint into upper and lower compartments. The lower compartment permits hinge or rotatory motion while upper compartment permits sliding or translator movements. Articular disk is a non-vascularised, non-innervated dense fibrous tissue with adequate strength to resist pressure,³ and adapts to functional demands of articular surfaces due to its flexibility.⁵ Dysfunction of TMJ and associated masticatory system can be a source of acute or chronic orofacial pain and dysfunction.^{2,6} Three cardinal signs of TMJD may be limitation of mandibular movement, pain with mandibular function and joint sounds. Successful treatment depends on accurate assessment, comprehensive evaluation and diagnosis. Various non-surgical and surgical treatment modalities of TMJD have been contemporarily described. Arthrocentesis is a simple, safe and minimally invasive technique

for the treatment of TMJD. Significant improvements have been reported in terms of reduction in pain, mouth opening and clicking or popping sounds in the TMJ following arthrocentesis.⁶

II. Materials and Methods

The study was conducted at department of Oral and Maxillofacial Surgery, Purvanchal Institute of Dental Sciences, Gorakhpur, U. P., India. A female patient aged 18 years with clinical and radiological diagnosis of TMJD, based on clinical diagnostic criteria was included in the study. Patient was treated with piroxicam injection following arthrocentesis to benefit from its anti-inflammatory characteristics. Post-operative and after one month mouth opening was recorded.

Technique:

We have performed the procedure under a local anesthetic block of auriculotemporal nerve and infiltration into the areas of joint penetration. Surgical field is draped and painted with povidone iodine following the measurement of preoperative mouth opening 22 mm. External auditory canal is protected from accumulation of blood and fluid using a cotton pledget. Auriculotemporal nerve block with 2% lignocaine and 1:80,000 adrenaline is administered and superior joint space is entered at 2 point with an 18-gauge needle at antero-superio-medial direction reaching posterior aspect of articular eminence.

A cantho-tragal line is drawn from outer canthus of ipsilateral eye to midpoint of tragus. A point approximating the posterior extent of the articular fossa is marked 10 mm anterior to the mid-tragal point and 2 mm inferior to canthotragal plane. A second point is marked at 20 mm anterior to tragus and 10 mm inferior to canthotragal line corresponds to height of articular eminence. Several milliliters of Ringer's lactate solution is injected passively into the joint until there is rebound of syringe with mandibular movement. A second needle is inserted slightly anterior to first needle at 20-10 point for outflow of irrigant from joint space. After lavage is performed using approximately 500 ml of Ringer's lactate solution, joint is manipulated through opening, closing, protrusive and excursive movements of the mandible and postoperative mouth opening is measured. 2 ml (40 mg) of piroxicam was injected into the upper joint compartment following arthrocentesis (Figure 2).

III. Results

There was no any complaint or complication following arthrocentic lavage. There was significant improvement in pain, range of motion, and joint sounds. Immediate postoperative mouth opening achieved was 34 mm. (Figure 3) and 37 mm after one month (Figure 4).

IV. Discussion

Arthroscopy of the TMJ was first introduced by **Ohnishi** in 1975. Arthroscopic lysis and lavage can be used to treat those patients with painful clicking or popping, to release intraarticular adhesions and anteriorly displaced non-reducing discs, and to confirm other diagnostic findings that could warrant surgical intervention.³ There were 8 different methods for the lysis and lavage of the TMJ published in 8 papers, and a modification reported. According to the times when they were published these were: arthroscopic lysis and lavage,¹ two-needle arthrocentesis using an irrigation pump, modified two needle arthrocentesis, the double-needle cannula method, single-needle arthrocentesis, use of a single Shepard cannula with two ports and two lumens, two-needle arthrocentesis, single-puncture arthrocentesis, and two needle arthrocentesis with new anatomical landmarks.⁶

Various methods and routes for lysis and lavage of the temporomandibular joint (TMJ) had been reported (Figure 5). In **Ohnishi** Arthroscopy of the TMJ, trocar is inserted to joint space with suggested advantage of visualisation and examination of the joint space.¹ In **Nitzan** two-needle arthrocentesis, points of entry are A and B here the advantage was that it permits massive lavage of the joint, in addition to aspiration and injection.⁷ In **Laskin** modified two-needle arthrocentesis, points of entry are A and D with advantage that it is easier to insert the anterior needle.³ **Alkan et al.** two-needle arthrocentesis, points of entry are A and C with advantage of easier outflow was easier, and it may be reasonable, as repeated insertions of a needle are uncomfortable and adversely affect the success of the treatment.⁶

Piroxicam has been used for the treatment of rheumatoid arthritis and osteoarthritis. The parenteral formulation of piroxicam has an aqueous base, without an organic stabiliser and since the solvent for injection is distilled water, this formulation offers the potential for intra-articular administration. Piroxicam has also been shown to concentrate in the synovium rather than in the cartilage.⁷ In the present study, patients were treated with arthrocentesis and piroxicam injection following arthrocentesis to benefit from its anti-inflammatory characteristics. The success rate was falling in the 70–91% success range of previous studies.⁸

Piroxicam is a NSAID of the oxamicam class. It is a potent analgesic and anti-inflammatory agent and has an established efficacy in postoperative pain relief. In view of its long half-life (about 50 h), once daily administration is sufficient. Piroxicam is effective as an anti-inflammatory agent. There was statistically

significant difference between the preoperative and post operative measurements of mouth opening, pain and range of motion.⁹ Pathophysiology of TMJD could be described by several theories: (i) Changes in the shape and position of the articular disk, (ii) biomechanical and biochemical changes in TMJ, (iii) joint overloading may cause hypoxia and on termination of overloading reoxygenation occurs. The hypoxia-reperfusion cycle can lead to the release and production of reactive oxygen species leading to degradation of hyaluronic acid and reduced viscosity of synovial fluid,¹⁰ resulting in more friction and adhesion of articular surfaces. The complication rate for TMJ arthrocentesis has not yet been defined, but is considered to be less than that for TMJ arthroscopy. Possible complications of lysis and lavage also depend on the technique used.^{11,12}

V. Conclusion

Arthrocentic lavage with piroxicam injection is safe, simple, minimally invasive and effective for the treatment of anterior disc displaced temporomandibular joint with closed lock.

VI. Figures

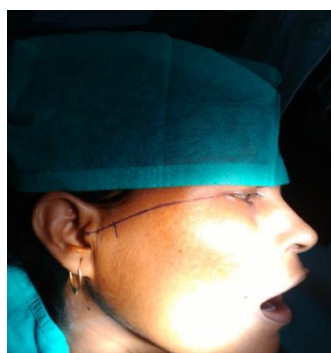

Figure 1: Pre-operative view

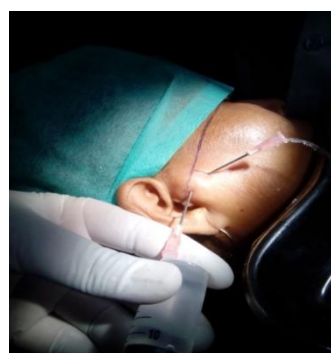

Figure 2: Intra-operative view

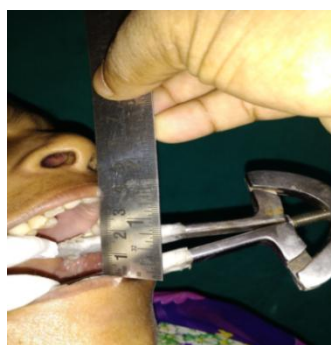

Figure 3: Mouth opening just after procedure

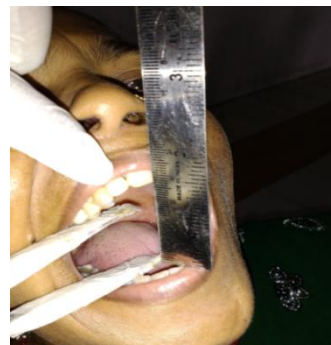

Figure 4: Mouth opening after one month

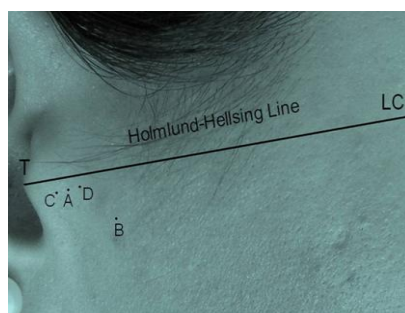


Figure 5: LC = lateral canthus; T = tragus; A = 10 mm from the middle of the tragus and 2 mm below the canthotragal line. B = 10 mm further along the canthotragal line and 10 mm below it; C = 7 mm anterior from the middle of the tragus and 2 mm inferior along the canthotragal line; and D = 2–3 mm in front of point A.

References

- [1]. Ohnishi M. Arthroscopy and arthroscopic surgery of the temporomandibular joint (TMJ). *Rev Stomatol Chir Maxillofac* 1990;91:143–50.
- [2]. Rayne J. Functional anatomy of the temporomandibular joint. *Br J Maxfac Surg* 1987;25:92-9.
- [3]. Laskin DM, Greene CS, Hylander WL. Temporomandibular disorders: an evidence-based approach to diagnosis and treatment. Chicago Quintessence, 2006;441–481.
- [4]. Miloro M, Ghali GE, Peter EL, Peter DW. Peterson’s Principles of Oral and Maxillofacial Surgery. 2nd ed. London: BC Decker Inc Hamilton; 2004. p. 963-89.
- [5]. DuBrul EL. Sicher’s oral anatomy. 7th ed. St. Louis (MO): C. V. Mosby;1980. p. 146-61, 174-209.
- [6]. Alkan A, Etöz OA. A new anatomical landmark to simplify temporomandibular joint arthrocentesis. *Br J Oral Maxillofac Surgery* 48 2010;310–311.
- [7]. Nitzan DW. Temporomandibular joint “open lock” versus dislocation: Signs and symptoms; imaging; treatment and pathogenesis. *J Oral Maxillofac Surg* 2002;60:506-11.
- [8]. Hosaka H, Murakami K, Goto K, Iizuka T. Outcome of arthrocentesis for temporomandibular joint with closed lock at 3 years follow-up. *Oral Surg Oral Med Oral Pathol Oral Radiol Endod* 1996;82:501-4.
- [9]. Reddy R, Reddy VS, Reddy S. Arthrocentesis - A minimally invasive treatment of temporomandibular joint dysfunction: Our experience. *J Dr NTR Univ Health Sci* 2013;2:196-200.
- [10]. Truelove EL, Sommers EE, Le Resche L, Dworkin SF, Von Korff M. Clinical diagnostic criteria for TMD. New classification permits multiple diagnoses. *J Am Dent Assoc* 1992;123:47-54.
- [11]. Carroll TA, Smith K, Jakubowski J. Extradural haematoma following temporomandibular joint arthrocentesis and lavage. *Br J Neurosurg* 2000;14:152–4.
- [12]. Tsuyama M, Kondoh T, Seto K, Fukuda J. Complications of temporomandibular joint arthroscopy: a retrospective analysis of 301 lysis and lavage procedures performed using the triangulation technique. *J Oral Maxillofac Surg* 2000;58:500–6.

Prof. Awadhesh Kumar Singh. “Arthrocentic Lavage with Piroxicam Injection in The Treatment of Anterior Disc Displaced TMJ with Closed Lock.” *IOSR Journal of Dental and Medical Sciences (IOSR-JDMS)*, vol. 18, no. 1, 2019, pp 21-24.