

"To Evaluate the Success Rate and Future Outcomes of Laparoscopic Orchidopexy Compared With Open Orchidopexy in Modern Era"

Dr. Ashutosh Kumar Singh
Corresponding Author: Dr. Abhishek Shukla
Dr. Gagandeep Shukla

ABSTRACT

INTRODUCTION- Isolated cryptorchidism is one of the most common congenital anomalies found at birth and affects about 3% of full-term male new-borns¹⁻³. Once cryptorchidism is diagnosed, treatment choices may include watchful waiting, hormonal treatment, or surgery & initial therapy is often selected on the basis of age at presentation and the location of the cryptorchid testicle^{21,22}

AIMS & OBJECTIVES- To evaluate the success rate of laparoscopic orchidopexy compared with that of open orchidopexy with comparison of post-operative morbidity & future outcomes.

MATERIAL & METHODS- A total of 40 patients were chosen after assessing inclusion/exclusion criteria. The patients were randomly divided in two groups.

Group A: 20 Patients undergoing open orchidopexy.

Group B: 20 Patients undergoing laparoscopic orchidopexy. patients were assessed on the day before surgery, on the postoperative day 1, postoperative day 3, postoperative day 7, for postop pain, scrotal oedema, resumption of bowel sounds, retention of urine, wound infections, on respective days

OBSERVATIONS & RESULTS- total of 20 testicles were operated in group A by laparoscopic method and 21 testicle were operated in group B by open method.

CONCLUSION- Results of our study revealed that the laparoscopic orchidopexy better than open orchidopexy in terms of

- Postoperative pain
- Mean time to resume bowel sound
- Duration of hospital stay
- Scrotal edema
- Wound infection
- Testicular site
- Testicular atrophy

Date of Submission: 12-01-2019

Date of acceptance: 27-01-2019

I. Introduction

Isolated cryptorchidism is one of the most common congenital anomalies found at birth and affects about 3% of full-term male new-borns¹⁻³. Unilateral cryptorchidism is more common than bilateral cryptorchidism, mostly on right side(70%).

Approximately 70% to 77% of crypt-orchid testes will spontaneously descend, usually by 3 months of age³. By 1 year of age, the incidence of cryptorchidism declines to about 1% and remains constant throughout adulthood³.

Although the exact etiology is still unknown, it is postulated that genetic, hormonal (hypothalamic-pituitary-gonadal axis dysfunction, congenital hypogonadotropic hypogonadism, testicular dysgenesis), and anatomical (short vas deferens and spermatic vessels) factors are involved⁴.

A birth weight <2.5 kg, being small for gestational age, prematurity, low maternal estrogen levels, and placental insufficiency with decreased human chorionic gonadotropins (hCG) secretion are suggested as risk factors for undescended testes⁴.

In addition, exposure to environmental factors such as persistent exposure to organochlorine compounds, mono-esters of the phthalates, maternal smoking, and maternal diabetes mellitus are also reported to be risk factors for maldevelopment of the male reproductive organs⁴. However, none of these factors has been shown to be solely responsible for the etiopathogenesis of undescended testes⁵.

Clinical examination findings reveal that 80% of undescended testes are palpable and sit in the inguinal superficial pouch (30%), the inguinal canal (20%), the upper scrotum (45%) and rarely (5%) in the perineum or the thigh and that 20% of undescended testis are non-palpable and are located in the abdominal cavity⁷.

The diagnosis of undescended testes is clinical. Nearly 20% of undescended testes are impalpable. There are several reasons for impalpable testes, including intraabdominal, intracanalicular or ectopic location of the testes, testicular dysgenesis and absence of the testes.

The use of imaging techniques in the diagnosis of impalpable testes is controversial. Today, it is recommended that impalpable testes should be examined by laparoscopic surgery with or without radiological guidance⁸.

Undescended Testes and the Rationale for Treatment

1- Risk for Infertility

Ten percent of infertile males have a history of undescended testes. The infertility risk is sixfold higher in patients with bilateral undescended testes compared to patients with unilateral undescended testis or with a healthy population¹⁰.

2- Risk for Cancer

The risk for cancer is 35 to 48 times higher in patients with undescended testes compared to the overall population¹³. The risk for malignant degeneration is 3-18% in these patients¹⁴. A total of 10% of testis malignancies are associated with undescended testes^{13,15,16}.

3- Risk for Torsion

The risk for torsion is higher in adult patients with undescended testes compared to overall population. A germ-cell tumor was reported to occur in 64% of such cases. It was also suggested that the risk for torsion was associated with the duration of the undescended testes¹⁷.

Once cryptorchidism is diagnosed, treatment choices may include watchful waiting, hormonal treatment, or surgery. In clinical practice, the choice of initial therapy is often selected on the basis of age at presentation and the location of the cryptorchid testicle^{21,22}. Watchful waiting may be used in boys <1 year of age with lower-lying testis in whom spontaneous descent is still a realistic possibility. Hormonal and surgical options are primarily selected on the basis of location and appearance of the undescended testicle. Hormonal treatment with luteinizing hormone releasing hormone (LHRH) analogs and/or human chorionic gonadotropin (hCG) could theoretically increase circulating androgens that may, in turn, promote testicular descent.

Surgical options include various forms of orchidopexy or orchidectomy. Primary orchidopexy (surgical mobilization of the testicle with placement and fixation in the scrotum) is usually performed for palpable cryptorchid testicles that are of relatively normal size and appearance that are located in the inguinal canal²¹.

This procedure can be performed as a single-stage operation, in which the vessels are ligated and the testicle is then placed into the proper position in the scrotum, or as a 2-stage procedure.

II. Aims And Objectives

AIM-

- To evaluate the success rate of laparoscopic orchidopexy compared with that of open orchidopexy.

OBJECTIVE-

- To evaluate post-operative morbidity of both method.
- To evaluate future outcome of both method in the terms of growth/atrophy.

III. Review Of Literature

The current method of testicular fixation within the subdartos pouch was first described by Schoemaker³⁷ in 1932 but was popularized by John K. Lattimer³⁸, at Columbia University, in 1957. He also worked out a way to implement gentle traction via an elastic band anchored in the vicinity of the patient's knee for 10 days.

With the inclusion of the subdartos pouch technique, the four key steps of standard orchidopexy were established just before the 1960s. The standard orchidopexy can be applied to almost all undescended testes with the exception of high undescended testes. The success rate ranges from 89% to 92%. Therefore, attention has turned to the treatment of high undescended testes which were not adequately treated by standard orchidopexy.

In 1979, Jones and Bagley suggested a high inguinal incision as the open surgical alternative for high canalicular or intraabdominal testes³⁹. In case of a high undescended testis, the testicular artery and veins often limit the distal mobility of these testes. As mentioned earlier, attempts to divide the testicular artery were made well before the 20th century. However, a high atrophy rate precluded wide application. In 1959, Fowler and Stephens⁴⁰ studied the vascular anatomy of the testis and devised a means to repair a high undescended testis and preserve its blood supply via collateral circulation. Children with a long, looping vas that extends down the

inguinal canal are the ideal candidates for this surgery, but less than one third of the children with intraabdominal testes were found to have this condition. Originally, Fowler and Stephens orchidopexy was known as a staged technique but it was further modified into a 2-staged operation with a better success rate (77% vs. 67%).

Bloom in 1991 described a procedure for staged pelviscopic orchidopexy⁴². The pure one-stage laparoscopic orchidopexy was first reported by Jordan and Winslow⁴³. Therapeutic laparoscopy has the advantage of

- 1) high magnification and improved visualization
- 2) capability of extensive vascular dissection up to the origin of gonadal vessels
- 3) minimal morbidity, and
- 4) the ability of creating a new internal ring medial to inferior epigastric vessels to achieve the straight vascular course to the scrotum.

Laparoscopic orchidopexy can be conducted as either one-stage orchidopexy with preservation of spermatic vessels or Fowler and Stephens orchidopexy. While current orchidopexy includes a variety of methods, all methods stem from the basic concepts of standard orchidopexy.

Docimo et al⁴⁵ reported that the overall success rate of open surgical orchidopexy was 74% for abdominal testes. Moreover, the same author reported that success rate was 77% for open staged Fowler-Stephens and 81% for open primary transabdominal orchidopexy.

However, recently Abolyosar A et al⁴⁶ presented better results with overall success rate was 85% and 90.5% for open and laparoscopic staged Fowler-Stephens orchidopexy, respectively.

According to Jordon GH et al⁴⁷ Between October 1991 and January 1993, 14 patients (16 testes) underwent minimally invasive surgery with 6 months of followup in all cases. No evidence of testicular loss or acute atrophy has occurred, with the entire procedure being accomplished by laparo-endoscopic techniques in all cases

According to Dave et al⁴⁸ presence of a long looping vas was associated with a higher atrophy rate following laparoscopic second stage Fowler-Stephens orchidopexy. Laparoscopic management of the long looping vas may be more challenging and, therefore/ in such cases open Fowler-Stephens orchidopexy may result in better success rates by preserving the integrity of the collateral vessels.

Merguerian PA et al⁴⁹ laparoscopy is now used routinely for the diagnosis of nonpalpable testes whatever further management is completed with laparoscopy or open surgery. Proceeding with a laparoscopic orchidopexy procedure for viable abdominal testis, is considered safe and effective with significantly less morbidity.

The main benefit of laparoscopy is the ability to start treatment as soon as a diagnosis is made. It is not appropriate to leave a nonpalpable testis untreated, unless it is diagnosed as vanishing testis. Orchidopexy or orchidectomy should to be carried out even when diagnostic imaging suggests intra-abdominal testis.

Laparoscopic surgery has a second advantage; namely, permitting minimum invasive surgery. Although laparotomy requires a relatively large surgical wound and ablation, laparoscopic surgery can be done with a few trocars and a small incision for guiding the testis. Furthermore, laparoscopic surgery seems to be better in terms of postoperative pain and clinical findings.

Lintula et al⁵⁰ although marginally longer in duration, primary Laparoscopic Orchidopexy appears to be a feasible, safe technique for the management of the low intra-abdominal testes, whereas the staged Fowler-Stephens Laparoscopic Orchidopexy may be more safe than primary Laparoscopic Orchidopexy in cases with high intra-abdominal testes.

According to Lowe et al⁵¹ Anatomic localization of nonpalpable testes facilitated accurate planning of operative repair, thereby potentially improving the ultimate result. Additionally, the technique rendered exploration unnecessary in patients with the intra-abdominal vanishing testis syndrome. No complications were noted as a result of laparoscopy in these patients.

According to Chang et al⁵² additional high overall success rate in placing the testis into the scrotum through laparoscopic procedures is considerably better than reported in other series to date. Laparoscopic Orchidopexy is an effective method for managing intra-abdominal testes in children. Patients who had undergone previous surgery had a higher risk of developing testicular atrophy. The additional dissection around the vas almost inevitably leads to testicular atrophy.

Dhanani et al⁵³ a high degree of success can be obtained for children with intra-abdominal testes. Mobility of the testis on exploration is a good indicator that the testis can be managed with primary Orchidopexy without division of the vessels. If primary Orchidopexy cannot be performed, excellent results are achieved with a staged Fowler-Stephens Orchidopexy.

To establish its high safety, improvements in laparoscopy operation skills and development of new surgical instruments are thought to be important. With the recent appearance of newly developed 2 or 3 mm trocars, endoscopes and forceps, less invasive laparoscopic surgery is becoming feasible. Laparoscopy for nonpalpable

testis is considered to be the most effective method for diagnosing the existence or absence of the testis and its location.

IV. Material And Methods

MATERIAL

This study was conducted on patients attended Outpatient Department of Surgery at S. N. Medical College, Agra, during the period from March 2014 to April 2015.

ELIGIBILITY CRITERIA

INCLUSION CRITERIA

Patients clinically diagnosed with non-palpable testes undergone laparoscopic and open orchidopexy were included in the study.

EXCLUSION CRITERIA

- Re-do surgery for failed orchidopexy.
- Orchidopexy for retractile testes.
- Orchidopexy for ascending testes.
- Orchidopexy beyond childhood.
- Trapped testes resulting from prior inguinal surgery.

METHODS

A total of 40 patients were chosen after assessing inclusion/exclusion criteria. The patients were randomly divided in two groups.

Group A: 20 Patients undergoing open orchidopexy.

Group B: 20 Patients undergoing laparoscopic orchidopexy.

The diagnosis of non-palpable testes was confirmed by examination under general anaesthesia in both the groups. In patients, testes palpable under general anaesthesia were excluded from study.

In the laparoscopic group (Group B) the laparoscopic findings were as follows:

- 1- Vanished testes, blind ended spermatic vessels.
- 2- Vessels and vas entering the ring.
- 3- High abdominal testes, found on iliac vessels.
- 4- Low abdominal testes, found between iliac vessels and internal ring.
- 5- Peeping testes, that emerges from internal ring.

Those in the first two categories were excluded from this study

For all high abdominal testes, laparoscopic first stage Fowler-Stephens (clipping of spermatic vessels) was performed initially. A second stage Fowler-Stephens orchidopexy was performed 3 months later. For low abdominal and peeping testes primary laparoscopic orchidopexy was performed. For bilateral cases one side was managed at a time and second side was treated 3 months later after the first in both groups.

Both groups were compared in respect of

Early Parameters-

- Duration of operation
- Postoperative pain
- Scrotal oedema
- Resumption of bowel sound
- Duration of hospital stay

Late Parameters-

- Testicular site
- Testicular atrophy

Patients assessments and outcome measurements

All the patients were assessed on the day before surgery, on the postoperative day 1, postoperative day 3, postoperative day 7, for postop pain, scrotal oedema, resumption of bowel sounds, retention of urine, wound infections, on respective days

Visual analogue pain scale was used for pain assessment and other parameters were assessed clinically.

Statistical Analysis:

The statistical analysis of data was done using Fisher's exact test and paired t test.

V. Observations And Results

A total of 40 patients were enrolled in the study, which were clinically diagnosed as non-palpable undescended testes. Two groups of 20 patients in each group was made randomly.

Group A: Comprised 20 patients in whom laparoscopic orchidopexy was done either by primary laparoscopic or by fowler Stephan staged laparoscopic orchidopexy.

Group B: Comprised 20 patients in whom primary open orchidopexy was done.

TABLE 1: DISTRIBUTION OF CASES ACCORDING TO AGE

Age group	Group A		Group B		Total	
	No.	%	No.	%	No.	%
< 2yrs	5	25	3	15	8	20
2-4 yrs	8	40	12	60	20	50
4-6 yrs	7	35	5	25	12	30
Total	20	100	20	100	40	100

p-value=0.4927

The groups are not significantly different.

Fisher's exact test is used

Table 2: Distribution of cases according to laterality

Side of undescended testes	Group A		Group B		Total	
	No.	%	No.	No.	No.	%
Right	12	60.00	10	50.00	22	55.00
Left	6	30.00	9	45.00	15	37.50
Bilateral	2	10.00	1	5.00	3	7.50
Total no. of patients	20	100.00	20	100.00	40	100.00
No. of testicle operated	22		21		43	

p-value=0.5509

The groups are not significantly different.

Fisher's exact test is used

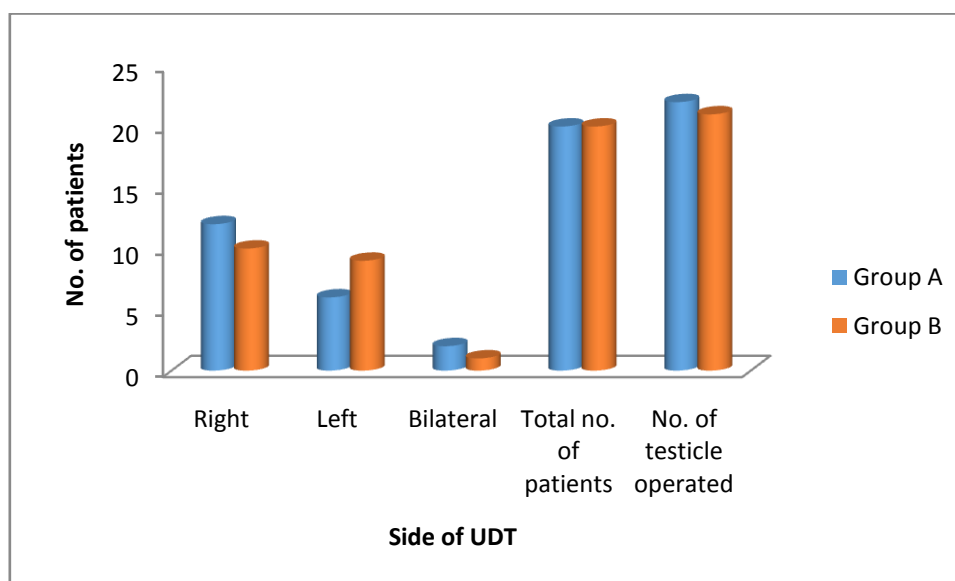
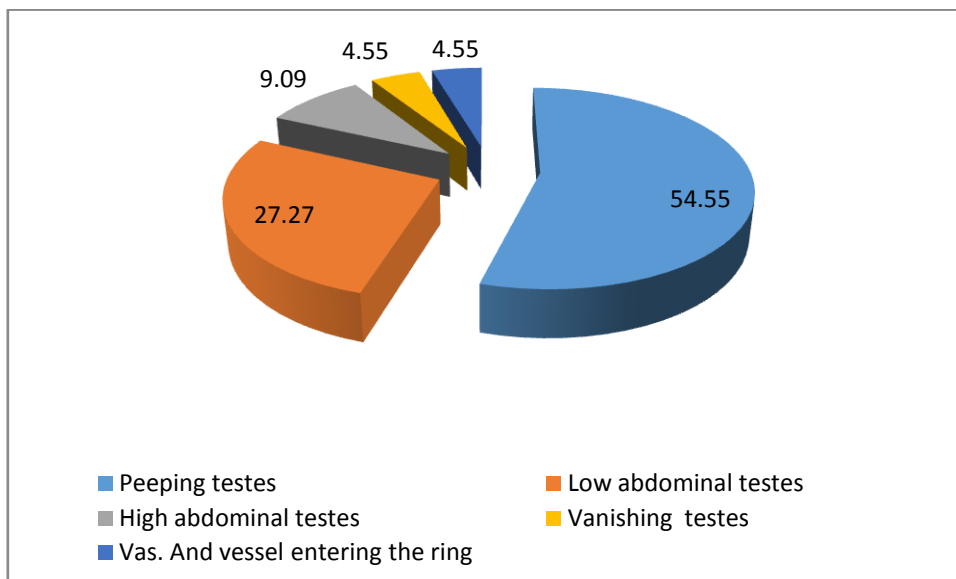


Table 3: intra operative findings /location of testes in group A

Location of testes	No.	%
Peeping testes	12	54.55
Low abdominal testes	6	27.27
High abdominal testes	2	9.09
Vanishing testes	1	4.55
Vas. And vessel entering the ring	1	4.55
Total	22	100.00



So a total of 20 testicles were operated in group A by laparoscopic method and 21 testicle were operated in group B by open method.

Table-4: Distribution of case according to type of procedure done

Type of procedure	Group A		Group B	
	No.	%	No.	%
Primary open orchidopexy			20	95.24
Primary lap orchidopexy	11	55.00		
One stage fowler step. method	6	30.00		
Two stage F.S. methods	2	10.00		
Orchidectomy	1	5.00	1	4.76
Total	20	100.00	21	100.00

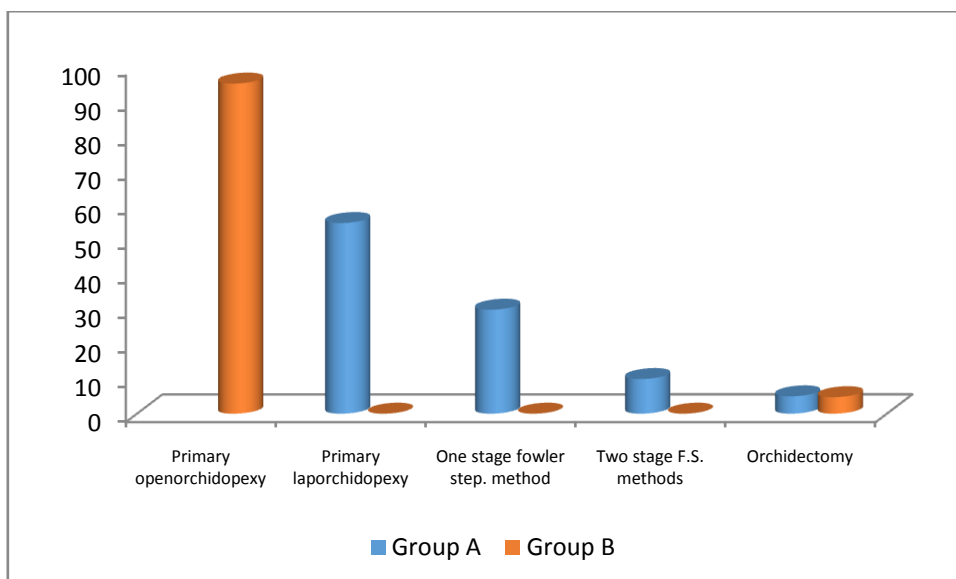
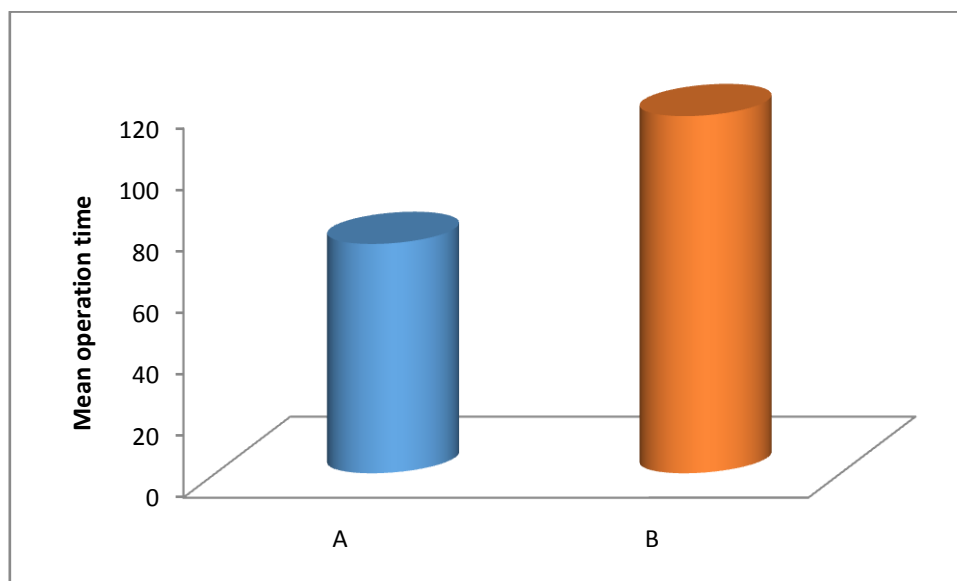


Table-5: Comparison of Operation Time in Group A and B

Groups	Operation Time (min.)			t-value	p-value
	Range	Mean	SD		
A	90-120	116.2	12.42	-9.629	<0.0001
B	60-90	74.6	14.8		



The two groups are significantly different with respect to Operation Time
 In group A average operative time was 90-120 minutes while in group B it was 60-90 minutes.

Table-6: Comparison of Hospital Stay in Group A and B

Groups	Hospital stay (hrs.)		t-value	p-value
	Mean	SD		
A	24.75	2.60	-48.4212	<0.0001
B	72.25	3.50		

In group A mean duration of hospital stay was 24.75 hrs while in group it was 72.25 hrs.

Table-7: Comparison of Post-Operative complications in Group A and B

	Group A (n=19)	Group B (n=20)	t-value	p-value
	Mean±SD	Mean±SD		
Resumption of bowel sound (hrs)	9.50±1.50	13.25±2.25	6.090	<0.0001
Pain	0.20±0.05	0.40±0.10	7.834	<0.0001
Oedema	2 (10.53)	3(15.00)		
Retention of urine	3(15.79)	4(20.00)		
Wound infection	1(5.26)	3(15.00)		
Prolonged Ileus (more than 24 hrs)	2(10.53)	3(15.00)		

(Figures in parentheses indicate percentage)

Table 8: Follow up comparison in Both groups

Testicular site	Group A	Group B
High inguinal	2(10.53)	4(21.05)
Bottom of scrotum	17(89.47)	15(78.95)
Total	19(100.00)	19(100.00)

(Figures in parentheses indicate percentage)

Table 9: Follow up comparison in Both groups

	Group A (n=19)	Group B (n=19)
Testicular atrophy	1(5.26)	2(10.52)

(Figures in parentheses indicate percentage)

VI. Discussion

Non palpable undescended testis has been identified as one of the common and classic indication for paediatric laparoscopy. The main advantage of laparoscopy are accurate localization of the testis and total avoidance of open exploration in some patient. The main criticism against inguinal exploration for a non palpable testis is that it may fail to locate an intra-abdominal testis.

In our study, inguinal exploration clearly identified the status of all 21 testis for which it was employed. Many of the clinically non palpable testis were either canalicular or low abdominal and was readily managed by standard inguinal approach.

In a report by **Lakhoo et al**⁴⁵ The author found viable testis in 59% of boys with previous negative inguinal exploration. **Kirsch et al**⁵⁵ reported a large experience with 447 non palpable testis, all of which were treated through standard inguinal incision. They concluded that the inguinal approach with transperitoneal mobilisation of vas and vessel is highly successful for intra-abdominal undescended testis. **William et al**⁵⁶ reported that in 37 of 39 non palpable testis, groin exploration was sufficient for deciding and executing treatment. **Adams and Allaway et al**⁵⁷ reported good results with inguinal exploration followed by preperitoneal approach for 110 non palpable testis. They concluded that the advantage of laparoscopy could be achieved by this open surgery with a favourable cost-benefit ratio.

In a randomised control trial, **Ferro et al**⁵⁸ concluded that laparoscopy only increased the operating time and cost without any significant advantage over open surgery.

Several authors reported excellent result with laparoscopic orchidopexy for non palpable testis.

Chang et al⁵² reported an overall success rate of 96% with laparoscopy orchidopexy for non palpable undescended testis. Similarly good results have been reported for staged laparoscopic Fowler-Stephens orchidopexy.

According to **Lintula et al**⁵⁰ although marginally longer in duration, primary Laparoscopic Orchidopexy appears to be a feasible, safe technique for the management of the low intra-abdominal testes.

Similar was the result of **Merguerian PA et al**⁴⁹ that laparoscopy is now used routinely for the diagnosis of nonpalpable testes whatever further management is completed with laparoscopy or open surgery. Proceeding with a laparoscopic orchidopexy procedure for viable abdominal testis, is considered safe and effective with significantly less morbidity.

Docimo et al⁴⁵ reported that the overall success rate of open surgical orchidopexy was 74% for abdominal testes. Moreover, the same author reported that success rate was 77% for open staged Fowler-Stephens and 81% for open primary transabdominal orchidopexy.

Only a few earlier reports compared laparoscopic versus open inguinal approach in non palpable undescended testis.

In our study, we also compared the two approaches and found that except in duration of operation and cost effectiveness laparoscopic orchidopexy is better than open orchidopexy in terms of postoperative complications and in long term efficacy in terms of testicular site and atrophy.

Both the groups were compared in terms of immediate postop complications and long term efficacy in terms of testicular site and atrophy.

Similar were the results of **Abolyosar A et al**⁴⁶ with overall success rate was 85% and 90.5% for open and laparoscopic staged Fowler-Stephens orchidopexy, respectively.

So the results of our study are little better than other studies done previously.

VII. Conclusion

The aim of the study was to evaluate the success rate of laparoscopic orchidopexy compared with that of open orchidopexy.

A total of 40 patients were enrolled in the study and two groups were made with each group having 20 patients. In one group patients were operated by open inguinal approach and in second group patients operated through laparoscopic approach.

Results of our study revealed that the laparoscopic orchidopexy better than open orchidopexy in terms of Postoperative pain (less in laparoscopic group)

- Mean time to resume bowel sound (less in laparoscopic group)
- Duration of hospital stay (shorter in laparoscopic group)
- Scrotal edema (less in laparoscopic group)
- Wound infection (low in laparoscopic group)
- Testicular site (better in laparoscopic group)
- Testicular atrophy (less in laparoscopic group)

Bibliography

- [1]. Scorer CG, Farrington GH: Congenital Deformities of the Testis and Epididymis, New York, Appleton-Century-Crofts, 1971.
- [2]. Cryptorchidism: A prospective study of 7500 consecutive male births, 1984-8. John Radcliffe Hospital Cryptorchidism Study Group. Arch Dis Child 1992; 67:892-899.
- [3]. Berkowitz GS, Lapinski RH, Dolgin SE, et al: Prevalence and natural history of cryptorchidism. Pediatrics 1993; 92:44-49.
- [4]. Virtanen HE, Bjerknes R, Cortes D, Jorgensen N, Rajpert-De Meyts E, Thorsson AV, Thorup J, Main KM. Cryptorchidism: classification, prevalence and long-term consequences. Acta Paediatr. 2007;96:611-616.

- [5]. Ritzen EM, Bergh A, Bjerknes R, Christiansen P, Cortes D, Haugen SE, Jorgensen N, Kollin C, Lindahl S, Lackgren G, Main KM, Nordenskjold A, Rajpert-De Meyts E, Soder O, Taskinen S, Thorsson A, Thorup J, Toppari J, Virtanen H. Nordic consensus on treatment of undescended testes. *ActaPaediatr*. 2007;96:638–643.
- [6]. Ashley RA, Barthold JS, Kolon TF. Cryptorchidism: pathogenesis, diagnosis, treatment and prognosis. *UrolClin North Am*. 2010;37:183–193.
- [7]. Mouriquand PD. Undescended testes in children the paediatric urologist's point of view. *Eur J Endocrinol*. 2008;159(Suppl 1):83–86.
- [8]. Hutson JM, Clarke MC. Current management of the undescended testicle. *SeminPediatr Surg*. 2007;16:64–70.
- [9]. Davenport M, Brain C, Vandenberg C, Zappala S, Duffy P, Ransley PG, Grant D. The use of the hCG stimulation test in the endocrine evaluation of cryptorchidism. *Br J Urol*. 1995;76:790–794.
- [10]. Chung E, Brock GB. Cryptorchidism and its impact on male fertility: a state of art review of current literature. *Can UrolAssoc J*. 2011;5:210–214.
- [11]. Hadziselimovic F, Herzog B. Importance of early postnatal germ cell maturation for fertility of cryptorchid males. *Horm Res*. 2001;55:6–10.
- [12]. Cortes D, Thorup J, Lindenberg S, Visfeldt J. Infertility despite surgery for cryptorchidism in childhood can be classified by patients with normal or elevated follicle-stimulating hormone and identified at orchidopexy. *BJU Int*. 2003;91:670–674.
- [13]. Leissner J, Filipas D, Wolf HK, Fisch M. The undescended testis: considerations and impact on fertility. *BJU Int*. 1999;83:885–891.
- [14]. Jannini EA, Screponi E, Mazzone D, D'Armiento M, Lorenzo N., Di Cryptorchidism: current views. *Minerva Endocrinol*. 1995;20:201–210.
- [15]. Gapany C, Frey P, Cachat F, Gudinchet F, Jichlinski P, Meyrat BJ, Ramseyer P, Theintz G, Burnand B. Management of cryptorchidism in children guidelines. *Swiss Med Wkly*. 2008;138:492–498.
- [16]. Kaefer M. Diagnosis and treatment of the undescended testicle. In: Pescovitz O, Eugster E, editors. *Pediatric Endocrinology*. USA: Lipincott Williams &Wilkins; 2004. pp. 255–274.
- [17]. Walsh TJ, Dall'Era MA, Croughan MS, Carroll PR, Turek PJ. Prepubertalorchidopexy for cryptorchidism may be associated with lower risk of testicular cancer. *J Urol*. 2007;178:1440–1446.
- [18]. Docimo SG, Silver RI, Cromie W. The undescended testicle: diagnosis and management. *Am Fam Physician*. 2000;62:2037–2044.
- [19]. Bertelloni S, Baroncelli GI, Ghirri P, Spinelli C, Saggese G. Hormonal treatment for unilateral inguinal testis: comparison of four different treatments. *Horm Res*. 2001;55:236–239.
- [20]. Cortes D, Thorup J, Visfeldt J. Hormonal treatment may harm the germ cells in 1 to 3-year-old boys with cryptorchidism. *J Urol*. 2000;163:1290–1292.
- [21]. Elder JS. The undescended testis. Hormonal and surgical management. *SurgClin North Am*. 1988;68:983–1005.
- [22]. Khatwa UA, Menon PS. Management of undescended testis. *Indian J Pediatr*. 2000;67:449–454.
- [23]. Tackett LD, Patel SR, Caldamone AA. A history of cryptorchidism: Lessons from the eighteenth century. *J Pediatr Urol*. 2007;3:426–432.
- [24]. Adams JE. Remarks on a case of transition of the testicle into the perineum. *Lancet*. 1871;1:710.
- [25]. Annandale T. Case in which a testicle congenitally displaced into the perineum was successfully transferred to the scrotum. *Br Med J*. 1879;1:7.
- [26]. Schüller M. On inguinal testicle, and its operative treatment by transplantation into the scrotum. *Ann Anat Surg*. 1881;4:89.
- [27]. Bidwell LA. Modified operation for the relief of undescended testis. *Lancet*. 1893;1:1439.
- [28]. Bevan AD. Operation for undescended testicle and congenital inguinal hernia. *JAMA*. 1899;33:773.
- [29]. Bevan AD. The surgical treatment of undescended testicle: a further contribution. *JAMA*. 1903;41:718.
- [30]. Eisendrath DN. Undescended testis. *Ann Surg*. 1916;64:324–328.
- [31]. Moore CR, Oslund R. Experiments on the sheep testis-cryptorchidism, vasectomy and scrotal insulation. *Am J Physiol*. 1924;67:595.
- [32]. Eccles WM. The Hunterian lectures on the anatomy, physiology, and pathology of the imperfectly descended testis, lecture I. *Br Med J*. 1902;1:503.
- [33]. Torek F. The technique of orcheopexy. *New York Med J*. 1909;90:948.
- [34]. Keetley CB. Two cases of retained testis presenting points of special interest. *Trans Med SocLond*. 1894;17:349.
- [35]. Cabot H, Nesbit RM. Undescended testis. *Arch Surg*. 1931;22:850.
- [36]. Prentiss RJ, Weickgenant CJ, Moses JJ, Frazier DB. Undescended testis: surgical anatomy of spermatic vessels, spermatic surgical triangles and lateral spermatic ligament. *J Urol*. 1960;83:686–692.
- [37]. Schoemaker J. Uber Kryptorchismus und seine behandlung. *Chirurg*. 1932;4:1–3.
- [38]. Lattimer JK. Scrotal pouch technique for orchidopexy. *J Urol*. 1957;78:628–632.
- [39]. Jones PF, Bagley FH. An abdominal extraperitoneal approach for the difficult orchidopexy. *Br J Surg*. 1979;66:14–18.
- [40]. Fowler R, Stephens FD. The role of testicular vascular anatomy in the salvage of high undescended testes. *Aust N Z J Surg*. 1959;29:92–106.
- [41]. Cortesi N, Ferrari P, Zambarda E, Manenti A, Baldini A, Morano FP. Diagnosis of bilateral abdominal cryptorchidism by laparoscopy. *Endoscopy*. 1976;8:33–34.
- [42]. Bloom DA. Two-step orchidopexy with pelviscopic clip ligation of the spermatic vessels. *J Urol*. 1991;145:1030–1033.
- [43]. Jordan GH, Winslow BH. Laparoscopic single stage and staged orchidopexy. *J Urol*. 1994;152:1249–1252.
- [44]. Smoiko MJ, Kaplan GW, Brock WA (1983) Location and fate of the nonpalpable testis in children. *J Urol* 129:1204-1206.
- [45]. Docimo SG (1995) The results of surgical therapy for cryptorchidism: a literature review and analysis. *J Urol* 154:1148-1152.
- [46]. Abolyosr A (2006) Laparoscopic versus open orchidopexy in the management of abdominal testis: a descriptive study. *Int J Urol* 13:1421-1424.
- [47]. Jordan GH, Winslow BH (1994) Laparoscopic single stage and staged orchidopexy. *J Urol* 152:1249-1252.
- [48]. Dave S, Manaboriboori IM, Braga LH et al (2009) Open versus laparoscopic staged Fowler-Stephens orchidopexy: impact of long loop vas. *J Urol* 182:2435-2439.
- [49]. Merguerian PA, Mevorach RA, Shortliffe LD et al (1998) Laparoscopy for the evaluation and management of the nonpalpable testicle. *Urology* 51:3-6.
- [50]. Lintula H, Kokki H, Eskelinen M et al (2008) Laparoscopic versus open orchidopexy in children with intra-abdominal testes. *J LaparoendoscAdvSurg Tech A* 18:449-456.
- [51]. Lowe DH, Brock WA, Kaplan GW (1984) Laparoscopy for localization of nonpalpable testes. *J Urol* 131:728-729.
- [52]. Chang B, Palmer LS, Franco I (2001) Laparoscopic orchidopexy: a review of a large clinical series. *BJU Int* 87:490-493.

- [53]. Dhanani NN, Cornelius D, Gunes A et al (2004) Successful outpatient management of the nonpalpable intra-abdominal testis with staged Fowler-Stephens orchiopexy. J Urol 172:2399-2401.
- [54]. Lakhoo K, Thomas DFM, Nijmaldin AS, Is inguinal exploration for impalpable testes an outdated operation? Br J Uro 1996; 77: 452-454.
- [55]. Kirsch AJ, Escala J, Duckett JW, Smith GH, Zdemec SA, Canning DA, Synder HM 3rd, Surgical management of nonpalpable testes: the Children's hospital of Philadelphia experience. J Urol 1998 ; 159: 1340-1343.
- [56]. Williams EV, Appanna T, Foster ME. Management of the impalpable testis: A six year review together with a national experience. Postgrad Med J 2001; 77 : 320-322.
- [57]. Adam AS, Allaway AJ. The difficult orchidopexy: The value of the abdominal preperitoneal approach. BJU Int 1999; 83: 290-293.
- [58]. Ferro F, Spagnoli A, Zaccara A, De Vico A , La Sala E. Is preoperative laparoscopy useful for impalpable testis? J Urol 1999; 162: 995-996.

Dr. Ashutosh Kumar Singh. "To Evaluate the Success Rate and Future Outcomes of Laparoscopic Orchidopexy Compared With Open Orchidopexy in Modern Era"" IOSR Journal of Dental and Medical Sciences (IOSR-JDMS), vol. 18, no. 1, 2019, pp 50-59.