

A Study 47 cases of Soft Tissue Defects with various Plastic Surgical Procedures in Orthopaedic practice

Dr.V.S.Ravindranath¹, Dr. MettuSri Ranga Rao², Dr. V. Lakshmi Sravanthi³

¹Professor of Orthopaedics,

²Associate Professor, Osmania Medical College, Hyderabad, Telangana,

³junior resident, GMC, Hyderabad, India.

Corresponding author: Dr. Mettu. Sri Rangarao,

Abstract:

Back ground: The purpose of this study is to evaluate results of the soft tissue injuries with Orthopaedic problems in 47 patients in Osmania General Hospital (OGH) under Osmania Medical College (OMC), Hyderabad, Telangana, during JAN2001 to DEC 2003.

Materials and Methods: The study of 47cases orthopaedic trauma with soft tissue injuries treated in the teaching hospital Osmania General Hospital, Osmania Medical College , Hyderabad during Jan 2001 to December 2003. The cases were followed for a period of 3 years and their outcome was assessed clinically.

Results: The mean follow up period was 3 years. The outcome was excellent in 45cases. One case had partial flap necrosis and the other case was lost in the follow up.

Key words: Dedridement, Fascio cutaneous flap, De- epithelialized flap, Osteofascio cutaneous flap.

Date of Submission: 14-01-2019

Date of acceptance: 31-01-2019

I. Back ground

With the increasing velocity of the vehicular movements there is rapid increase of the trauma cases with extensive soft tissue damages. The management of the soft tissues is also as important as the management of the skeletal trauma. The present study includes the different modalities of the soft tissue management in 32 cases over a period of 3 years .The injuries were classified as per the Gustillo's Classification. All the cases were assessed clinically in the emergency department and were stabilized haemodynamically. The cases were investigated as per the trauma protocol and the soft tissues around the wounds were assessed clinically. The wounds were categorized into different groups depending on the type of the soft tissue covers needed. We have executed the following types of the flap covers like: Fascio cutaneous flaps, Cross leg flaps, De-epithelialized flaps, Myo-cutaneous flaps, Muscle flaps, 2 groin flaps, 2 reverse Sural artery flaps, one Osteofascio cutaneous flap.

Inclusion criteria:

1. Patients between 20 years to 50 years
2. Associated with orthopaedic trauma
3. No distal neurovascular deficit

Exclusion Criteria:

1. Old patients with co-morbid conditions like diabetes mellitus, peripheral vascular diseases.
2. Poly trauma
3. Non complacent patients

II. Introduction

The blood supply to the skin of the entire posterior calf to 5 cm above the medial malleolus and 7 cm above the lateral malleolus is primarily from vessels that perforate the fascia of the underlying medial and lateral gastrocnemius muscles. Distal to the muscle bellies, these perforators run superficial to the Achilles tendon. This neurovascular bundle is stretchable to at least 4.5 to 5cm when the muscle origins are detached, allowing distal mobilization of the functioning musculocutaneous unit.

Surgical procedures:

All the patients were received in the Emergency department of the teaching hospital. Each case was assessed by classifying by Gustillio’s method. After thorough work up for the fitness for anaesthesia, initially debridement was done to demark the soft tissue defect. The skeleton was stabilized by either external fixator or by internal fixation. The external fixators were applied in such a way that wounds were not covered by the fixators. We had performed 19 fascio cutaneous flaps, 4 cross leg flaps, 6 myofascio cutaneous flaps, 12 muscle flaps, 2 groin flaps, 2 reverse Sural artery flaps, one Osteofascio cutaneous flap and one de-epithelialized fascio cutaneous flap. The muscle flaps consisted of 10 Medial Head Gastrocnemius and 2 Sural muscle flaps. Among the fascio cutaneous flaps 12 cases were on proximal based and 7 were distal based flaps. One case of De-epithelialized flap was done for a chronic Osteomyelitis of the Tibia with a cavity wherein the tip of the flap was de-epithelialized and was packed in to occlude the cavity and to prevent the infection. In all cases the secondary defects were covered with split thickness skin graft.

III. Discussion

With increase in the technology of the vehicular speed and violent anti social activities and the military activities, the compound injuries are also at its peak in Orthopaedic practice. The common age group of these patients is in the most productive period and early mobilization is very essential. Historically these injuries were managed by the general surgeons. We had studied 47 cases that attended the tertiary care of our hospital. All these cases were managed by the trauma protocol of our institute. The initial DCO (damage control orthopaedic) protocol i.e. wound debridement and temporary skeletal stabilization was followed. All the compound injuries were classified by Gustillio’s. Later on definitive plastic surgical procedures such as Fascio-cutaneous, myofascio-cutaneous, muscle flap, cross leg flap, reverse Sural artery flap, groin flap and a de-epithelialized Fasciocutaneous flap were done.

The literature study of Flaps in compound fractures

By Godina⁷ on failure rates. Table: 1

Group I	Flaps within 75 hours	the failure rate is 0.75%
Group II	Flaps between 3 days to 3 months	the failure rate is 12%
Group III	Flaps beyond 3 months	the failure rate is 9.5%

Byrd et al¹⁴ advocated the Timing of Reconstruction: Table: 2

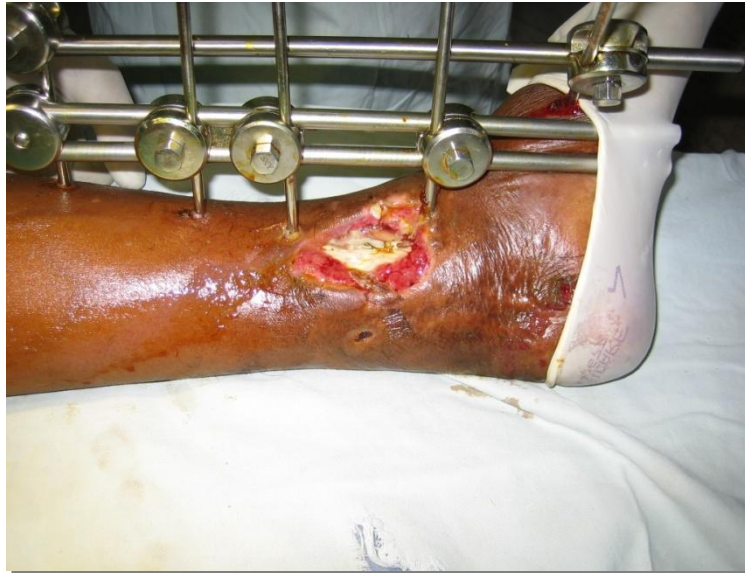Acute	Contaminated wound, not infected	1 –5 days
Sub acute	Colonized and infected wound	1 –6 weeks
Chronic	Infection limited to the scar, sequestra, granulating, contracting wound	>6 weeks

Our study: Table: 3

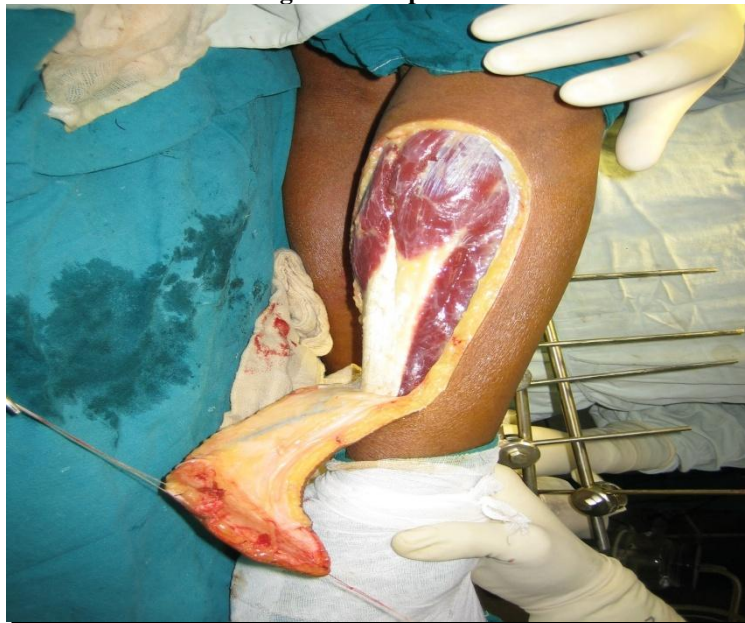Type of Flaps	Number
Fasciocutaneous flaps	19
Cross leg flaps	4
Myofasciocutaneous flaps	6
Muscle flaps	12
Groin flaps	2
Reverse Sural artery flaps	2
Osteo fascio cutaneous flap	1
De epithelialized fasciocutaneous flap	1
Total number of cases (flaps)	47

Surgical Procedure: by illustrations

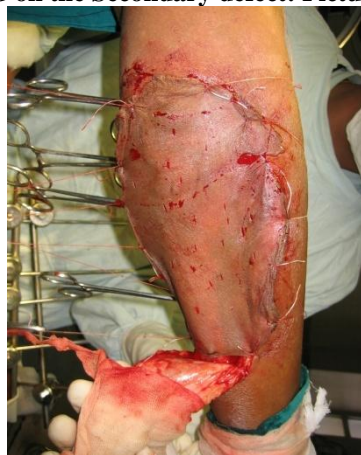After wound debridement: Picture: 1



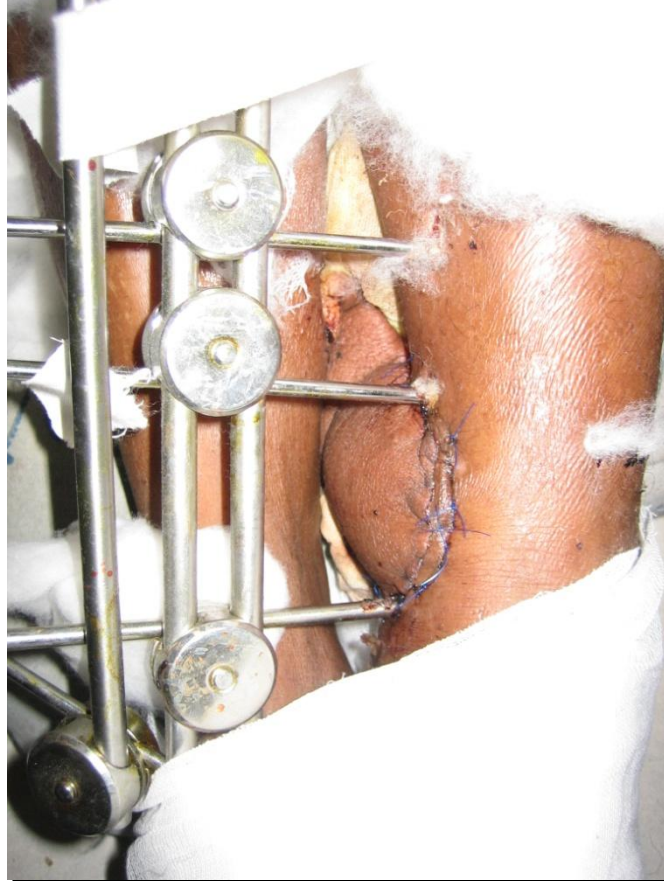Raising of the Flap: Picture: 2



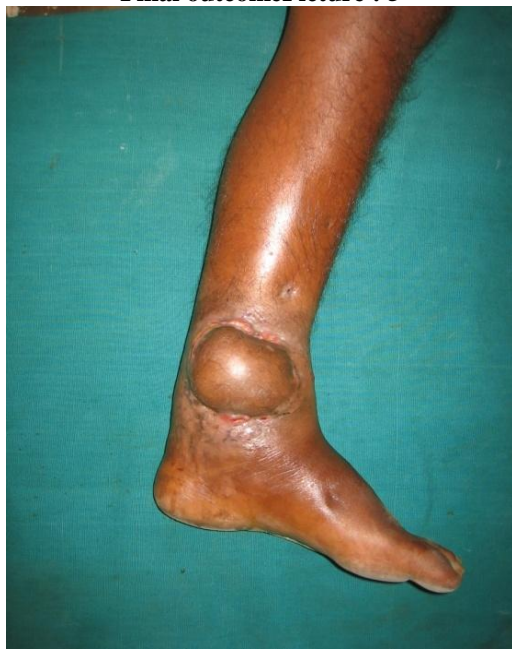SSG on the Secondary defect: Picture: 3



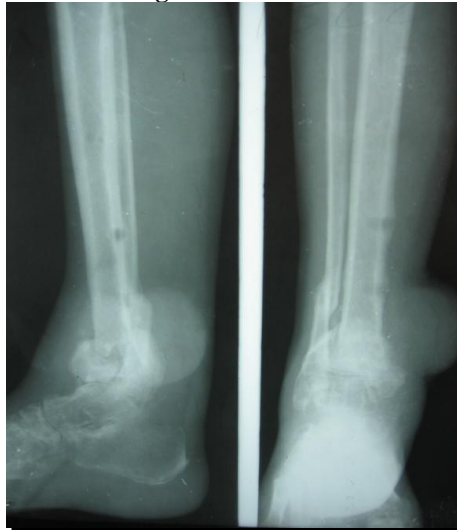
Final inset over the primary defect Picture : 4



Final outcome Picture : 5

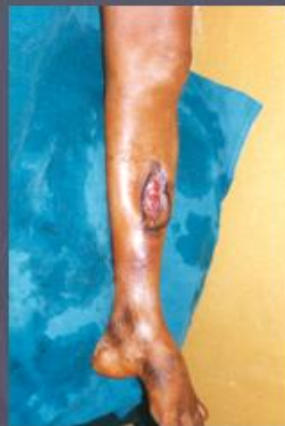

Radiological union Picture :6

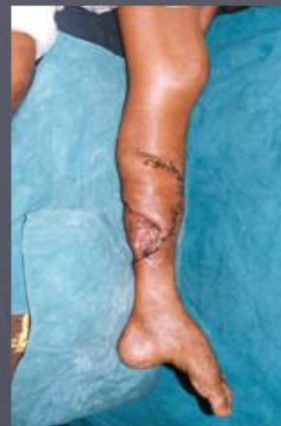

Picture : 7

Myofasciocutaneous flap



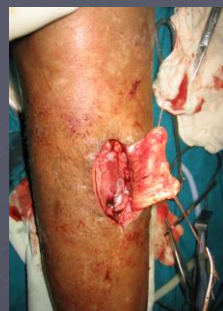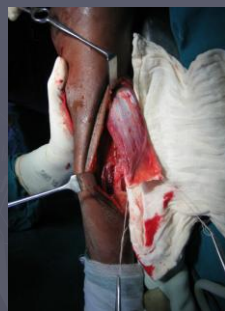Primary defect



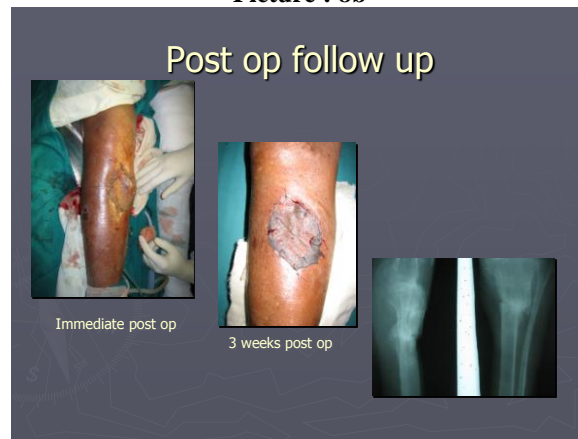4 weeks follow up

Picture : 8a

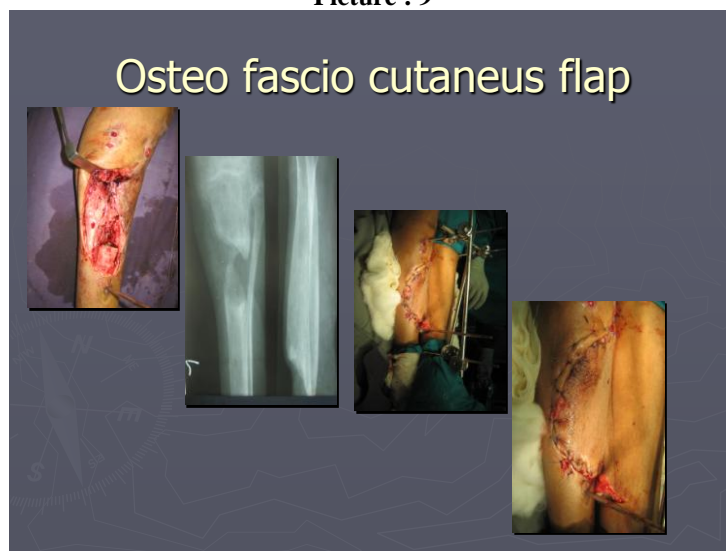
Gastrocnemius muscle flap



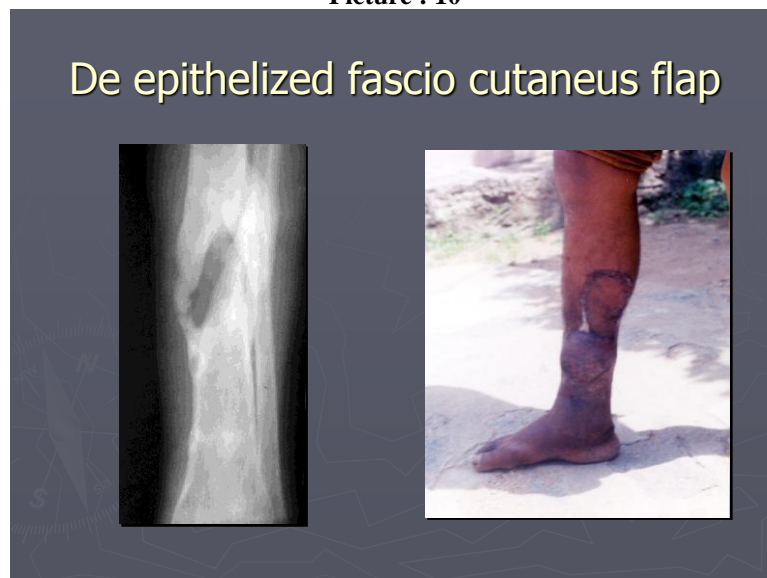Picture : 8b



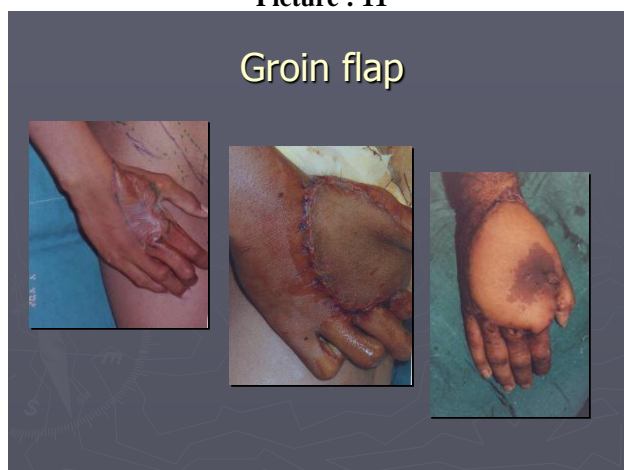
Picture : 9



Picture : 10



Picture : 11



IV. Results

These cases were followed post operatively for 3months to 2 & half years. In all the cases the flaps were well taken up and the soft tissue defects were well covered. Thus the patients had no morbidity and had speedy recovery.

V. Conclusions

This was study of 47 cases of compound fractures lower limb treated at the tertiary care teaching hospital. All the fractures were managed by the trauma protocol of the institute like wound debridement, skeletal stabilization and followed by definitive plastic surgical procedures by the Orthopaedic surgeons alone . All the flaps were successfully taken up in the prescribed time duration of 3 to 6 weeks. Thus the morbidity of these patients in terms of hospital stay, financial and psychological stresses was drastically reduced.

Conflict of interest ---NIL

References

- [1]. Am J Surg. 1991 Jun;161(6):693-701.Treatment of compound fractures.Seligson D¹, HenrySL.
- [2]. Witmer, Daniel K.; Marshall, Silas T.; Browner, Bruce D. (2016). "Emergency Care of Musculoskeletal Injuries". In Townsend, Courtney M.; Beauchamp, R. Daniel; Evers, B. Mark; Mattox, Kenneth L. *Sabiston Textbook of Surgery* (20th ed.). Elsevier. pp. 462–504. ISBN 978-0-323-40163-0.
- [3]. Roberto Schubert. "Fractures of the extremities (general rules and nomenclature)". *Radiopaedia*. Retrieved 2018-02-21.
- [4]. March 1937THE MANAGEMENT OF COMPOUND FRACTURES,HENRY H. RITTER, .*D.Arch Surg.* 1937;34(3):527-534. doi:10.1001/archsurg.1937.01190090152007
- [5]. Richards RR, Schemitsch EH. Effect of muscle flap coverage on bone blood flow following devascularization of a segment of tibia: an experimental investigation in the dog. *J Orthop Res.* 1989;7(4):550–8. [PubMed]
- [6]. Naique SB, Pearse M, J N. Management of severe open tibial fractures: the need for combined orthopaedic and plastic surgical treatment in specialist centres. *J Bone Joint Surg Br.* 2006;88(3):351–7.[PubMed]
- [7]. Godina M. Early microsurgical reconstruction of complex trauma of the extremities. *PlastReconstr Surg.* 1986;78(3):285–92. [PubMed]
- [8]. Liu R, Schindeler A, Little DG. The potential role of muscle in bone repair. *J Musculoskelet Neuronal Interact.* 2010;10(1):71–6. [PubMed]
- [9]. Holden CE. The role of blood supply to soft tissue in the healing of diaphyseal fractures. An experimental study. *J Bone Joint Surg Am.* 1972;54(5):993–1000. [PubMed]
- [10]. Gosain A, et al. A study of the relationship between blood flow and bacterial inoculation in musculocutaneous and fasciocutaneous flaps. *PlastReconstr Surg.* 1990;86(6):1152–62. discussion 1163.[PubMed]
- [11]. Harry LE, et al. Comparison of the healing of open tibial fractures covered with either muscle or fasciocutaneous tissue in a murine model. *J Orthop Res.* 2008;26(9):1238–44. [PubMed]
- [12]. Harry LE, et al. Comparison of the vascularity of fasciocutaneous tissue and muscle for coverage of open tibial fractures. *PlastReconstr Surg.* 2009;124(4):1211–9. [PubMed]
- [13]. Gopal S, et al. Fix and flap: the radical orthopaedic and plastic treatment of severe open fractures of the tibia. *J Bone Joint Surg Br.* 2000;82(7):959–66. [PubMed]
- [14]. Byrd HS, Cierny G, 3rd, Tebbetts JB. The management of open tibial fractures with associated soft-tissue loss: external pin fixation with early flap coverage. *PlastReconstr Surg.* 1981;68(1):73–82.[PubMed]
- [15]. Fischer MD, Gustilo RB, Varecka TF. The timing of flap coverage, bone-grafting, and intramedullary nailing in patients who have a fracture of the tibial shaft with extensive soft-tissue injury. *J Bone Joint Surg Am.* 1991;73(9):1316–22. [PubMed]
- [16]. Hallock GG. Complications of 100 consecutive local fasciocutaneous flaps. *PlastReconstr Surg.* 1991;88(2):264–8. [PubMed]

Dr. Mettu. Sri Rangarao,. "A Study 47 cases of Soft Tissue Defects with various Plastic Surgical Procedures in Orthopaedic practice." *IOSR Journal of Dental and Medical Sciences (IOSR-JDMS)*, vol. 18, no. 1, 2019, pp 41-47.