

A study of Locking compression plate as external fixator in the definitive management of open diaphyseal fractures of tibia in adults.

Dr. Shrinivas Prabhu¹, Dr. Binayak Ray²

¹(PGT, Department of Orthopaedics, RIMS, Imphal, India)

²(PGT, Department of Orthopaedics, RIMS, Imphal, India)

Corresponding Author: Dr. Binayak Ray

Abstract: Background: Locking compression plate as an external fixator for the definitive management of open fracture of tibia decreases both cost and trauma to the soft tissue. Though LCP is mechanically less rigid construct compared to conventional external fixators, it is clinically stable enough to maintain the reduction. LCP is light weight, comfortable and convenient for patients in daily life activities. The aim of this study is to evaluate the results of locking compression plate used as an external fixator for the definitive management of open fracture of tibial diaphysis in 35 patients. **Methodology:** 35 patients with compound fracture (Type I to Type IIIA) of tibial diaphysis underwent supracutaneous plating of the tibia using LCP. Average age was 42 year. Patients were followed up for a period of 1 year. **Results:** Mean healing time was 18.42 weeks. Out of the 35 cases, 2 cases healed with delayed union, and no case was observed to have non union. At the final follow up all patients were fully weight bearing with infection free healed wounds. **Conclusion:** LCP as external fixator in the compound tibial diaphyseal fractures are very well tolerated by the patients and addresses the challenging problems of compound wound healing, non-union, and infection with a good union rate.

Keywords: compound fracture tibia, external fixation, locking compression plate

Date of Submission: 18-12-2018

Date of acceptance: 03-01-2019

I. Introduction

Open fracture of the tibial diaphysis is the most common lower extremity open fracture¹. The limited anteromedial soft tissue envelope makes open fractures more common than in other locations. Infection and non-union are more common with open tibia fractures and controversy exists regarding how, or if, definitive treatment algorithms should change in the face of an open fracture.²

Although closed and low grade open diaphyseal fractures are typically treated with internal fixation, with nails being used for diaphyseal fractures and plates or nails for periarticular fractures, controversy continues regarding the best treatment of the high grade injuries.³

Unilateral external fixators and Ring fixators are widely used to treat open tibial fractures. Ring fixators are used almost exclusively for Gustilo IIIB and IIIC fractures. Definitive treatment with ring fixators has shown a low incidences of infection and malunion rate. However definitive treatment of tibial diaphyseal fractures with unilateral external fixation has been plagued with relatively high rates of malunion.⁴

These external fixator frames used in fixation are bulky and cumbersome to the patient, causing inconvenience to them in day to day activities and also cause disturbance in movement of the extremity involved and gait, while trying to clear from the opposite limb. Locking compression plate as an external fixation device has been described in the management of open fractures, non-union, septic arthritis and even as an adjunct in distraction osteogenesis.^{5,6}

Locking compression plate as an external device not only stabilizes the fracture but also preserves the soft tissue envelope and vascularity of tibia and promotes union when it is done as an emergency procedure after thorough wound debridement. LCP as one-stage external fixation decreases both costs and surgical injuries. Fractures are anatomically reduced via a small incision without massive dissection. Locking compression plate external fixator can be concealed under the clothes making it more acceptable to patients. There is much less tendency to strike the contralateral leg in the swing through phase of either leg during ambulation⁷.

This study is undertaken to evaluate the results of locking compression plate used as an external fixator for the definitive management of open fracture of tibial diaphysis in 35 patients.

II. Materials And Methods

A prospective interventional study of thirty five cases of open diaphyseal fractures of tibia treated with a locking compression plate as external fixator for the definitive management. Patients fulfilling the inclusion and exclusion criteria during the study period from Sept 2015 to Sept 2017 admitted to RIMS Ortho deptt were included in the study. Patients were followed up monthly until 6 months and then 2 monthly till 1 year.

Inclusion criteria:

1. Both males and females between 18 to 70 yrs of age
2. Compound fractures Type I to Type IIIA according to Gustilo Anderson classification.
3. Diaphyseal fractures of tibia.

Exclusion criteria:

1. Patient medically unfit for surgery.
2. Patients having fractures with intraarticular extension.
3. Patients with comorbidities or associated fractures which may influence the outcome of the study.
4. Patients not consenting for the study.
5. Osteoporotic patients, pregnancy, Compartment syndrome and other such fracture associated diseases which may influence outcome

Operative procedure: After thorough debridement of the wound the plate was initially fixed to the proximal and distal fragment with a k-wire after ascertaining fracture reduction via a small incision with minimum tissue dissection. LCP was placed as close to the bone as possible, yet still allowing some space for swelling and regular wound care, to increase the mechanical stability of fixation. It was separated from the skin surface by a spacer of uniform thickness, like keeping a large needle holder. Bi-cortical locked screw fixation was preferred while using LCP as an external fixator. At least three 4.5 mm screws proximal and three screws distal to the fracture were ensured. The injured limb was immobilized with a below knee splint for soft tissue protection.

Postoperative care: Regular screw tract and compound wound dressings were done. Range of movement exercises and non- weight bearing walking was allowed from immediate post operative day. After 4 weeks, they were allowed toe-touch partial weight bearing for next 6 weeks, and followed by partial weight bearing for 4 weeks. According to the stability of fixation and healing of fracture, complete weight bearing was started

The patients' own functional assessments were recorded according to Lower Extremity Functional Scale (LEFS)⁸. The patients were asked 20 questions and their responses were recorded. The score out of 80 was then converted to out of 100 by multiplying with 100/80.

Table 1. LEFS questionnaire:

	Activities	Extreme Difficulty or Unable to Perform Activity	Quite a Bit of Difficulty	Moderate Difficulty	A Little Bit of Difficulty	No Difficulty
1	Any of your usual work, housework, or school activities.	0	1	2	3	4
2	Your usual hobbies, recreational or sporting activities.	0	1	2	3	4
3	Getting into or out of the bath.	0	1	2	3	4
4	Walking between rooms.	0	1	2	3	4
5	Putting on your shoes or socks.	0	1	2	3	4
6	Squatting.	0	1	2	3	4
7	Lifting an object, like a bag of groceries from the floor.	0	1	2	3	4
8	Performing light activities around your home.	0	1	2	3	4
9	Performing heavy activities around your home.	0	1	2	3	4
10	Getting into or out of a car.	0	1	2	3	4
11	Walking 2 blocks.	0	1	2	3	4
12	Walking a mile.	0	1	2	3	4
13	Going up or down 10 stairs (about 1 flight of stairs).	0	1	2	3	4
14	Standing for 1 hour.	0	1	2	3	4
15	Sitting for 1 hour.	0	1	2	3	4
16	Running on even ground.	0	1	2	3	4
17	Running on uneven ground.	0	1	2	3	4
18	Making sharp turns while running fast.	0	1	2	3	4
19	Hopping.	0	1	2	3	4
20	Rolling over in bed.	0	1	2	3	4
	Column Totals:					

Weekly follow up was undertaken till clinical union was evident with monthly X-rays to note the progress of healing. Whenever signs of clinical union were apparent, it was confirmed radiologically. The frame was removed at 3 months followed by application of patellar tendon bearing cast for 1 month. Thereafter the patient was followed up monthly until 6 months and then 2 monthly till 1 year.

Statistical analysis was done using SPSS software (version 21.0). Mean, standard deviation and the distribution of each variable was calculated.

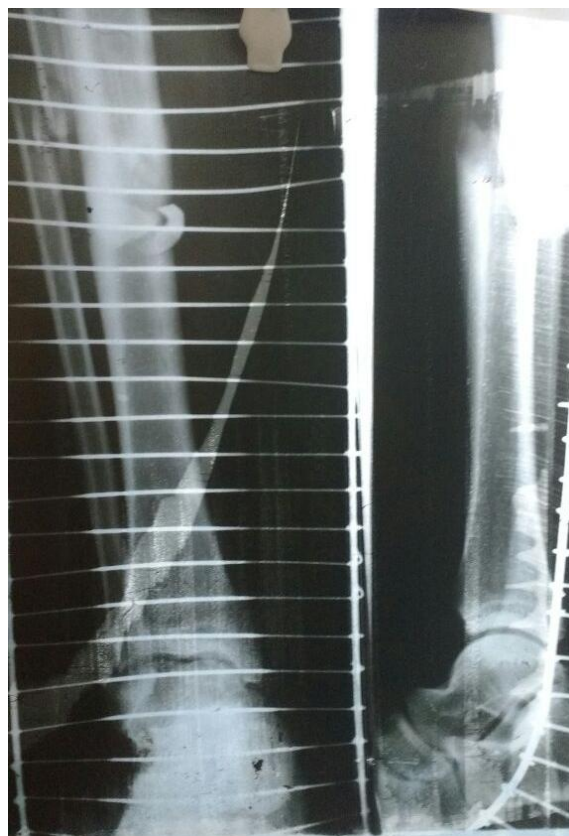

Fig 1: Preoperative X-ray of fracture shaft of tibia

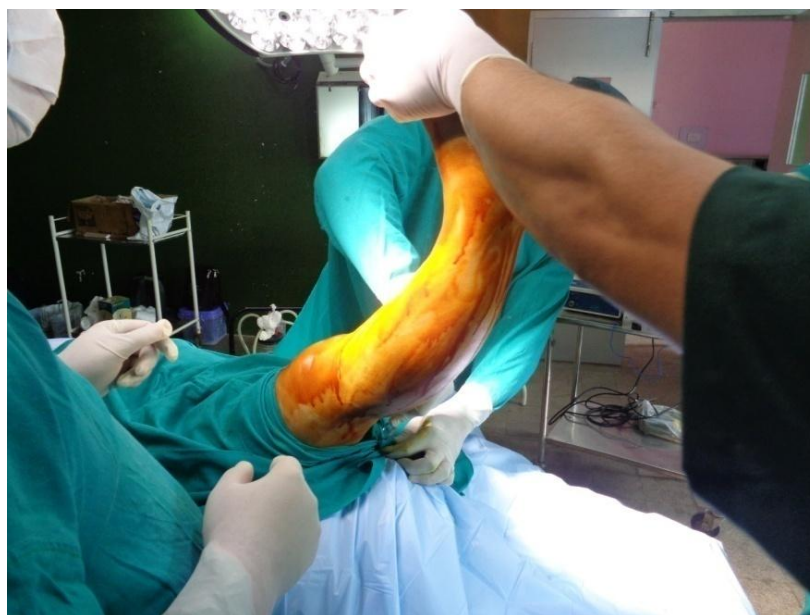

Fig 2: Painttinting before surgery

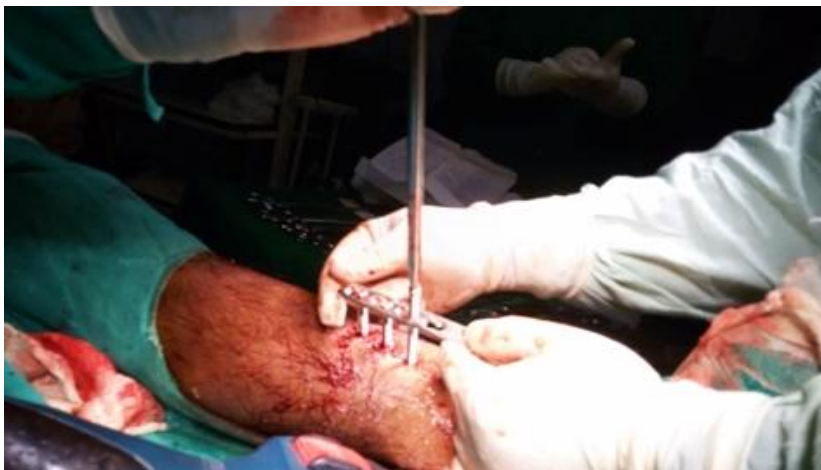

Fig 3: Introduction of screws through LCP after wound debridement and fracture reduction

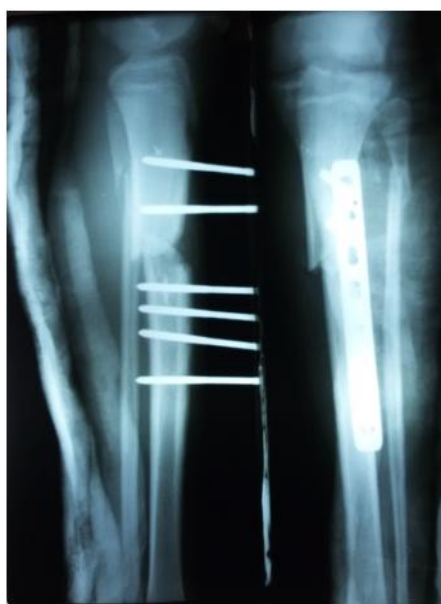

Fig 4: Post-op X-ray showing correction of length, alignment and rotation with rigid fixation.

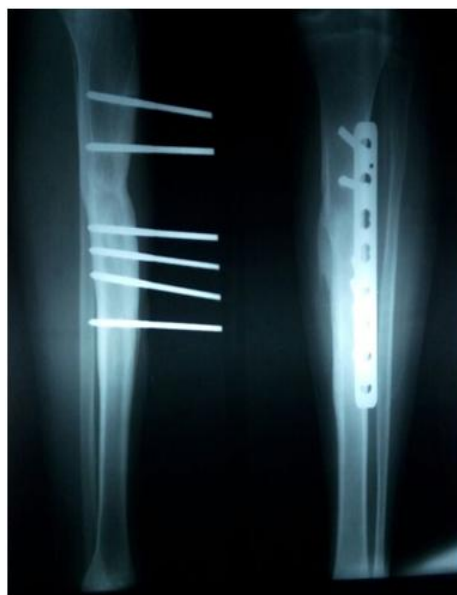

Fig 5: Radiological evidence of union with callus formation

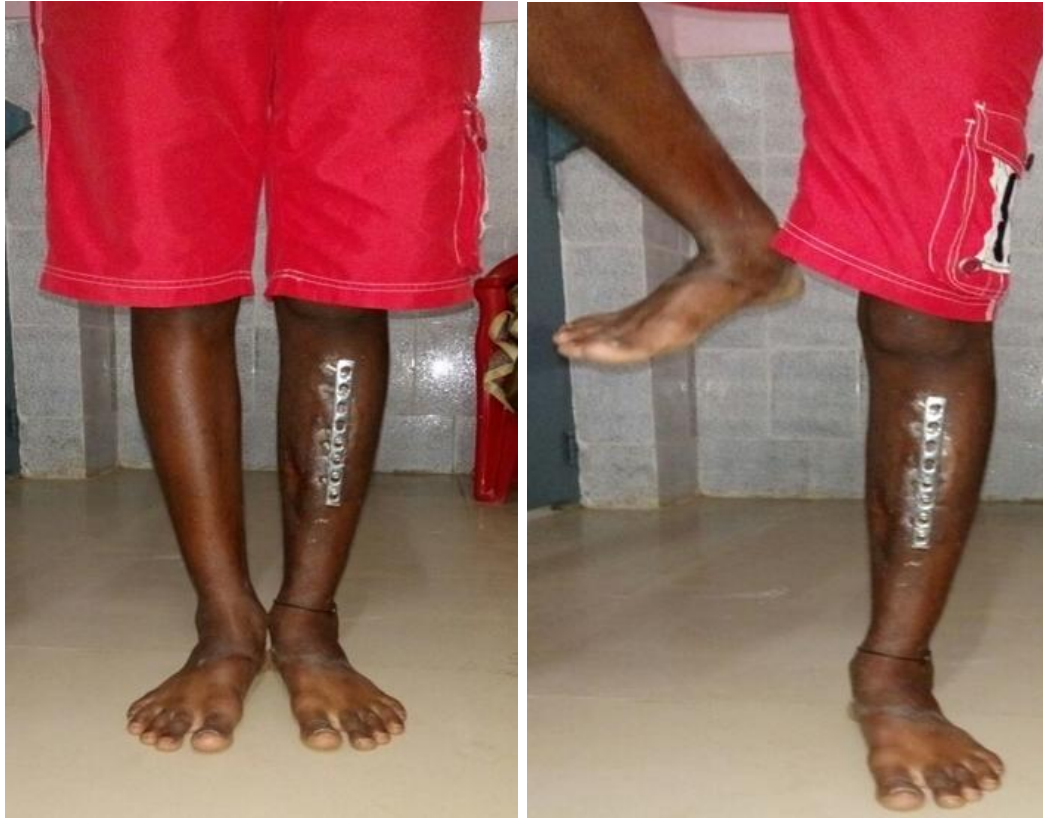

Fig 6: Unsupported full weight bearing at 12th week

III. Results

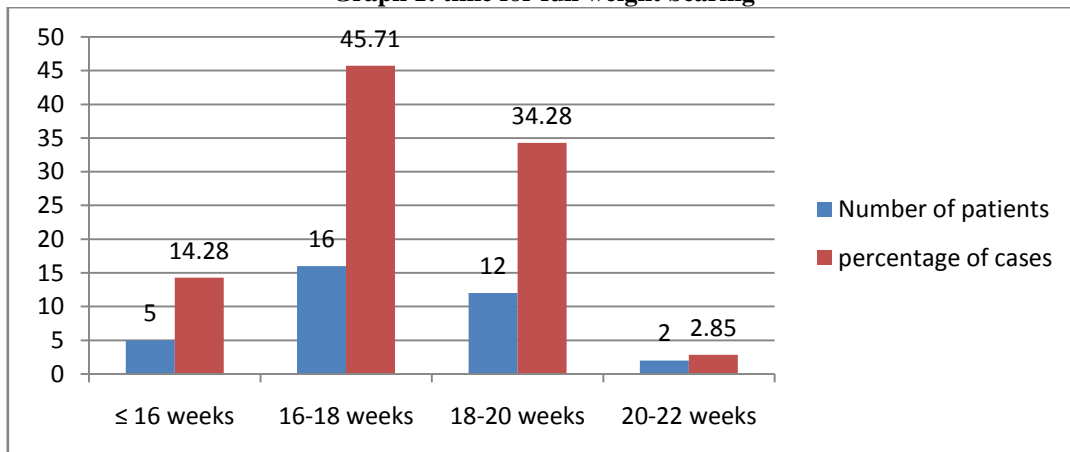
The average age was 42 years with a range of 18-70 years. There were 19 males and 16 females. Road traffic accident was the most common mode of injury. 16 cases were of Gustilo type I, 19 cases were type II and 10 cases were type IIIA. Spiral fractures were the most common pattern followed by oblique fractures.

Mean healing time was 18.42 weeks. Out of the 35 cases, 2 cases healed with delayed union, and no case was observed to have non union.

Lower Extremity functional scale: Of the 35 fractures in study, LEFS Score was greater than 95% in 34 cases.

Partial weight bearing was started with frame in place at first sign of radiological union in tibia. Unsupported full weight bearing was started in <16 weeks in 5 patients, between 16 and 18 weeks in 16 patients, between 18 weeks to 20 weeks in 12 patients and between 20 weeks and 22 weeks in 2 patients

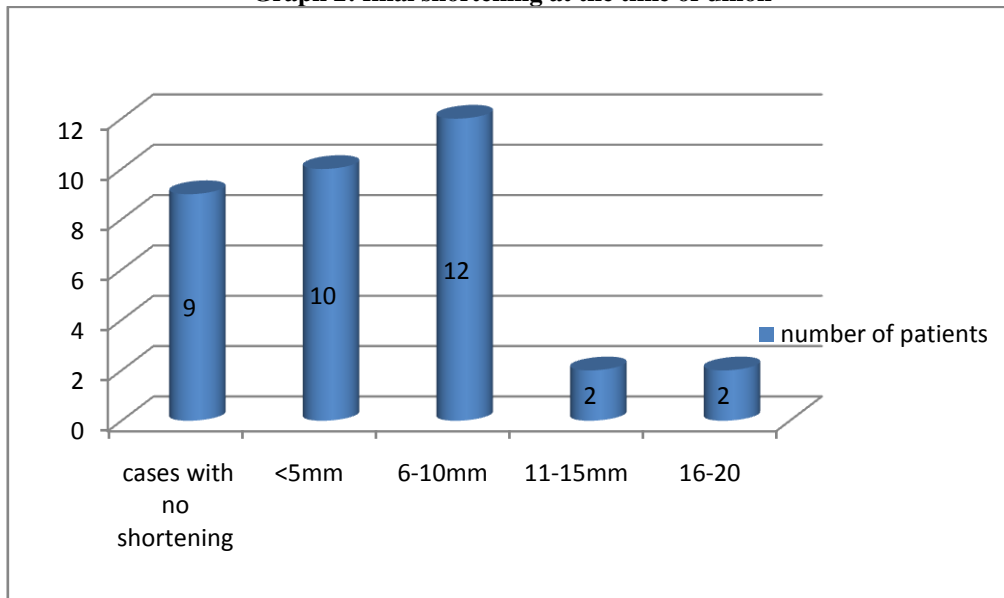
Graph 1: time for full weight bearing



Complications:

Final shortening of the limb: In the present study, 26 cases were observed to have shortening

Graph 2: final shortening at the time of union



Malalignment: In the present study, the most common angular deformity observed in the fractures at the time of complete union was varus angulation followed by posterior angulation, valgus angulation and anterior angulation respectively. i.e. varus(14)>posterior(12)>valgus(8)>anterior(7).

Restriction of ROM : Of the 35 patients at the time of complete union, 31(88.57%) patients had full range of motion at knee and ankle joints, 3 patients had mild restriction of movements and 1 patient had moderate restriction of movements. No patient was observed to have severe restriction of range of movement.

IV. Discussion

The prevalence of tibia non-unions increases with the severity of open fractures. The endosteal and periosteal blood supply is extensively destroyed when open fracture occurs which is a very important factor for fracture healing. So when LCP is planned for definitive management of open tibial fractures cases should be chosen cautiously considering the soft tissue status, location of fracture and vascularity of the tibia. In our study we have achieved a 100% union rate in 35 cases of Gustilo Type I, Type II and Type IIIA compound fractures of tibial diaphysis.

Theoretically LCP as external fixator is mechanically less stable construct than conventional unilateral and ring fixators, the stability of LCP as an external fixator was questioned by several studies⁹⁻¹¹. However, LCP as an external device is advantageous than other standard and circular external frames. Locking plate can be concealed under clothing making it more acceptable to patients. It is light weight, comfortable and convenient for patients to ambulate. Implant removal can be performed under local anaesthesia. It imparts a less conspicuous radiographic silhouette compared with traditional fixators allowing ease of assessment of healing of fracture to treating surgeons. Small amounts of axial micro motion may reduce stress shielding of the fracture site. Load sharing during weight bearing may stimulate the developing callus until bony union. Controlled dynamization by removing screws closest to the fracture site is possible, allowing some measure of control to the load sharing process. Multiple distal locking holes in the pre contoured plate provide more stability compared to the standard two large external fixator pins.

Unlike the traditional fixation, mono-axial nature of locking head screw trajectory reduces the ability to compensate for imperfect placement, making it mandatory that anatomical reduction should be achieved prior to placement of first screw. While traditional constructs can be strengthened by stacking connecting rods, it is not possible for LCP external fixation⁷. However LCP is comparatively costly as compared to traditional external fixators.

V. Conclusion

LCP as external fixator in the compound tibial diaphyseal fractures are well tolerated by patients and addresses the challenging problems of compound wound healing, non-union, and infection with a good union rate. Though the use of locked plates as external fixators in the definitive management of compound tibial diaphyseal fractures is not a generally acknowledged technique, and there is little experience with it in the literature but it has the advantage of less financial burden to rural population with good clinical outcome.

References

- [1]. Court Brown CM, Bugler KE, Clement ND, Duckwoth AD, McQueen MM. *The epidemiology of open fractures in adults. A 15 year review. Injury, 2012;43(6):891-97*
- [2]. Bhandari M, Guyatt GH, Swiontkowski MF, Schemitsch EH. *Treatment of open fractures of the shaft of tibia. J Bone Joint Br, 2001;83(1):62-68*
- [3]. Bhandari M, Guyatt GH, Swiontkowski MF, Schemitsch EH. Surgeon's preferences for the operative treatment of fractures of the tibial shaft. An international survey. *J Bone Joint surg Am, 2001;83-A(11):1746-52.*
- [4]. 4.Christina B, Robert VO. Tibia and fibula shaft fractures. In: Court Brown CM, Heckman JD, McQueen MM, Ricci WM, Tornetta P III, editors. *Rockwood and Green's fractures in adults, 8th ed* (Philadelphia: Wolters Kluwer; 2015) 2415-72.
- [5]. Kerkhoffs GMMJ, Kuipers MM, Marti RK, Werken C. External Fixation with Standard AO-Plates: Tech-nique, Indications, and Results in 31 Cases. *Journal of Orthopaedic Trauma, 2003; 17(1):61-4.*
- [6]. Appivatthakakul T, Sanapanich K. The Locking Compression Plate as an External Fixator for Bone Transport in the Treatment of a Large Distal Tibial Defect: A Case Report. *Injury, 2007;38(11):1318-25.*
- [7]. Kloen P. Supercutaneous Plating: Use of a Locking Compression Plate as an External Fixator. *Journal of Orthopaedic Trauma, 2009; 23(1):72-7.*
- [8]. Binkley JM, Stratford PW, Lott SA, Riddle DL. The Lower Extremity Functional Scale (LEFS): scale development, measurement properties, and clinical application. North American Orthopaedic Rehabilitation Research Network. *Phys Ther,1999 Apr;79(4):371-83.*
- [9]. Ahmad M, Nanda R, Bajwa AS, Candal-Couto J, Green S, Hui AC. Biomechanical testing of the locking compression plate: when does the distance between bone and implant significantly reduce construct stability? *Injury, 2007;38(3):358-64.*
- [10]. Zhang J, Ebraheim N, Li M, He X, Schwind J, Liu J, Zhu L. External fixation using locking plate in distal tibial fracture: a finite element analysis. *Eur J Orthop Surg Traumatol. 2015;25(6):1099-104.*
- [11]. Kanchanomai C, Phiphobmongkol V. Biomechanical evaluation of fractured tibia externally fixed with an LCP. *J Appl Biomech, 2012;28(5):587-92.*

Dr. Shrinivas Prabhu. "A study of Locking compression plate as external fixator in the definitive management of open diaphyseal fractures of tibia in adults." IOSR Journal of Dental and Medical Sciences (IOSR-JDMS), vol. 18, no. 1, 2019, pp 07-13.