

Lingual Orthodontic Bracket Design Modification and Their Development-A Review

Dr.Appasaheb S Naragond, Dr.Smitha A Naragond

Asso.Proff,Dept Of Dentistry G M C H Miraj, Maharastra India

Shri Mallikarjun Dental Hospital Miraj, Maharastra India

Corresponding Author: Dr.Appasaheb S Naragond

Abstract; Lingual orthodontics is more difficult and complex than labial orthodontics for several reasons, such as difficulties in bracket positioning, patient comfort, maintenance of oral hygiene, with increasing in the demand of orthodontic treatment in adults patients there is a demand of such brackets they should not be visible during the course of treatment. Clinically improved laboratory techniques have overcome many of the difficulties that a previous generation of orthodontists encountered when first trying to embrace this innovative technique to correct malocclusions. This article provides a brief history of lingual orthodontics. It will discuss the development of the technique

Key word – lingual orthodontics ,lingual braces

Date of Submission: 26-12-2018

Date of acceptance: 11-01-2019

I. Introduction

“Necessity Is the Mother of Invention” Says the proverb. So was the invention of the lingual orthodontic technique by Dr.Craven Kurz. Dr.Kurz, whose clientele was dominated by public figures, felt the need for an orthodontic system which would not expense the brackets **Development:**

With the help of his colleague Dr.Jim Mulick, Dr.Kurz developed the true lingual appliance. The appliance had plastic Lee Fischer brackets bonded to the lingual aspect of the anterior dentition and metal brackets to the lingual aspect of the posterior dentition. The plastic anterior brackets were selected due to the ease of recontouring and reshaping them to avoid direct contact with the opposing teeth.

Two initial hurdles encountered by them were

1. High bond failure rate.
2. Brackets being uncomfortable and irritating to the patient’s tongue.

Very soon, research and development into the lingual orthodontic technique was taken over by ORMCO, a company in California, which formed a team consisting of Mr. Frank Miller, Mr. Craig Andreiko and Dr.Kurz.

The team started analyzing the reason for bond failure. It was found out by the team that it was due to the shear forces acting on the maxillary anterior brackets. The solution for all the problems regarding bond failure was the incorporation of an anterior inclined plane. It converted the shear forces to compressive forces applied in an intrusive and labial direction.

The original lingual task of force was developed to provide beta test sites for the appliance.

The task force included in addition to Dr. Kurz

1. Dr. Jack Gormen
2. Dr. Bob Smith
3. Dr. Richard Alexander
4. Dr. Moody Alexander
5. Dr. James Hilgers
6. Dr. Bob Scholz

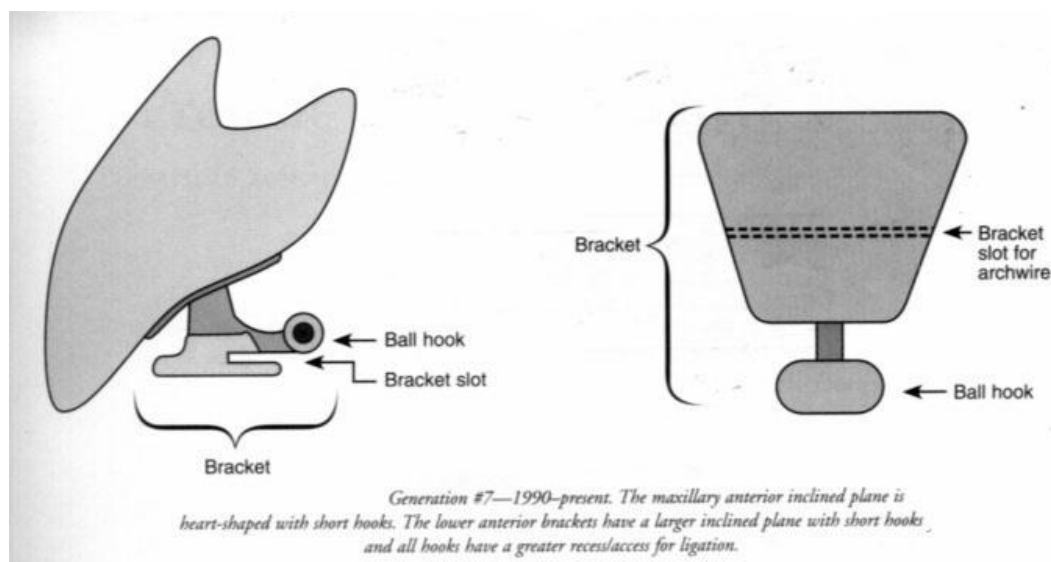
In 1982-83, ORMCO organised a task force of two doctors from every country in Europe. By 1983, the lingual orthodontic technique was introduced to Europe. There was high demand in the dental community to provide the appliance for wide scale use. Hence, the task conducted regular seminars on lingual appliance in Newport Beach, California.

The lingual task force was developed with the aim of

1. Helping refine bracket design (*dimensions, torques, angulations, thickness, etc*)
2. Developing mechanotherapy techniques.

3. Creating arch wire design
4. Discussing treatment sequences and
5. Determining case selection criteria.

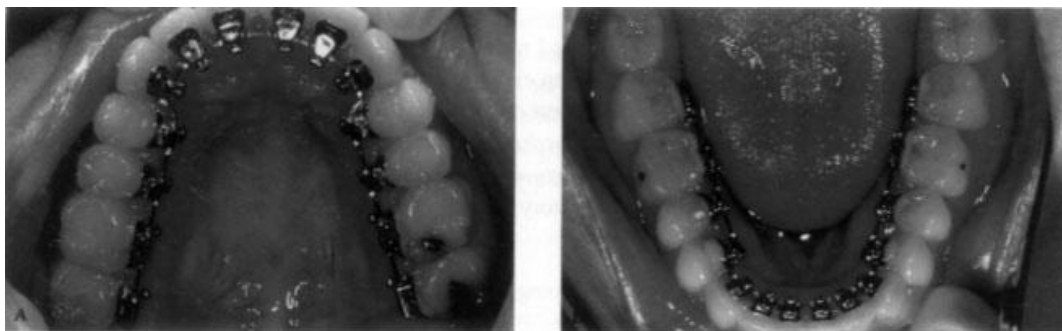
Differences in bracket design: Bracket bonding to the lingual surface of the teeth requires special attention because lingual morphology differs and varies widely from the labial morphology and also lingual morphology of every tooth differs. So, before going into the process of bonding brackets to the lingual surface, extensive study of the lingual morphology should be done by using topographical maps of the lingual surface of the tooth. The brackets are made of hardened stainless steel. The brackets for all the teeth are of the same design. They differ only in the width which varies with individual tooth. The brackets are brazed to a diffusion bonded foil / mesh base. The bonding base is contour to conform to the lingual morphology of each individual tooth. If the brackets are still not contoured well to the lingual surface, additional adaptation can be done in the laboratory on a custom made tooth to tooth bases at the time of indirect bonding set up. Brackets have on 0.018" each wire slot which parallels the occlusal plane. Brackets are provided with varying design of torque, angulations and bracket thickness, which were determined after an extensive study of lingual morphology. Maxillary anterior brackets incorporate bite plane designed into the incisal edge of the bracket the bite plane in parallel to the arch wire and the occlusal plane.



A gingival ball hook was incorporated in to all the brackets. This design helped in

1. Elastic ligature placement
2. Rotation control
3. Placement of intra and intermaxillary elastics

Bonding brackets to the lingual surface in not feasible for all the teeth, especially those with short clinical crowns. An example for this are the mandibular bicuspid. Since this area of the dentition is not visible for most patients, banding rather than bonding can be attempted. After trying, testing and discarding various brackets designs, including the Siamese twin brackets design, it was concluded that the straight wire bracket design was good enough and conformed better to the lingual anatomy.



A AND B. During treatment: upper and lower occlusal view of lingual appliance.

Initially, lingual anatomy of every tooth was analysed and studied through the use of topographic maps. These topographic contour maps were made from models of several finished orthodontic cases with the exception of short clinical crowns, lingual morphology hardly presented a problem in establishing a straight wire plane in both maxillary and mandibular arches. These planes were found to be parallel to the occlusal plane.

After having decided on the bracket design, the next task was to convert the desired bracket design to configurations that would fit within the projected arch wire plane and determining necessary bracket torque, thickness and angulations. To solve this they related the lingual determinants to the labial tooth anatomy. Through this a data base was established so that by simple mathematical computations a lingual appliance for any selection of torque values relative to the established labial appliances could be produced.

A bracket with a slot size of 0.018" was selected with two criteria in mind.

1. It would conserve incisal – gingival bracket dimension
2. It would be compatible with existing arch wires.

Brackets were made of hardened stainless steel alloy. Even with all these precautions, occlusion in the maximally incisor brackets was inevitable. It was later decided to incorporate a bite plane in the incisal wing of the maxillary incisor bracket.

The bite plane served 2 purposes.

1. It assisted in opening the bite.
2. It redirected the forces of occlusion to prevent shearing of the bond

Modifications in the brackets:

In 1979-80, certain modifications were introduced in the bracket design they were:

1. In the maxillary cuspids, bite plane was modified from a flat plane to a bibeveled plane in order to minimize bracket – cuspid interference in the final class 1 cuspid relationship.
2. Bracket torque was increased.
3. Ball hooks were added to all the lingual brackets
4. Cross over or buccolingual mechanics was a modification with buccal mechanics in the posterior segments.

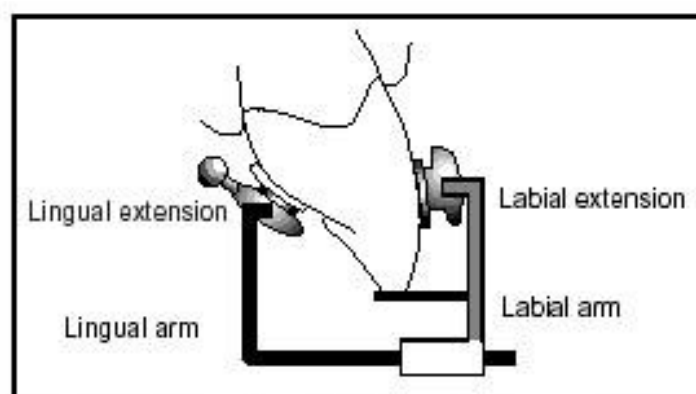
The Lingual Bracket Jig (LBJ)

JCO, 1999 August, Dr. Silvia Geron, 457 – 463.

Precise placement of the lingual brackets is important because when using the lingual technique an orthodontist is faced with the following problems:

1. Difficulty in direct viewing and access, especially in cases of Retroclined anterior teeth.
2. Variation in lingual surface morphology
3. Wide range of labiolingual thickness of the teeth.
4. Critical relationship between the vertical height of lingual brackets and the labial surface torque.

The author describes a new lingual bracket jig. Lingual morphology permit the establishment of a straight wire lingual plane in both arches. The plane selected was the Andrews labial arch wire plane. The jig simply transfers the Andrews straight wire appliance labial bracket prescription to the lingual surface.



The jig has a labial and a lingual arm. The lingual arm holds the lingual bracket and slides into the labial arm. When the lingual bracket is mounted on the LBJ, the lingual bracket slot is parallel to the labial slot. There is an additional spring mechanism to eliminate play between the lingual extension and the lingual bracket slot. An occlusal stopper is used to position the height of bracket placement. At zero position, the stopper allows 1mm between the incisal edges of the anterior teeth and bite planes of the anterior brackets.

Newer bracket designs:

Lingual Orthodontics – Its Renaissance
JCO 1989, Creekmore, 120 – 137.

In this article, the author has described a newer bracket design with occlusal slots instead of lingual. There is also modification in the design of the molar tube. The first 1mm of molar tube opens to the occlusal aspect, providing direct guidance for the insertion of arch wire occlusal to the arch wire plane.

Problems with lingually opening slots:

The author also sums up the disadvantages faced during the use of brackets with lingually opening slots. They are

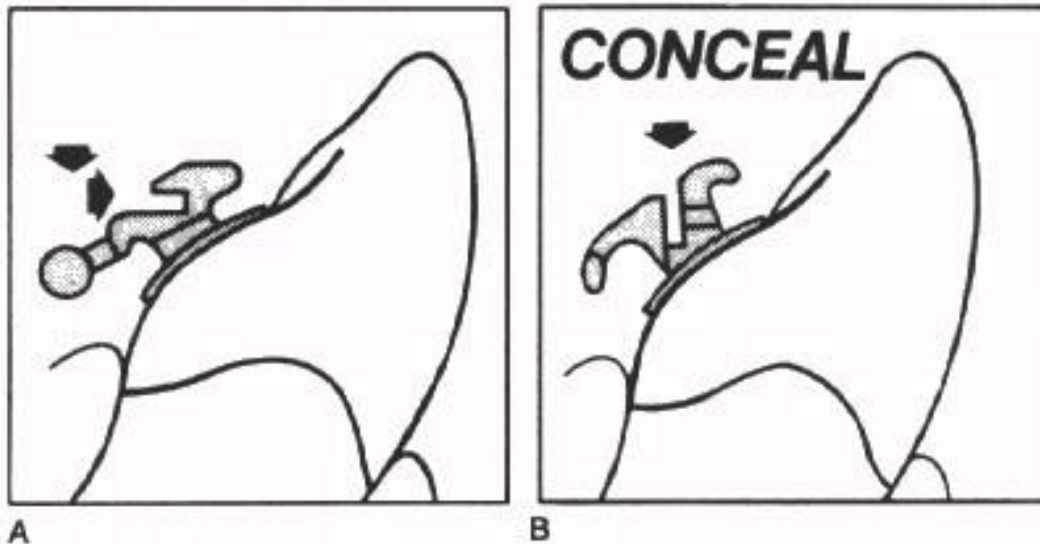
1. It requires the insertion of the arch wire distally beyond anterior brackets.
2. There is a need for the constriction of the arch wire lingually to engage slots.
3. The arch wire has to be brought mesially to fully engage anterior brackets, hence stiffer arch wires are difficult to insert.
4. The arch wire pulls out of slot in space closing mechanics.

Occlusal design was not fault proof. There was a hurdle in designing premolar / molar brackets that would provide effective ligation. To solve this, the design of the occlusal tie wings was changed so that they would face mesially and distally instead of labiolingually.

II. Conceal Brackets- Centered Slot Concept

Unitwin Bracket

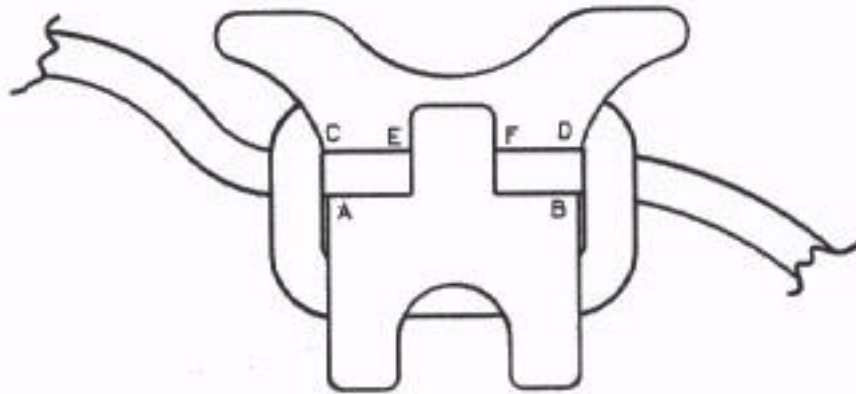
These are single bracket without tie wings is the center of a 0.045” twin bracket.



There different slot widths were given, they were

- A-B for tip (0.100” width)
- E-F for torque (0.035” width)
- C-F and E-D for rotation (0.070”width)

The slot dimensions were
0.016” horizontally
0.022” vertically



Anterior brackets were designed with 'y' configuration with single tire wing gingivally and twin tie wings occlusally.

Update on The Fujita Lingual Brackets
JCO 1999 March, by Ryoan Ki Hong, Hee Wook Sohn.

Bracket design:

Though the Fujita lingual brackets are still based on occlusal slot opening, the authors have introduced additional slots in the brackets. The anterior and premolar brackets have three slots: occlusal, lingual and vertical. Molar brackets have five slots: one occlusal, two lingual and two vertical.

Occlusal slots:

The slot dimensions are 0.019" x 0.019". This main occlusal slots has the advantages of easier arch wire insertion seating and removal than with linguallly opening slots. The arch wire does out pull out during space closure. Rotation control is more efficient with the occlusal slot, since it requires only the insertion of the light arch wire which produces an action analogous to tipping with a labial edgewise appliance.

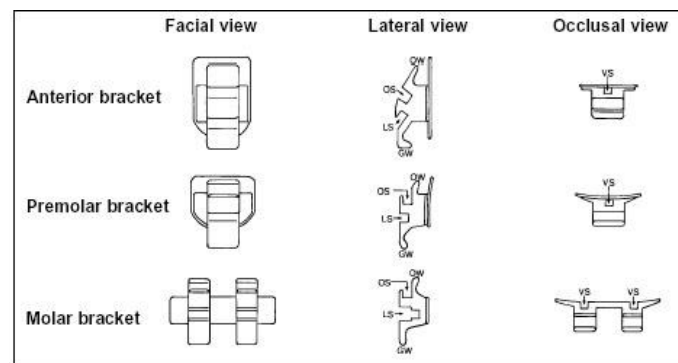
Lingual slot:

The dimensions are 0.018" x 0.018". This is reserved for sliding mechanics like partial canine retraction and insertion of various Tandem arch wire system.

The molar bracket has two slot dimensions. The outer dimension being 0.028" x 0.022" and the inner being 0.018" x 0.018".

The outer slot helps in

1. Engaging transpalatal arch to detain an expanded maxillary arch
2. Inhibiting extrusion of maxillary first molar during leveling in dolichofacial patients.

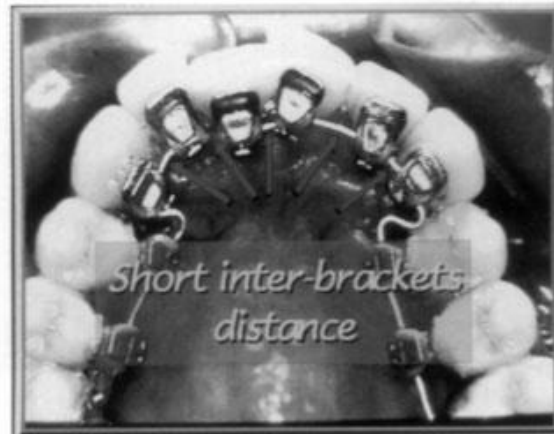

Vertical slots:

The slot dimensions are 0.016" x 0.016", used in engaging auxiliary up writing springs or elastic hooks. Insertion of up righting springs in critical slots provide better tip control. The multiple slots of the Fujita lingual bracket allow positive tip and rotation control for a wide variety of mechanics, despite reduced brackets width.

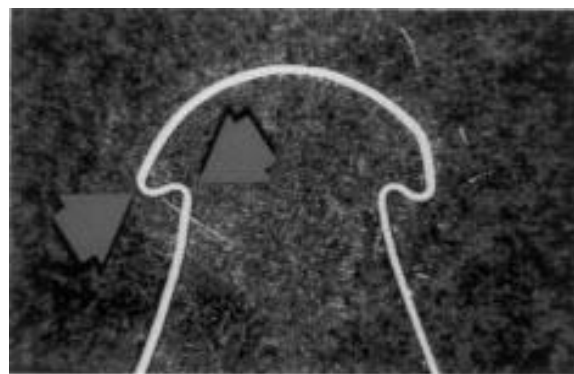
Arch wires:

Resilient arch wires have been the mainstay of treatment in lingual orthodontics. This is because, arch radius and thereby inter bracket distance is greatly reduced, especially in the lingual anterior region. Resilient wires are better to offset such reduction so that there can be full expression of rotational and torque control.



Short interbracket distances with lingual appliance.

Arch wires used in lingual treatment are mushroom shaped arch wires. This is due to the fact that there is a large constriction in arch width that occurs as one proceeds distally from the lingual surface of the canine to the bicuspid. The compensatory first order bends are placed interproximally at cuspid – bicuspid and bicuspid – molar locations.



Mushroom shape of an archwire in shape memory alloys.

In case of short clinical crowns or when there is a problem with incisal clearance, a second order bend or step – down, may also be needed between cuspids and bicuspid.

Wire sequencing:

Regardless of all nature of malocclusion

Class I, Class II, Class III extraction or non – extraction cases it would be prudent to follow a protocol to

1. Maximize the potential of each wire
2. Reduce arch wire changes to minimum
3. Provide high quality results

Each wire used will perform a specific task in the treatment.

First initial wire 0.016” Ni Ti

Second Initial Wire : 0.019” special plus wilcocks heat treated stainless steel.

Intermediate Wire : 0.017” x 0.025” TMA

Finishing Wire : 0.017” x 0.025” (or) 0.016” x 0.022” S.S.

Detailing Wires : Wilcocks 0.016 or 0.018 special plus.

Initial Wires

Initial wires are the most important in the sequence and time consuming to apply.

Intended goal advancements at this level are.

1. Initial leveling
2. Alignment
3. Derotation
4. Tip control.

A second initial wire is required when crowding is severe to ensure full bracket slot engagement. For this, wilcock special plus wire (0.016") is employed with advancement loops or stops mesial to the first molar. For anterior bite opening, the use of wilcock 0.019" special plus wire with an additional reverse curve of spee provide good results. For correction of moderate rotation in anterior segment, steel double over – tie is performed over a NiTi wire.

Intermediate Wires:

Intermediate wires used are 0.017" x 0.025" wires made of TMA. In non extraction cases, in some instances they can be used as finishing wires.

In extraction cases, the archform is modified to give the offset just distal to the canine bracket to allow space closure.

The buccolingual compensatory curve is reduced in the intermediate wire since it is relatively stiffer than the initial wires. TMA wires are not suitable for prolonged or heavy elastic forces, but light forces can be applied to initiate A – P control.

If class II elastics are required, as extra buccal compensatory bend should be made to negate the rotational effect of the elastic forces on the lower second molars.

The anterior segment must be "figure – eighted" to prevent space opening during the use of elastic force when using rectangular wire, steel ligation can be used. This accomplishes the following.

1. To ensure full bracket slot engagement.
2. Full expansion of appliance prescription
3. Prevent re – rotation of lateral incisors and canines.

Finishing and detailing wires.

Treatment is usually complete using 0.017" x 0.025" in upper arch and 0.016" x 0.022" in lower arch stainless steel wires. The wires are reversed in class III cases.

The use of 0.018" x 0.025" stainless steel wires are employed when.

1. Maxillary anterior torque control in difficult to achieve.
2. Lengthy class II elastics are to be employed

The changes in the arch form when compared to intermediate wires are subtle. They are

1. Mild adjustments to the canine or molar offsets.
2. Corresponding bends to facilitate completion of space and interarch adjustment.

During fine detailing of occlusion more flexible wires like 0.016" or 0.018" special plus (Wilcock's) are used

Advantages of lingual therapy

1. The brackets are bonded to the lingual surface, which proves as a main esthetic advantage over labial technique.
2. The labial enamel surface is served from chemical insults of etching and bonding procedures. These procedures can result in permanent unsightly decalcification
3. Oral hygiene is better performed with the tongue playing a major self – cleansing act.
4. Clinical judgement of treatment program can be enhanced as the labial surface of the teeth is free to accurately follow the tooth movement accomplished.
5. Soft time response of the lips and cheeks to treatment can also be accurately judged.
6. There is an inherent bite opening effect in the technique which is the first movement accomplished.
7. There is an inherent arch expansion (maxillary) due to the reduced interbracket span.
8. While achieving distalization of molars, we get a bodily movement rather than the tipping seen in labial appliance.
9. Anterior segment retraction is performed with ease because the tongue is in a more posterior position and does not exert pressure on the anterior teeth.
10. The use of indirect bonding technique paves way for accurate bracket placement.

III. Conclusion

"Go on Smiling" For Lingual orthodontics aims at just that. Apart from the esthetic face left a contribution in arena of orthodontics, it also renders mechanical advantages such as inherent expansion, bite opening extra with these appliances the practitioner can achieve excellent results while providing his or her

patients with a unique and valuable service. The only criteria for achieving successful results on the part of the operator is to develop the necessary skills let us hope in future the lingual orthodontics will culminate to “invisible orthodontics” in the real sense.

References

- [1]. Hohoff A, et al. Comparison of the effect on oral discomfort of two positioning techniques with lingual brackets. *The Angle Orthodontist*. 2004;74:226-233.
- [2]. Geron S. Class II non-extraction treatment with self ligating lingual brackets. *Adult ling orthod*. 2005;3.
- [3]. Geron S. Self-ligating brackets in lingual orthodontics. *Semin Orthod*. 2008;14:64-72.
- [4]. Wiechmann D, et al. Prediction of oral discomfort and dysfunction in lingual orthodontics: A preliminary report. *Am J Orthod Dentofac*. 2008;133:359-364.
- [5]. Fillion D. Lingual straight wire treatment with the Orapix system. *J Clin Orthod*. 2011;45:488-497.
- [6]. Grauer D and Proffit WR. Accuracy in tooth positioning with a fully customized lingual orthodontic appliance. *Am J Orthod Dentofacial Orthop*. 2011;140:433-443.
- [7]. Schulhof A. Lingual for everyone. *Orthod Prod*. 2014.
- [8]. Buckley J. Lingual orthodontics: an illustrated review with the incognito fully customized appliance. *J Ir Dent Assoc*. 2012;58:149-155.
- [9]. Alexander, M., Alexander, R.G., Gorman, J.C. et al, Lingual orthodontics: a status report: part 5: lingual mechanotherapy. *J Clin Orthod*. 1983;17:99-115.
- [10]. Harradine, N.W.T. Self-ligating brackets: where are we now?. *J Orthod*. 2003;30:262-273.
- [11]. Shivapuja, P.K., Berger, J. A comparative study of conventional ligation and self-ligation bracket systems. *Am J Orthod Dentofacial Orthop*. 1994;106:472-480.
- [12]. Berger, J.L. The influence of the SPEED bracket's self-ligating design on force levels in tooth movement: a comparative in vitro study. *Am J Orthod Dentofacial Orthop*. 1990;97:219-228.
- [13]. Pizzoni, L., Ravnholt, G., Melsen, B. Frictional forces related to self-ligating brackets. *Eur J Orthod*. 1998;20:283-291
- [14]. Hain, B., Dhopatkar, A., Rock, P. The effect of ligation method on friction in sliding mechanics. *Am J Orthod Dentofacial Orthop*. 2003;123:416-422.
- [15]. Park, J.-H., Lee, Y.-K., Lim, B.-S. et al, Frictional forces between lingual brackets and archwires measured by a friction tester. *Angle Orthod*. 2004;74:816-824.
- [16]. Maijer, R., Smith, D.C. Time saving with self-ligating brackets. *J Clin Orthod*. 1990;24:29-31.
- [17]. Shivapuja, P.K., Berger, J. A comparative study of conventional ligation and self-ligation bracket systems. *Am J Orthod Dentofacial Orthop*. 1994;106:472-480.
- [18]. Harradine, N.W.T. Self-ligating brackets and treatment efficiency. *Clin Orthod Res*. 2001;4:220-227.
- [19]. Eberting, J.J., Straja, S.R., Tuncay, O.C. Treatment time, outcome and patient satisfaction comparisons of Damon and conventional brackets. *Clin Orthod Res*. 2001;4:228-234.
- [20]. Neumann, G., Holtgrave, E. Self-ligating brackets in lingual orthodontics. *J Ling Orthod*. 1999;1:19.
- [21]. Macchi, A., Tagliabue, A., Levrini, L. et al, Philippe self-ligating lingual brackets. *J Clin Orthod*. 2002;36:42-45.
- [22]. Scuzzo, G., Cirulli, N., Macchi, A. A simple lingual bracket (2D control) for minor crowding and periodontal problems. *J Ling Orthod*. 2000;1:1-4.
- [23]. Takemoto, K., Scuzzo, G. Implementing the HIRO technique for lingual indirect bonding. *Clin Impress*. 2003;12:7-13.
- [24]. Sattler, N., Hahn, W. Self-ligating brackets versus conventional brackets. *J Ling Orthod*. 2002;2:67-70.
- [25]. Fillion, D. The resurgence of lingual orthodontics. *Clin Impress*. 1998;7:2-9.
- [26]. Hug, S.A. The customized lingual appliance set-up service (CLASS) system. in: R. Romano (Ed.) *Lingual Orthodontics*. BC Decker, Hamilton, Ontario; 1998:163-173.
- [27]. Geron, S. The lingual bracket jig. *J Clin Orthod*. 1999;33:457-463.

Dr.Appasaheb S Naragond. “Lingual Orthodontic Bracket Design Modification and Their Development-A Review . “IOSR Journal of Dental and Medical Sciences (IOSR-JDMS), vol. 18, no. 1, 2019, pp 34-41.