

Analysis of Efficacy of Adjunctive Mitomycin-C in External Dacryocystorhinostomy (DCR) in Chronic Dacryocystitis: A Prospective, Double-Masked Study

Dr. Manoj Govila¹, Dr. Jitendra Kumar², Dr. Puneet Kumar Jaisal³

¹ Professor, Deptt. of ophthalmology, MLB Medical College Jhansi, India.

² Assistant Professor & HOD of ophthalmology, MLB Medical College Jhansi, India

³ Junior resident, Deptt. of ophthalmology, MLB Medical College Jhansi, India

*Corresponding Author : Dr. Puneet Kumar Jaisal

Abstract:

Objective: The aims of this study were to assess the efficacy of intraoperative adjunctive mitomycin C (MMC) treatment in external DCR surgery and to compare this procedure with the standard DCR procedure alone.

Materials and Methods: There were 60 patients in this study who were divided into 2 groups. In group A, MMC was used intraoperatively at the osteotomy site for a period of thirty minutes. In Group B, Conventional External DCR was done without using an adjuvant. The study population included patients with acquired nasolacrimal duct obstruction. After the surgery, patients were assessed at 1st week, 1st, 3rd and 6th month respectively.

Results: The mean age of the study group was 43.88±10.51 years. Patients in both the groups were followed up regularly. Postoperatively at 6th month of visit, it was found that 2 (6.7%) out of 30 patients in Group A (MMC) and 6 patients (20%) among 30 in Group B (Conventional) reported with symptoms of watering of eyes and on examination had a high tear meniscus height, thereby had a non-patent lacrimal drainage system following surgery. On comparison there was a statistically significant difference between the two groups with the P value of 0.001. It was revealed that success rate was better in MMC group when compared with the Conventional group.

Conclusion: External dacryocystorhinostomy with intraoperative mitomycin-C is more efficacious in achieving lacrimalsystem patency than external dacryocystorhinostomy without mitomycin-C.

Keywords: External dacryocystorhinostomy. Intraoperative mitomycin-C. Lacrimal drainage system patency. Nasolacrimal duct obstruction

Date of Submission: 04-10-2019

Date of Acceptance: 21-10-2019

I. Introduction

Dacryocystitis is the infection of lacrimal sac most often as a result of obstruction of nasolacrimal duct[1]. This disease may be acute or chronic. Watering from the eye is the presenting complaint of chronic dacryocystitis[2]. A swelling at the inner canthus, that is usually painless, is often the presenting sign in chronic dacryocystitis[3]. Sometimes swelling may not be obvious but pressure over the lacrimal sac can result in regurgitation of mucopurulent discharge through the canaliculi[1]. For the management of epiphora, as a result of nasolacrimal duct obstruction, external dacryocystorhinostomy (DCR) is the most popular procedure[2,4]. In this procedure, a surgical anastomosis is done between the lacrimal sac to the nasal mucosa of middle meatus by creating an opening in the intervening bone[5]. Success rate of dacryocystorhinostomy varies from 88% to 95% (by external approach) and upto 87% by nasal approach. However, both surgical routes have reported failure rates ranging from 0% to 18%, due to blockage of osteotomy due to granulation tissue, scarring and formation of adhesions and synechiae in the nasal cavity[3,4,5,6]. During the postoperative healing process, scarring can further decrease the ostium size.[5] Therefore, the key to increasing the longevity of the success of a DCR, obviously lies in maintaining the patency of the ostium. The use of anti-metabolites, which inhibits circumosteal fibrous tissue growth and scarring is hence desirable. Various causes of failure of surgery include undiagnosed canalicular obstruction, improperly made lacrimal or nasal mucosal flaps, small osteotomy, undiagnosed nasal pathology, excessive fibrosis and granulation tissue formation invoke nasal and lacrimal mucosa, membranous closure at ostium, canalicular obstruction, infection and clot formation. Introduction of antifibrotics like Mitomycin-C (MMC) has reformed ophthalmology surgeries including dacryocystorhinostomy, pterygium and glaucoma procedures. Mitomycin-C is an antineoplastic and antiproliferative agent [systemic chemotherapeutic agent] derived from soil bacterium *Streptomyces caespitosus* that inhibits the synthesis of DNA, cellular RNA,

and protein by inhibiting the synthesis of collagen by fibroblasts.[8,9] Mitomycin C (MMC), an alkalinizing antibiotic, acts by inhibiting DNA-dependent RNA synthesis and represents an alternative approach to prevent the development of fibrous tissue formation over the osteotomy site and the anastomosed flaps. MMC has been reported to inhibit excessive fibrous tissue formation subsequent to trabeculectomy for glaucoma[11]. MMC may increase the surgical success rate of DCR by preventing both a decrease in ostium size and canalicular obstruction[4,5,12]. Due to the potential for adverse effects (AEs), MMC is typically administered for brief durations (2-10 minutes) at doses of 0.2 to 0.4 mg/mL. It has been reported that 0.2 mg/mL MMC administered to an osteotomy site for 30 minutes might be favorable to increase success rates with no significant increase in AEs.

II. Material & Method

This experimental study was conducted for a period of 18 months from August 2017 to March 2019 in the Department of Ophthalmology, Maha Rani Laxmi Bai Medical College, Jhansi. Study was approved by the Ethical and Research Board of the Medical College. Sixty patients were selected from the outpatient department (OPD) of ophthalmology, who had undergone external approach DCR for chronic dacryocystitis and had come to OPD for follow-up after 6 months of surgery. Informed consent was taken. All the surgeries were performed by same surgeon. Tenets of the declaration of Helsinki were followed. Study protocol was approved by the institutional ethics committee.

Patients were randomized into 2 groups, Group (Mitomycin group) and Group B (EXT-DCR without MMC)

Inclusion Criteria :

Inclusion criteria were adult patients between 20 and 60 years of age with chronic dacryocystitis of either gender.

Exclusion Criteria:

1. Patients with additional pathologies like middle turbinate hypertrophy, deviated nasal septum, nasal polyps, atrophic rhinitis and previous failed DCR were not included in the study.
2. Aged < 18 or >70 years, previous nasolacrimal duct surgery, morphologic or functional palpebral disorders, and secondary causes of nasolacrimal duct obstruction.
3. Patients with less than 6 months of follow-up after surgery were excluded out of study

All patients underwent a comprehensive examination which included slit lamp evaluation for a detailed assessment of ocular adnexa and external ocular surface & lacrimal sac syringing was done and the outflow was assessed. A standard nasal examination was performed to rule out pathologies (septal deviation, middle turbinate hypertrophy, nasal polyps) that would affect the surgery. In both groups, the standard DCR procedure under local anesthesia (3 ml of 2% xylocaine with epinephrine and 2 ml of 0.5% bupivacaine) was followed. A curved incision, confirming with the anterior lacrimal crest was given with 15 no. BP blade. By proper blunt dissection medial palpebral ligament (MPL) and anterior lacrimal crest (ALC) were exposed. MPL was divided and periosteum over ALC was incised. Periosteum and sac were reflected laterally to exposed lacrimal fossa. An osteotomy of approximately 15 mm in diameter was created. Anterior and posterior flaps of nasal and lacrimal mucosa were made. Respective flaps were sutured with 6-0 chromic catgut suture. In group A, a sponge soaked in 1 ml of 0.2 mg/ml of Mitomycin-C was placed at osteotomy site before suturing of flaps. After 5 minutes, sponge was removed and osteotomy site was washed with plenty of normal saline. Orbicularis muscle was also sutured with the help of 6-0 chromic catgut suture. The skin incision was closed with interrupted 6-0 silk suture. The patients and their searchers were masked to the treatment. Postoperative management included intravenous antibiotics, anti-inflammatory drugs and haemocoagulants. Bandage was opened after one day and gentle syringing was done with 1 ml of gentamicin (40mg). Regular follow-ups were done at 1 week, 1 month, 3 month interval and thereafter 6 monthly. Objective and subjective findings were followed up for 6 months. All cases were evaluated by transcanalicular nasolacrimal irrigation and trans-nasal endoscopic examination. At each visit, the success rate was evaluated objectively based on the patency of drainage system on irrigation and subjectively on degree of epiphora by Munk's score.

Munk's score of epiphora

Grade 0 No epiphora

Grade 1 Occasional epiphora requiring dabbing < than twice a day

Grade 2 Epiphora requiring dabbing two to four times per day

Grade 3 Epiphora requiring dabbing 5–10 times per day

Grade 4 Epiphora requiring dabbing more than 10 times per day

Grade 5 Constant tearing

Analysis of results was done using SPSS Software (version 22) with P values < 0.001 was considered statistically significant. Chi square test was used to compare the variables.

III. Results

A total of 60 patients (eyes) with chronic dacryocystitis were included in the study in a 18 month duration. Other cases not fitting inclusion criteria were excluded out of study. Among 60 patients, 23 were males and 37 were females. Mean age (SD) of patient was 43.88 +/-10.51 years. 70.83% of the cases were from rural area while 29.17% cases were from urban area. Success achieved in the study was graded as 'good', 'fair' and 'poor (failure)' based on outcome. Outcome was assessed objectively, by syringing & subjectively, by Munk's scoring system at the end of 06 month.

TABLE 1: Age distribution in study population

Age group	Group A Mitomycin c N=30	Group B Conventional N=30	P value
<30 Years	3(10%)	3(10%)	0.432
31-40 years	8(26.6%)	8(26.4%)	
51-60 years	6(20%)	7(23.4%)	
>60 years	4(13.4%)	3(10%)	

Table 2: Descriptive analysis of gender in study population

Gender	Study group		P value
	Mitomycin C N=30)	Conventional N=30)	
Male	12(40%)	11(36.6%)	0.482
Female	18(60%)	19(63.7%)	

Table 3: Subjective improvement in epiphora Outcome (Munk'sscore)

Group	Improvement in watering symptoms		
	Poor outcome	Fair Outcome	Good Outcome
Group A MMC	1(3.33%)	2(6.66%)	27(90%)
Group B Conventional [EXT DCR]	3(10%)	6(20%)	21(70%)

Table 4: Comparison of study group based on post-operative follow-up

Follow up	Group	Symptom		LacrimalSac Syringing		Tear meniscus height	
		No	Yes	Patent	Non patent	Normal	High
1st week	MMC (N=30)	30 (100%)	0 (0%)	30 (100%)	0 (0%)	30 (100%)	0 (0%)
	Conventional (N=30)	27 (90%)	3 (10%)	27 (90%)	0 (0%)	27 (90%)	0 (0%)
	P value	*		*		*	
1st month	MMC (N=30)	28 (93.3%)	2 (6.7%)	28 (93.3%)	2 (6.7%)	28 (93.3%)	2 (6.7%)
	Conventional (N=30)	25 (83.3%)	5 (16.7%)	25 (83.3%)	5 (16.7%)	25 (83.3%)	5 (16.7%)
	P value	0.019		0.019		0.019	
3rd month	MMC (N=30)	28 (93.3%)	2 (6.7%)	28 (93.3%)	2 (6.7%)	28 (93.3%)	2 (6.7%)
	Conventional (N=30)	24 (80%)	6 (20%)	24 (80%)	6 (20%)	24 (80%)	6 (20%)
	P value	0.001		0.001		0.001	
6th month	MMC (N=30)	28 (93.3%)	2 (6.7%)	28 (93.3%)	2 (6.7%)	28 (93.3%)	2 (6.7%)
	Conventional (N=30)	24 (80%)	6 (20%)	24 (80%)	6 (20%)	24 (80%)	6 (20%)
	P value	0.001		0.001		0.001	

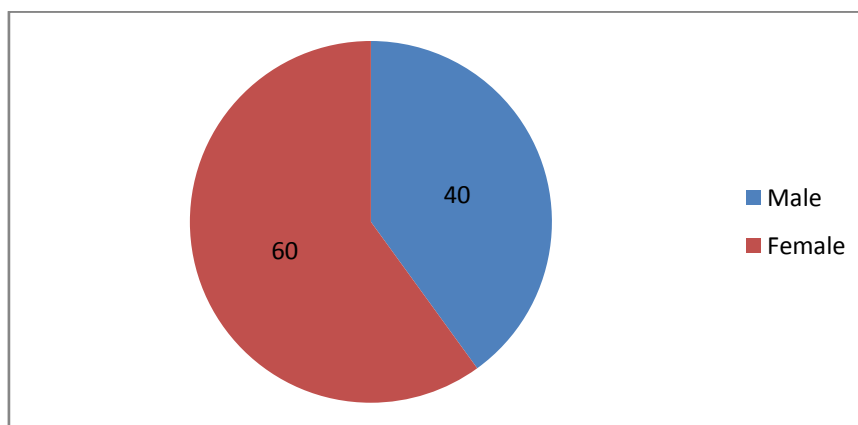


Fig. 1: Gender distribution in the study population

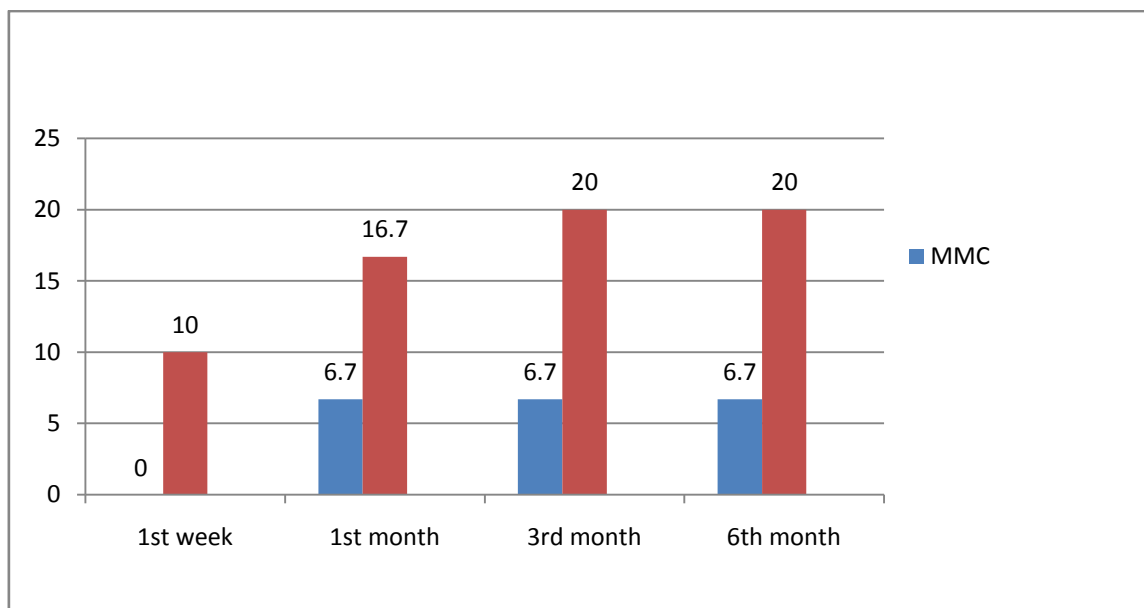


Figure 2: Comparison of study group based on post-operative follow-up

Postoperatively (Table 4) (Fig. 2), the patients were followed up at 1st week, 1st month, 3rd month and 6th month. Patients were assessed based on symptoms (watering of eyes), tear meniscus height and lacrimal sac syringing. Success achieved in the study was graded as 'good', 'fair' and 'poor (failure)' based on outcome. Outcome was assessed objectively, by syringing & subjectively, by Munk's scoring system at the end of 6 months. Good outcome was considered in cases where fistulous opening was freely patent and patients had subjective epiphora of Munk's score 0 to 1. Fair outcome was labelled when passage was patent on syringing but with some resistance to flow and patient had Munk's score 2 to 3. Poor outcome was when passage was not patent on syringing and patient's epiphora scored 4 to 5. (Table 3) Out of 30 patients in group B, 3 cases had poor outcome and 6 cases had fair outcome. Out of 30 patients in group A, 1 patient had poor outcome while 2 patients had fair outcome. Based on the observation, it was found that at 6th month of follow up postoperatively, with 30 patients each group, only 2 patient (6.6%) in Group A and 6 patients (20%) in Group B had a non patent lacrimal drainage system. The P value was 0.001 and difference between the two groups was significant.

IV. Discussion

In this study, female to male ratio was 1.5:1. High predilection of NLDO for females has been reported by many workers. Meller and co-workers suggested that higher involvement in females was due to narrower lumen of bony canal i.e. nasolacrimal canal while Heinonen associated it with nasal index.[16,17] An endocrine etiology has also been suggested by G.Pico.[18]. In another study, causes of DCR failure in 30.76% patients were intranasal adhesions, abnormal fistula size in 22.30% patients, and close ostium in 6.15%[13]. It is clear that fibrous tissue growth, scarring and granulation tissue formation during the wound healing process results in stenosis of common canaliculus opening or closure of osteotomy in the lateral wall of the nose, culminating in failure of DCR surgery. Following dacryocystorhinostomy (DCR,) scarring and subsequent cicatricial closure of the osteotomy site is quite common.[18,19] Mitomycin C (MMC) is used as an adjuvant thereby helps in preventing such complications. Success rate is better in patients where External DCR is done along with an intra operative antifibrotic - Mitomycin C when compared to patients in whom only conventional external dacryocystorhinostomy is done.[20] Currently, there are no definite guidelines on dose and duration of MMC application in DCR surgery. Ali et al[21] demonstrated 0.2 mg/ml of MMC for 3 min to be effective in reducing fibrosis without causing much apoptosis. In DCR surgery, the efficacy of intra operative MMC (0.2mg/ml) was compared with control group undergoing Conventional DCR in Liao *et al.*[22], It was found that non patency rate was 4.5% among 44 patients in MMC group and 11.4% among 44 patients in the control group after 10 months of follow up postoperatively ($P < 0.05$). Histo pathological effects of MMC on transnasal DCR by using intraoperative MMC (0.5mg/ml) at the osteotomy site was assessed by Ugurbas et al.[23] Light and electron microscopy examination of the intra operative and post operative specimens which were collected from 4 patients at day 15th, 1st month and 6th month, revealed attenuated epithelium and looser hypo cellular sub epithelial connective tissue in the MMC specimens and this serves as an evidence to know the potency of MMC application at the osteotomy site when used intra operatively. Kao SCS et al [24] observed effect of intraoperative 0.2 mg/ml MMC application for 30 minutes on size of ostium after DCR and found statistically

significant difference in ostium size in two groups after 6 months from day of surgery. The effectiveness of intraoperative MMC treatment in DCR surgery was reported by You and Fang.[25] Is Fifty eyes were included in the study and were divided into 3 groups. MMC 0.2 and 0.5 mg/mL were administered for 5 minutes and the results were compared with those of a conventional DCR surgery group. A significant difference was found between the MMC-treated patients and the control group in patency rate and osteotomy size; however, no significant difference was found between the 2 MMC groups. In our study, with 30 patients in each group, at 6th month of post operative follow up following DCR, only 2 (6.6%) patient in the Mitomycin C group whereas 6 (20%) patients (N=30) in the Conventional group reported unsatisfactory results following external dacryocystorhinostomy. There was a statistically significant difference between the two groups with a P value of 0.001. The main limitation of this study is its short follow-up. Studies with longer follow-up may be performed to find long-term outcome of intraoperative use of MMC in external DCR. In short-term follow-up intraoperative use of MMC during external DCR surgery increase the success of the procedure.

V. Conclusion

Using 0.2 mg/ml mitomycin-C for 02-10 minutes intraoperatively in external dacryocystorhinostomy (DCR) provided much better surgical results regarding the lacrimal drainage system patency, than conventional external dacryocystorhinostomy without mitomycin-C and hence can be considered as a safe and effective modification in conventional dacryocystorhinostomy.

References

- [1]. Kanski JJ, editor. Clinical ophthalmology a systemic approach: lacrimal drainage system. 6th edition. China: *Butterworth Heinemann Elsevier*; 2007.
- [2]. Zaman M, Babar TF, Abdullah A. Prospective randomized comparison of dacryocystorhinostomy (DCR) with and without intubation. *Pak J Med Res* 2005; **44**:75-8.
- [3]. Imran H, Chatta RU, Latif S, Aslam N. Analysis and efficacy of dacryocystorhinostomy performed with nasal endoscope and its advantage over external dacryocystorhinostomy. *Ophthalmology Update* 2012; **10**:217-9.
- [4]. Seider N, Kaplan N, Gilboa M, Gdalon M, Miller B, Beiran I. Effect of timing of external dacryocystorhinostomy on surgical outcome. *Ophthalm Plast Reconstr Surg* 2007; **23**:183- 6.
- [5]. Marr JE, Lee AD, Willshaw HE. Management of childhood epiphora. *Br J Ophthalmol* 2005; **89**:1123-6.
- [6]. Deka A, Bhattacharjee K, Bhuyan SK, Barua CK, Bhattacharjee H, Khaund G. Effect of mitomycin C on ostium in dacryocystorhinostomy. *Clin Experiment Ophthalmol*. 2006;34:
- [7]. Hallum AV. The Dupuy-Dutemps dacryocystorhinostomy. *Am J Ophthalmol*. 1949;32:1197
- [8]. Mcpherson TR, Egleston DB. Dacryocystorhinostomy. *Am J Ophthalmol*. 1959;47:328-31
- [9]. Cheng SM, Feng YF, Xu L, Li Y, Huang JH. Efficacy of mitomycin C in endoscopic dacryocystorhinostomy: A systematic review and meta-analysis. *PLoS One*. 2013;8:e62737.
- [10]. You YA, Fang CT. Intraoperative mitomycin C in dacryocystorhinostomy. *Ophthalm Plast Reconstr Surg*. 2001;17:115
- [11]. Roozitalab MH, Amirahmadi M, Namazi MR. Results of the application of intraoperative mitomycin C in dacryocystorhinostomy. *Eur J Ophthalmol*. 2004;14:461-463.
- [12]. Liao SL, Kao CS, Tseng JH, et al. Results of intraoperative mitomycin C application in dacryocystorhinostomy. *Br J Ophthalmol*. 2000;84:903-906.
- [13]. Ibrahim HA, Batterbury M, Banhegyi G, McGalliard J. Endonasal laser dacryocystorhinostomy and external dacryocystorhinostomy outcome profile in a general ophthalmic service unit: A comparative retrospective study. *Ophthalmic Surg Lasers*. 2001;32:220-227.
- [14]. Kashkoul MB, Parvaresh MM, Mirzajani H, et al. Intraoperative mitomycin C use during filtration surgery and lacrimal drainage system obstruction. *Am J Ophthalmol*. 2009;147:453-457. e1.
- [15]. Deka A, Bhattacharjee K, Bhuyan SK, et al. Effect of mitomycin C on ostium in dacryocystorhinostomy. *Clin Experiment Ophthalmol*. 2006;34:557-561.
- [16]. Meller J. Diseases of lacrimal apparatus. UK:Transactions of Ophthalmic Society;1929.p.233
- [17]. Heinonen, Diss. Helsingfors. See Klin. Mb Auganhelik,65,601; 120. 18.Pico G: A modified technique of external dacryocystorhinostomy. *Am. J Ophthalmol*, 72:679;1971.
- [18]. Yildirim C, Yaylali V, Esme A, Ozden S. Long-term results of adjunctive use of mitomycin C in external dacryocystorhinostomy. *Int Ophthalmol*. 2007;27:31-5.
- [19]. Cokkeser Y, Evereklioglu C, Er H. Comparative external versus endoscopic dacryocystorhinostomy: Results in 115 patients (130 eyes). *Otolaryngol Head Neck Surg* 2000;123:488-91.
- [20]. McLachlan DL, Shannon GM, Flanagan JC. Results of dacryocystorhinostomy: analysis of the reoperations. *Ophthalmic Surg*. 1980;11:427-30.
- [21]. Ali MJ, Baig F, Lakshman M, Naik MN. Electronmicroscopic features of nasal mucosa treated with topical and circumstantial injection of mitomycin C: Implications in dacryocystorhinostomy. *Ophthalm Plast Reconstr Surg*,2015;31:103-7
- [22]. Liao SL, Kao CS, Tseng JH. Results of intraoperative mitomycin C application in dacryocystorhinostomy. *Br J Ophthalmol*. 2000;84:903-6.
- [23]. Ugurbas SH, Zilelioglu G, Sargon MF. Histopathologic effects of mitomycin-C on endoscopic transnasal dacryocystorhinostomy. *Ophthalmic Surg Lasers* 1997;28:300-4.
- [24]. Kao SC, Liao CL, Tseng JH, Chen MS, Ho PD. Dacryocystorhinostomy with intraoperative mitomycin C. *Ophthalmology*, 1997 Jan 1;104(1):86-91.12.
- [25]. You YA, Fang CT. Intraoperative mitomycin C in dacryocystorhinostomy. *Ophthalmic Plastic & Reconstructive Surgery*, 2001 Mar 1;17(2):115-9.14.