

## A Rare Presentation of Multiple Fungal Balls in Type 1 Diabetes Mellitus with Old Pulmonary Tuberculosis

Dr Bharath Singh<sup>1</sup>, Dr Esther Rani<sup>2</sup>, Dr Phani Kumar<sup>3</sup>

1. Post Graduate in General Medicine, SVMC & SVRRGGH Tirupati, 2. Post Graduate in General Medicine, SVMC & SVRRGGH Tirupati & 3. Senior resident, Department of Neurology, SVIMS Tirupati.

Corresponding Author: Dr Bharath Singh

**Abstract:** Aspergillosis is the collective term used to describe all the disease entities caused by more than 50 pathogenic and allergic species of *Aspergillus*, *A. fumigatus* being the most responsible specie for invasive and chronic aspergillosis. The primary risk factors being profound neutropenia and glucocorticoid use. We are reporting a rare case of bilateral multiple fungal balls in a 22-year-old Type I diabetic patient with prior history of pulmonary tuberculosis.

Date of Submission: 09-10-2019

Date of Acceptance: 25-10-2019

### I. Introduction

**Aspergillosis** is the name given to a wide variety of diseases caused by fungal infection of the genus *Aspergillus*. The majority of cases occur in people with underlying illnesses such as tuberculosis or chronic obstructive pulmonary disease (COPD), steroid abuse and may occur with otherwise healthy immune systems. Most commonly, aspergillosis occurs in the form of chronic pulmonary aspergillosis (CPA), aspergilloma or Allergic BronchoPulmonary Aspergillosis (ABPA). Some forms are intertwined; for example, ABPA and simple aspergilloma can progress to CPA. The most frequently identified pathogen is *Aspergillus fumigatus*—a ubiquitous organism that is capable of living under extensive environmental stress. It is estimated that most humans inhale thousands of *Aspergillus* spores daily, but they do not affect most people's health due to effective immune responses. The mortality rate is 50% if infection is treated but 100% when diagnosis is missed.

### II. Case Report

A 22 years old female with 1 ½ year history of type I Diabetes mellitus presented to the emergency department with C/o decreased food intake since 1-week excessive thirst and increased frequency of urination for one week. Vomiting (5 – 6 episodes) for 2 days. Abdominal pain with loose motions for 1 day. Past history of Anti tuberculous therapy for pulmonary TB and extra pulmonary TB lymph node for 10 months. On examination patient is conscious and coherent. Pulse rate 120 / min, BP 110/70 mm/Hg, cardiovascular system – S1, S2 present, respiratory system – bilateral coarse crepitation's present, per abdomen – tenderness present in epigastrium, CNS – no abnormal detected.

#### Investigations:

HB – 10 grms/dl, TC – 14,800 /mm<sup>3</sup>, DC – P<sub>78</sub>L<sub>18</sub> E<sub>4</sub>M<sub>0</sub>, ESR – 20 mm/hr, sputum – AFB – Negative, VCTC – Negative, FBS – 340 mg/dl, PPBS – 410 mg/dl, urine ketone bodies – Negative, serum electrolytes – Na<sup>+</sup> - 123 mmol/l, K<sup>+</sup> - 2.8 mmol/l, Cl<sup>-</sup> - 90 mmol/m.

#### CT Chest:

Bilateral upper lobe Bronchiectasis changes with multiple continuous lesions.  
Few cavities with fungal ball (mycetoma).

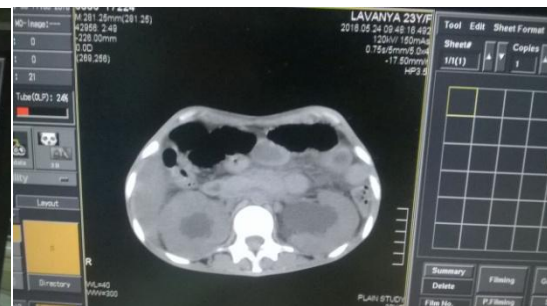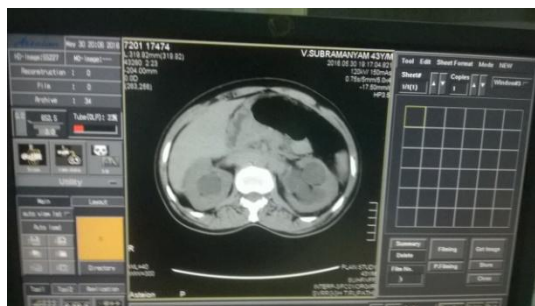
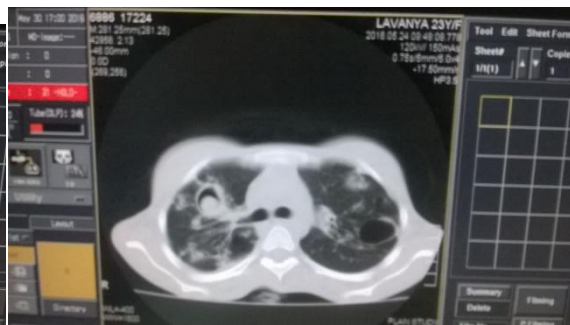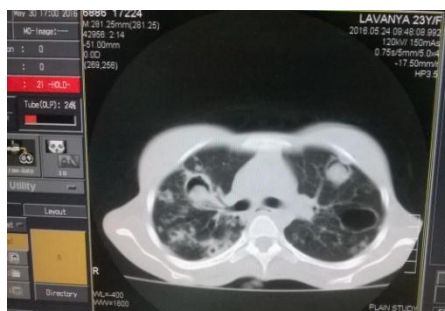
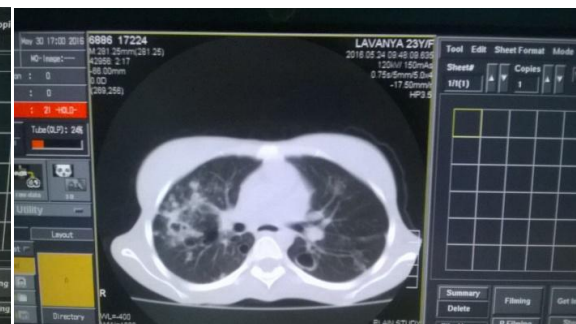
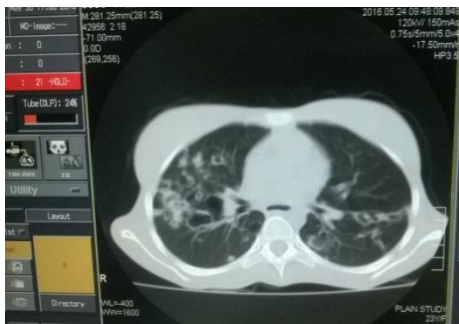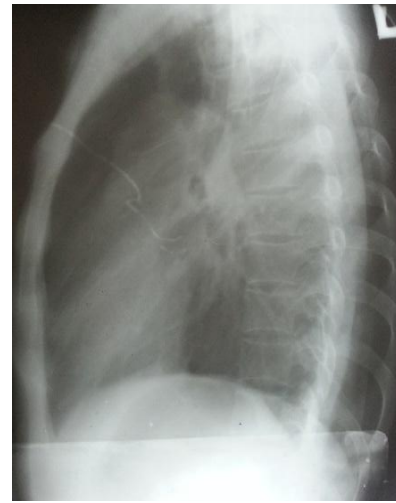
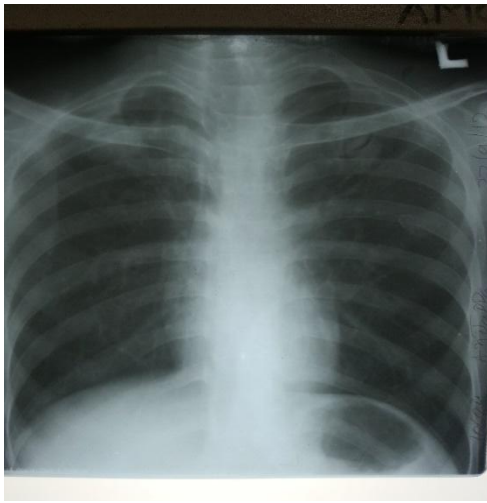
#### Ultrasound abdomen:

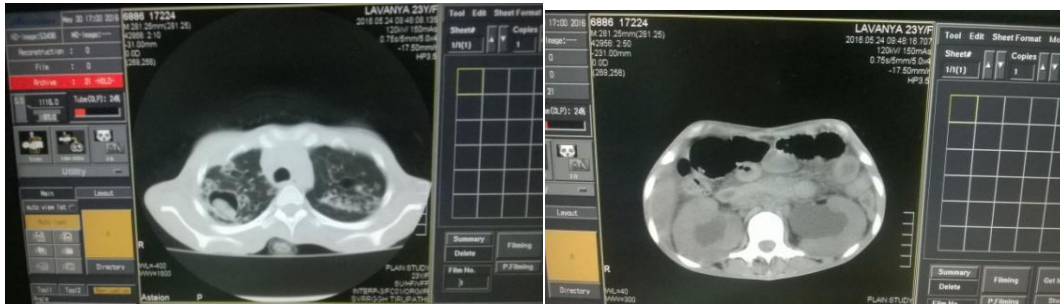Bilateral hydro uretero nephrosis  
Bladder wall thickening  
Bilateral grade – 1, RPD changes.

Chest X ray showed non homogenous opacity in left upper zone. CT chest showed B/L upper lobe cavity with intra cavitory hyperdense nodules with crescent sign. Nodules are varying in position and non-enhancing, probably ASPERGILLOMA.

*A Rare Presentation of Multiple Fungal Balls in Type 1 Diabetes Mellitus with Old Pulmonary*

Patient was treated with inj. Piperacillin – Tazobactam for 5 days and tablet. Itraconazole 200mg twice daily with strict glycaemic control and other supportive management with proper nutrition. Patient condition improved symptomatically.





### III. Discussion

Infections due to *Aspergillus* species result in significant morbidity and mortality. Most infections are attributed to *Aspergillus fumigatus*, followed by *Aspergillus flavus* and *Aspergillus terreus*. Fungal pneumonia is an infectious process in the lungs caused by one or more endemic or opportunistic fungi. Fungal infection occurs following the inhalation of spores, after the inhalation of conidia, or by the reactivation of a latent infection. Haematogenous dissemination frequently occurs, especially in an immunocompromised host. *Aspergillus* presents as a spectrum of clinical syndromes like Invasive pulmonary aspergillosis, chronic necrotising aspergillosis, Aspergilloma (fungal ball), allergic bronchopulmonary aspergillosis.<sup>1</sup>

Invasive pulmonary aspergillosis usually occurs in severely immunocompromised patients.<sup>2</sup> The expanded use of glucocorticoids accounts for increasing number of fungal infections reported in mildly or non-immunocompromised hosts.<sup>3</sup> Other most common risk factors include neutropenia, acute leukaemia, and relapsing disease, ADE protocol of chemotherapy and nosocomial infections.

Genetic predisposition: With regard to predisposition through stem cell transplants, certain toll-like receptor (TLR) polymorphisms (e.g., TLR 4 haplotype S4) in an unrelated stem cell donor can increase the risk of invasive aspergillosis in the transplant recipient. Similarly, TLR1 and TLR6 polymorphisms in the recipient have been associated with susceptibility to invasive aspergillosis after allogeneic stem cell transplantation.<sup>4</sup>

Complications of fungal pneumonia include (1) disease dissemination to other sites (i.e., brain, meninges, skin, liver, spleen, kidneys, adrenals, heart, and eyes) and sepsis syndrome and (2) blood vessel invasion, which can lead to pulmonary haemoptysis, infarction, myocardial infarction, cerebral emboli, cerebral infarction, or blindness. Others include Bronchopleural or tracheoesophageal fistulas, chronic pulmonary symptoms, Mediastinal fibrosis (histoplasmosis), Broncholithiasis (histoplasmosis), Pericarditis and other rheumatologic symptoms.<sup>5</sup>

The endemic fungal pneumonias are generally self-limited in healthy hosts. Patients with fungal pneumonias may develop chronic pulmonary (e.g., cavitation, pleural effusions, bronchopleural fistulas) or extra pulmonary complications. In patients with AIDS, the mortality rate is as high as 70%. Aspergillosis in patients who are neutropenic (from either leukaemia chemotherapy or bone marrow transplantation) has a mortality rate of 50-85%. More often, in the case of aspergillosis, the cause of mortality in patients who are immunocompromised is disseminated disease.<sup>6</sup> Endemic fungal disease affects men (75-95%) more often than women; oestrogen-mediated inhibition of mycelium-to-yeast transformation may be responsible for the male predominance.

History findings in persons with fungal pneumonia may include, fever, cough (usually non-productive), chest discomfort, dyspnoea, enlarged mediastinal adenopathy, haemoptysis, hypersensitivity or allergic reactions. In individuals who are neutropenic or immunocompromised, persistent fever (even before pulmonary findings) may be an early sign of infection, especially if the fever is unresponsive to broad-spectrum antibiotics. Hypersensitivity or allergic reactions include allergic bronchial asthma (*Aspergillus* species, *Candida* species), allergic bronchopulmonary mycoses (*Aspergillus* species, *Candida* species), bronchocentric granulomatosis (necrotizing granulomatous replacement and eosinophilic infiltration of bronchial mucosa in infection with *Aspergillus* species), and extrinsic allergic alveolitis (malt worker's lung, farmer's lung).

Various antigen detection assays, such as galactomannan enzyme immunoassay for detection of *Aspergillus* invasive infections, are now in clinical use. Polymerase chain reaction (PCR)-based assays are also available for detecting various pathogens, including *Aspergillus*, *Histoplasma*, and *Candida* species. For *Aspergillus* species antigen, galactomannan ELISA assay findings may be positive in the blood very early prior to clinical suspicion of invasive fungal infection and may be of use in monitoring and pre-emptive treatment in high-risk populations.

Using a galactomannan platelia *Aspergillus* enzyme immunoassay approved by the US Food and Drug Administration (FDA), investigators showed that 2 consecutive samples with an optical index of 0.5 provided the highest test accuracy (specificity, 97.5%; sensitivity, 92.1%; positive predictive value, 87.5%; negative predictive value, 98.5%). Testing in bronchoalveolar lavage (BAL) fluid increased the sensitivity compared with

serum galactomannan assay from 71-100%. Beta-glucan testing is also available and may be comparable or more sensitive than galactomannan assays in diagnosing invasive aspergillosis; several kits are available worldwide. False-positive results have also been reported in patients receiving fungal-derived antibiotics and cross-reactions have been reported with *Pseudomonas aeruginosa* infections.<sup>7</sup>

*Aspergillus* PCR is most sensitive (100%) when performed on the bronchial lavage fluid of patients with invasive pulmonary aspergillosis, but it is only 40-66% sensitive when performed on the blood. No standardized protocols have been established among laboratories that re performing this assay.

CxR may show patchy infiltrate, nodules (seen in the image below), consolidation, cavitation, or pleural effusion.<sup>8</sup> Mediastinal adenopathy is common in patients with endemic fungal pneumonias. The adenopathy may be either unilateral or bilateral. Miliary infiltration occurs in patients with disseminated disease.

High-resolution chest computed tomography (CT) scanning allows observation of the halo sign in patients with aspergillosis. This is a nodular lesion usually surrounded by a ground-glass opacity or halo.<sup>9</sup> Obtaining a CT scan of the abdomen and brain may reveal sites of dissemination.

Magnetic resonance imaging (MRI) may reveal the haemorrhagic content of *Aspergillus* lesions.

Fiberoptic bronchoscopy (procedure of choice) is used to obtain bronchial lavage specimens for staining and culture techniques and transbronchial biopsy specimens for identification of fungal tissue invasion, shows varying yields in *Aspergillus*, for which clinical correlation is still important.<sup>10</sup> An open lung biopsy is the only way to prove invasive disease for *Aspergillus* or *Candida* organisms; however, this procedure may be difficult to perform in patients with severe neutropenia and thrombocytopenia who are in respiratory failure.

In cases in which aspergillosis, mucormycosis, and candidiasis occur in an immunocompromised host, reversing the factors affecting the patient's immune status is linked to successful recovery from the infection. Attempt ancillary events that may help to promote recovery from the opportunistic infection. These include (1) ensuring, with the use of growth factors, neutropenia recovery in patients receiving chemotherapy and bone marrow transplants; (2) withdrawing or tapering immunosuppressive drugs and steroids; and (3) removing infected or highly colonized catheters in patients with candidiasis. All patients with invasive disease; in patients who are immunosuppressed, early diagnosis and empiric treatment for persistent fever not responding to broad-spectrum antibiotics; high mortality once infiltrates and symptoms appear; prognosis ultimately linked to severity and outcome of underlying disease. Mortality rate of 50-60% in patients with AIDS; mortality rate as high as 85% in patients with prior bone marrow transplantation. Oral itraconazole 200mg twice daily is the preferred agent for chronic and allergic forms of aspergillosis. Voriconazole is the new standard of care for invasive aspergillosis based on superiority over amphotericin B in primary therapy. Oral voriconazole can be used to complete treatment with initial response to IV voriconazole or amphotericin B, Caspofungin is used as salvage therapy. Surgical treatment is often curative in aspergillomas.

## References

- [1]. Harrison's internal medicine; 200<sup>th</sup> edition 2019; 1532-37.
- [2]. Denning DW. Aspergillosis in 'nonimmunocompromised' critically ill patients. *Am J Respir Crit Care Med* 2004; 170: 580-581.
- [3]. Berenguer J, Allende MC, Lee JW, et al. Pathogenesis of pulmonary aspergillosis granulocytopenia vs cyclosporine and methylprednisone-induced immunosuppression. *Am J Respir Crit Care Med* 1995; 152: 1079-1086.
- [4]. Kesh S, Mensah NY, Peterlongo P, Jaffe D, Hsu K, VAN DEN Brink M, et al. TLR1 and TLR6 polymorphisms are associated with susceptibility to invasive aspergillosis after allogeneic stem cell transplantation. *Ann N Y Acad Sci*. 2005 Dec. 1062:95-103. [Medline].
- [5]. Ader F, Nseir S, Le Berre R, et al. Invasive pulmonary aspergillosis in chronic obstructive pulmonary disease: an emerging fungal pathogen. *Clin Microbiol Infect* 2005; 11: 427-429.
- [6]. Segal BH, Walsh TJ. Current approaches to diagnosis and treatment of invasive aspergillosis. *Am J Respir Crit Care Med*. 2006 Apr 1. 173(7):707-17. [Medline].
- [7]. Meersseman W, Vandecasteele SJ, Wilmer A, et al. Invasive aspergillosis in critically ill patients without malignancies. *Am J Respir Crit Care Med* 2004; 170: 621-625.
- [8]. Bulpa PA, Dive AM, Garrino MG, et al. Chronic obstructive pulmonary disease patients with invasive pulmonary aspergillosis: benefits of intensive care. *Intensive Care Med* 2001; 27:59-67.
- [9]. Agusti C, Ransohoff A, Filella X, et al. Pulmonary infiltrates in patients receiving long-term glucocorticoid treatment: etiology, prognostic factors, and associated inflammatory response. *Chest* 2003; 123: 488-498.
- [10]. Gefter WB, Albelda SM, Talbot GH, et al. Invasive pulmonary aspergillosis and acute leukemia: limitations in the diagnostic utility of the air crescent sign. *Radiology* 1985; 157: 605-610.

Dr Bharath Singh. "A Rare Presentation of Multiple Fungal Balls in Type 1 Diabetes Mellitus with Old Pulmonary Tuberculosis." *IOSR Journal of Dental and Medical Sciences (IOSR-JDMS)*, vol. 18, no. 10, 2019, pp 30-33.