

Acute Flaccid Quadriplegia as a Presenting Manifestation in Diabetic Ketoacidosis in Denovo Diabetic Patient- A Rare Case Report

*Dr.K.Veerabhadraiah M.D ,** Dr.Malleswari Belle M.D

*Professor, ** Asst.Professor,Dept in Medicine Government Medical College, Anantapur Andhra Pradesh, India

Corresponding Author: Dr. K.Veerabhadraiah M.D

Abstract: Diabetic ketoacidosis is the most common presenting manifestation in previously undiagnosed diabetic patients coming to emergency department. Acute generalised weakness and paralysis due to various causes is also the most common in ER. In the present case the patient presenting with progressive weakness and breathlessness of short duration. On evaluation by history and clinical examination revealed that patient had symptoms suggestive of diabetes but not diagnosed yet. And there is hypotonia ,areflexia of all limbs with severe respiratory distress and acidotic breathing. Laboratory investigations revealed that patient has diabetic ketoacidosis with severe hypokalemia .Severe symptomatic hypokalemia is rare initial clinical manifestation of DKA.

Key Words: Hypokalemia, hyperaldosteronism,Hyperglycemic, Keto acidosis

Date of Submission: 17-10-2019

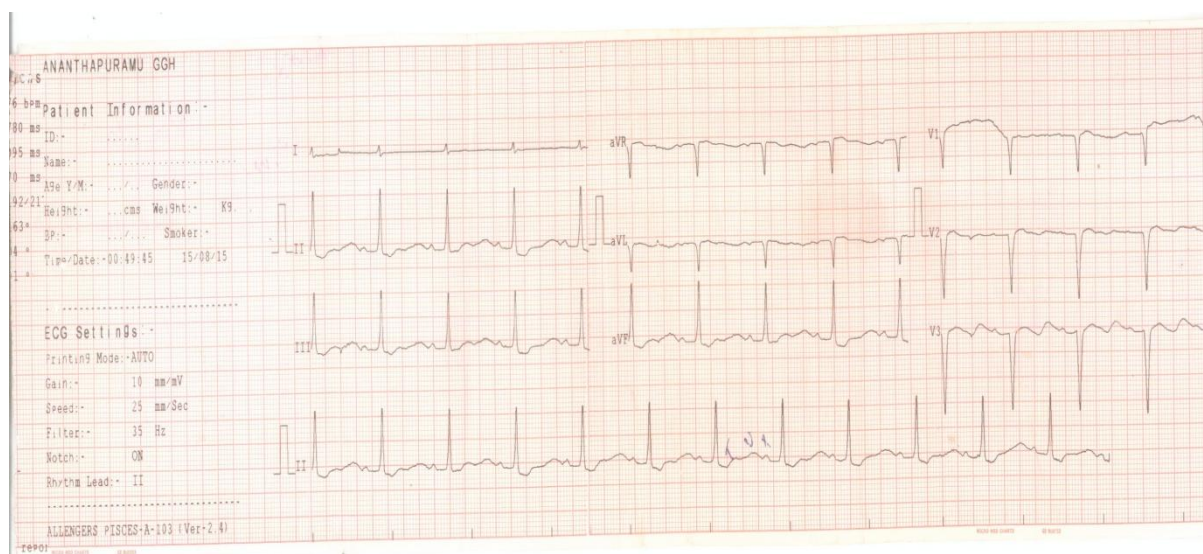
Date of Acceptance: 02-11-2019

I. Introduction

Generalised progressive weakness is common complaint encountered in OPD and Emergency. Severity of symptoms varies from mild ,distributed to certain group of muscles to severe - quadriplegia, respiratory and bulbar muscle paralysis. There are numerous etiologies for the cause based on the severity, progression and distribution of the weakness the etiologies are shortlisted. The reasons could be metabolic, neurological ,neuromuscular, muscular, toxic. Hypokalemia is the most common cause for acute flaccid quadriplegia which is also reversible. Symptoms of hypokalemia also range from mild weakness to severe respiratory paralysis. Metabolic acidosis can cause low serum potassium due to transcellular shift which is usually mild and symptoms of metabolic abnormality and acidosis predominate over those of hypokalemia.here in our case symptoms of hypokalemia predominate and made the patient seek medical attention in the background undiagnosed diabetes.

II. Case Report

A thirty year old lady ,house wife ,presented to the emergency department at midnight with complaints of weakness of all limbs since morning . weakness started suddenly in the lower limbs and rapidly progressed to upper limbs and neck over few hours. History of fall few minutes before arrival to hospital as she attempted to get up from bed .Patient do not have history of loss of consciousness, seizure activity, speech difficulty,splinter incontinence or retention. There is no difficulty in breathing or swallowing . There are no sensory symptoms. No history of fever, G.I losses, diuretic abuse. On clinical examination patient is conscious, coherent and well oriented. She is dehydrated ,a febrile, pulse rate 80per minute, regular and blood pressure is 120/80mm of Hg, respiratory rate is 34 cycles per minute regular and deep. Neurological examination revealed hypotonic of all limbs with power of grade 2/5 and deep tendon reflexes grade is 1+. Investigations are blood sugars 410mg% , serum electrolytes – sodium 124 meq/Lt , potassium 1.6 meq/Lt, chloride 80 meq/Lt. Blood urea 24mg% ,serum creatinine 1.2mg%. urine sugars 4+,albumin-traces, ketones 3+.Acid blood gas analysis –P^H -7.20 , P CO₂- 14 mm of Hg, P O₂-142mm of Hg, HCO₃-8meq, ECG- prominent U waves in all leads, increased QT interval-ray cervical spine is normal.Patinet is diagnosed to have diabetic keto acidosis with hypo natremia and hypokalemia with quadriplegia. Treatment started with KCl infusions with simultaneous hydration but patient rapidly deteriorated and developed respiratory failure,desaturation. She was started on mechanical ventilation. Before full correction of potassium patient landed in cardiac arrest and died .The cause of death in this case is probably due to impaired cardiac contractility due to hypokalemia and stopped in diastole.



III. Discussion

Hypokalemia with metabolic acidosis is seen in conditions like RTA ,DKA, Drug overdose. In present case with hyperglycaemia, ketonuria, acidosis, dehydration, increased anion gap the diagnosis of DKA is confirmed .The basic abnormality is insulin deficiency and excess counter regulatory hormones. Excess lipolysis and ketone body production ⁽¹⁾. In the setting of DKA, acidosis will cause excess extracellular shift of potassium leading to hyperkalemia and relative insulin deficiency will impair the intracellular shift of potassium. hence hyperkalemia is the usual finding in DKA.

Hypokalemia is also explained in severe and prolonged DKA based on following mechanisms-

1. Dehydration due to osmotic diuresis and potassium loss
2. Activation of RAAS and hyper Aldosteronism
3. Initial hyperkalemia also stimulates aldosterone secretion.(aldosterone acts on the ROMK potassium channels and K⁺ secreted into renal tubules).⁽²⁾
4. Treatment of DKA with fluids and insulin therapy cause rapid insulin mediated transcellular shift and iatrogenic hypokelimia.^(3,4)

Hypokalemia at the time of presentation even before administration of insulin therapy is rare but possible as explained by the reasons above ⁽⁵⁾.

In the present case patient presented to emergency medicine with acute onset and rapidly worsening quadripareisis. Lower motor type of weakness with prominent 'U'waves in ECG and low serum potassium levels indicates hypokalemia related muscle paralysis which is explained by the impairment of membrane potentials of the conducting tissues – nerve and muscle. Among the various causes of hypokalemia ,here presence of high blood sugars , ketosis and acidosis indicate DKA as the cause of hypokalemia. Rarely DKA patients present with significant and symptomatic hypokalemia.^(6,7) in these patients potassium should be supplemented intravenously to bring the serum potassium atleast to 3.3meq/lit before starting insulin therapy for correction of blood sugars. In our patient potassium supplementation and ventilator support is given to tide over the respiratory crisis before starting insulin therapy. But before full electrolyte balance and metabolic control is attained ,patient died due to sudden cardiac arrest. This may be explained by the development of arrhythmias or a systole due to hypokalemia which again reverted after initiating the insulin therapy. Insulin therapy causes intracellular shift of the potassium leading to hyokalemia in patients with DKA even when it is normokalemia of hyperkalemia at the beginning.

Severe hypokalemia with manifest quadripareisis and respiratory compromise is rarely seen in DKA. Such presentation in our patient with undiagnosed diabetes is even more rare and it is the unique one encountered in our clinical practice.

References

- [1]. Bell DS, Alele J. Diabetic ketoacidosis: Why early detection and aggressive treatment are crucial . Postgrad Med 1997;101:193-204
- [2]. Attending Rounds: Patient with Hypokalemia and Metabolic Acidosis. Clin J Am soc Nephrol 6: 2516-2521, 2011. doi: 10.2215/CJN.04150511.
- [3]. Abdelaziz. Dabbagh O, Al Delcer MO, Hassan I: Hypokalemia and refractory asystole complicating DKA, lessons for prevention. BMJ case rep 2012; 2012: 1-3 (PMC Free article) .
- [4]. Fisher DS , Nichol BA. Intraventricular conduction defect and respiratory tract paralysis in Diabetic ketoacidosis. AMJ Med. 1963; 35:123-129. (Pubmed)

- [5]. Shanlee M Davis, aline B Muddux, Guy T Alonso, Carol R Okada, peter M Mourani and David M mechs. Profound Hypokalemia associated with severe DKA. *Pediatr Diabetes*.2016 Fed: 17(1) : 61-65.Published Online 2014 Nov 27. doi: 10.1111/ped 12246.
- [6]. H.K. Aggarwal, Deepak Jain, V.Kaverappa, S.YAdav, P.Jain. Quadripareisis as a presenting manifestation of Diabetic Ketoacidosis; A rare case report .*Diabetalgia Crotica* 42(2) : 60-4 June 2013.
- [7]. Murthy k, Harrington JT, Seigel RD. Profound hypokalemia in diabetic ketoacidosis: a therapeutic challange. *Endocr Pract* 2005;11(5):331-334.

*Dr.K.Veerabhadraiah M.D. “Acute Flaccid Quadripareisis as a Presenting Manifestation in Diabetic Ketoacidosis in Denovo Diabetic Patient- A Rare Case Report.” *IOSR Journal of Dental and Medical Sciences (IOSR-JDMS)*, vol. 18, no. 10, 2019, pp 06-08.