

Cystic Lymphangioma of Abdominal Wall in a Child, a Rare Site

Pranav Kumar Dave^{1*}, Vivek Gupta², R Mishra³, M Jain⁴, M Bapat⁵, M Tilgam⁶,
P Gupta⁶, A Patidar⁶, M Ram⁷, K Anand⁸, V Agarwal⁹ and C Dave¹⁰

^{1,2}Asso.Prof, ³Prof, ⁴Prof & HOD, ⁵Asst. Prof, ⁶Resident, -Department of Radio diagnosis, ⁷Asst of. Deptt. of Surgery ⁸Prof & HOD of surgery ⁹Prof of Pathology ¹⁰Ex.Asst Prof, - Department of Pediatrics,
L N Medical College and J K Hospital, Kolar Road, Bhopal-462042, MP, India.

*¹ Corresponding Author: Dr Pranav K Dave, Asso. Prof. Deptt. of Radiology,
E-7/540, MIG Senior, Arera Colony, Bhopal-462016, MP, India.

Abstract: Cystic lymphangiomas are rare, congenital, benign lesions occurring early in life, mainly in the head, neck, and oral cavity, rarely occur in abdominal wall. It is due to aberrant proliferation of lymphatic vessels resulting from abnormal development of the lymphatic system. Lymphangiomas are classified as micro cystic, macro cystic, and cystic hygromas according to the size of the lymphatic cavities incorporated. These are soft, variable in size and shape and tend to grow extensively if not surgically excised. These are multilocular cysts filled with clear or yellow lymph fluid, some time mixed with blood. Histopathologically, lymphangiomas are of three types: Lymphangioma simplex, Cavernous lymphangioma, and Cystic hygroma depending on the size of vascular spaces and thickness of the adventitia. The present case report describes a case of cystic lymphangioma of upper abdominal wall in a 13-year-old male child and its clinical, ultrasonographic, MRI, and cytological and histopathological correlation.

Key Words: Cystic Lymphangioma CL, Cystic Hygroma CH, Macro cystic lymphatic malformation, Abdominal wall .Child.

Date of Submission: 17-10-2019

Date of Acceptance: 02-11-2019

I. Introduction

Cystic lymphangioma or Cystic hygroma is a congenital malformation due to failure of communication between the primary lymphatic sacs to drain into the venous system¹. This results into the formation of a cystic structure.² Also known as macro cystic lymphatic malformation and was first described in 1828 by Redenbacher. Cystic lymphangiomas are reported to account for 5-6 % of all pediatric neoplasm³. CL commonly occur in neck, more than 80%. Other sites are in the maxilla, superior mediastinum, mesentery, retroperitoneal region, pelvis and lower limbs.^{4,5} Rarely it occurs on the abdominal wall. There is no predilection for either sex. Cystic lymphangiomas are slow growing tumors and usually located in one organ but once their infiltration into local tissue, surrounding muscles and adjacent nerve and vessels, then surgical removal becomes difficult. In our case parents noticed the progress of the swelling on abdominal wall, which was present since birth. Ultrasonographic and MRI findings were suggestive of cystic lymphangioma of abdominal wall. Aspiration cytology from the lesion and histopathological examination of excised lesion confirmed the clinical and imaging diagnosis of cystic lymphangioma.

II. Case Report

A 13 years old male child was referred to the Radiology department for Radiograph of chest, abdomen and Ultrasound examination of swelling in left side of upper abdominal wall. This swelling was since birth, which has progressively increased in size. There is a palpable soft non tender swelling of 6x5 cm size seen in subcutaneous plain of left upper lateral of abdominal wall on physical examination (**Figure -1-2**). The overlying skin was normal. The child was in good health with normal developmental milestones. No other physical deformity or abnormality was seen in rest of the body. All laboratory test results were normal.

Mother had not undergone any ANC ultrasound study. Child was born on full term normal vaginal delivery. Other siblings are normal.

Chest and Abdomen radiograph reveals soft tissue swelling over left lateral abdominal wall. No calcifications or any bone pathology seen. (**Figure-3-4**).

Ultrasound study of abdomen reveals large subcutaneous multilocular clusters of abnormal cystic channels with internal echoes of 6x 2x8 cm size in left upper abdominal wall. In few channels thin septae were seen. There was no abnormal vascularity seen on color Doppler. No obvious invasion of muscles seen (**Figure 5-6**). Ultrasound of abdomen and pelvis reveals no abnormality. MRI lower chest and abdomen findings showed

multiloculated T2 hyper intense lesion of 6.9x2.8x8.1 cms size in upper part of left lateral abdomen wall in subcutaneous plane. Few locules were hyper intense on T1 weighted images. There was no evidence of intra thoracic and intra abdominal extension. (**Figure 7-10**).The aspiration cytology from the lesion showed predominantly lymphocytes against a proteinaceous background.This lesion was surgically excised completely under all aseptic precaution and condition with preserving cosmetic function. The tumor showed cystic areas containing lymphatic fluid mixed with blood. (**Figure 11-12**).Histopathological of the excised tumor confirmed the clinical and imaging diagnosis of cystic lymphangioma.Patient recovered fully in post operative period without any complications. No evidence of recurrence of the lesion was seen in the subsequent follow up visit up to six weeks.

III. Discussion

The lymphatic system develops as sac -like out growth from the endothelium of veins in the fifth week of gestation. There are six primary lymph sacs develops ,two in jugulars,two iliac,one retroperitoneal and one cisterna chyli. Failure of communication with lymph system results in formation of CL⁶.

Cystic lymphangioma or hygroma is a congenital malformation of the lymphatic system and are of capillary, cavernous or cystic types. Also classified on basis of size of the cyst- as micro cystic(less than 2 cm), macro cystic (more than 2 cm in size) and mixed lymphangiomas (variable sizes of cysts) .Cystic lymphangioma / hygroma are results of sequestration of lymphatic tissue from lymphatic sacs during the development of lymphatic venous sacs. The sequestered tissue fail to communicate with the lymphatic or venous system and results in cystic dilatation of the lesion.⁴⁻⁵. Majority of cases present in the first 2 years of life and 65% are noted at birth.Wernher in 1843 described the various site of CL⁶.

Goldstein et al. focused on the prenatal dignosis of CL during the 15th and 22 nd week of gestation²by USG during the nuchal translucency test.About 75% cases are in the neck often in posterior triangle,20% in axilla and the remaining 5% in other parts of body³ . Although it can occur in any anatomical site in human body, the head and neck is affected more with a predilection for the left site .The other affected sites are the mediastinum, groin and retro peritoneum. Rare site of occurrence are anogenital region, forehead, orbit, buttock, tongue, gastrointestinal tract, extremity ,pelvis⁶. Hancock etal reported ³ various sites of involvement of CL are; cervical-31.45, craniofacial-18.9%, extremities-18.9%, trunk-9.2%, intraabdominal-9.2%, cervicoaxillothoracic-4.9%, multiple-3.8%, cervicomediastinal-2.25 and intrathoracic-1.6%. Pandit etal ⁴ reported two cases of CL in the abdominal wall (4.4%).Very few cases of CL of abdominal wall were published so far⁷⁻⁸ . In Kyeom Kim etal reported two case of CL, one was in the abdominal wall in LLQ and in other case CL was abdominal wall in RUQ³.Ammar et al ⁷ reported a case of CL in 10 years female child in left side of abdomen with mass extending to pelvic cavity.

Riahinezhad et al ⁸ reported a case of 9 years male child with sudden onset of localized abdominal pain and bulging caused by rapid expansion of a hemorrhagic cystic lymphangioma of the abdominal wall. Most common presentation is slow growing painless lump in otherwise asymptomatic child. The effect of these lesions depends on their position and relationship to surrounding structure⁴⁻⁵.In our case the lesion was slowly increasing in size, although parents noticed this in infancy. Ravi Kapoor etal described four different types of sonographic features for lymphangioma (a) cystic with thin setae;(b) cystic with thick septae;(c) cystic with thick septae and solid areas;(d)mainly solid with scattered cystic areas⁹.

Anupam Lal etal described various radiological manifestations for abdominal lymphatic malformation¹⁰ .

Radiological findings were similar in our case.Ultrasound study revealed a multiloculated cystic mass with thin internal septae and absent blood flow on color Doppler .MRI finding are useful in determining the form, extent and nature of lesion ¹².MRI showed high signal intensity in T2W1 and low signal intensity in T1W1. USG and MRI findings were similarly observed in our case. CT study reveals a large thin wall multiseptated cystic mass. And show fluid attenuation, unless complicated by hemorrhage ¹¹.However in our case CT study was not performed.

Aspiration cytology of the lesion was showing predominantly lymphocytes against a proteinaceous background. Aspiration of the lesion may result in reduction in size temporarily only. Surgical excision of the lesion is considered as a standard treatment. Incomplete excision often results in recurrence. Other surgical complications are damage to surrounding blood vessels, nerves and infection hypertrophied scar and lymphatic discharge from the wound¹³ . About 20% of cases are reported to have recurrence of lesion .Post operative period was unremarkable and no recurrence of the lesion seen in follow up examination in our case⁵.It is important to know the relationship between the cystic mass and the peritoneum as this decide the lesion is extra peritoneal in subcutaneous plane or with extension to peritoneal cavity.Therefore,it is important to differentiate between CL involving the properitoneal fat layer and other cystic masses in peritoneal cavity. The presence of peritoneal lining elevation and prominent properitoneal fat surrounding the mass can help in determining whether the mass is located within or in extra peritoneal cavity. These are valuable radiological observation and

helpful for planning the surgery. In our case the lesion was extra peritoneal in subcutaneous planes of left upper abdominal wall. Use of sclerosing agents, laser therapy, radiation therapy and chemotherapy may be used as alternative treatment in poor surgical cases.

IV. Conclusion

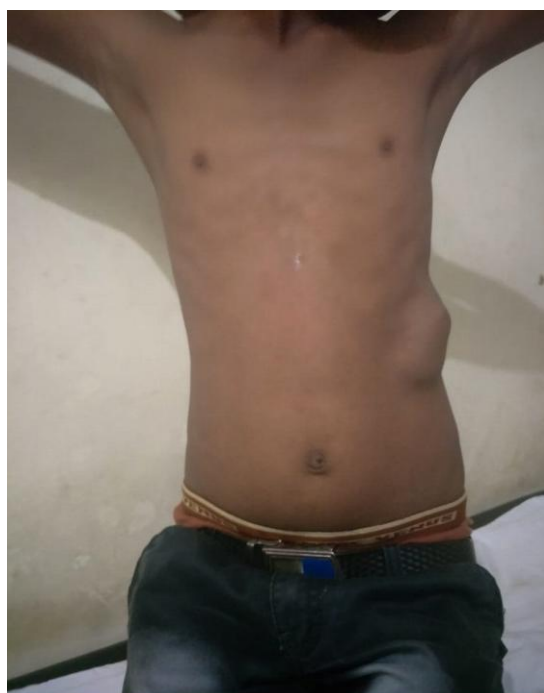Cystic lymphangioma / Hygroma is a commonly seen in pediatric age group. Abdominal wall is a common site of involvement, should be kept in differential diagnosis of cystic lesions. Various imaging findings are characteristic to diagnosed CL pre operatively. As standard protocol USG examination followed by MRI/CT examination used for proper evaluation in suspicious case of CL. Surgery is the mainstay of treatment if suitable.

Financial support and sponsorship - Nil

Conflicts of Interest -There are no conflicts of interest.

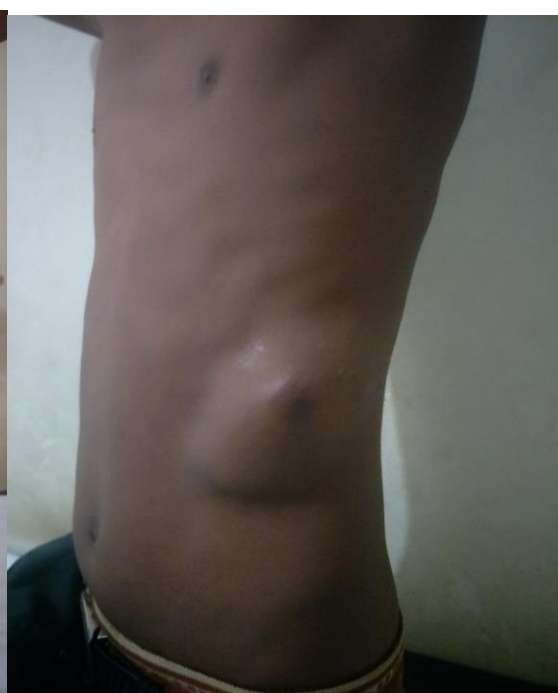References

- [1]. Norio Yokoigawa et al, cystic Lymphangioma of the Chest Wall: A Case Report. *Case Reports in Gastroenterology* 2014;8: 393-397.
- [2]. Dimitrios Patoulis et al. Cystic Lymphangioma of the Chest Wall in a 5- Year-old Male Patient: A Rare and Atypical Localization- A Case Report and Comprehensive Review of the Literature. *Case Reports in Pediatrics*, Volume 2017, Article ID 2083204, 6 pages.
- [3]. In Kyeom Kim et al. Cystic Lymphangioma of the Abdominal Wall in childhood: A Report of Two Cases Focused on Radiological Findings. *Iran J Radiol.* 2017 April;14(2):e40549.
- [4]. Panditt SK et al. Cystic lymphangioma with special reference to rare sites, *Indian J Pediatr*; 2000; 67:339-41. PMID:10885205
- [5]. Karthigesu Aimanan et al. Case report of chest wall cystic hygroma in a teenager. *Med J Malaysia* Vol.71, No.5 .October 2016.
- [6]. Snehanu Pan .A rare site of Cystic Hygroma. *IOSR Journal of dental and Medical Scinces (IOSR-JDMS0*. Volume 14, Issue 11. Ver. VI (Nov.2015). PP10-11.
- [7]. Ammar S et al Cystic lymphangioma of the rectus abdominis muscle: an extremely rare clinical entity. *Iran J Pediatr.* 2014;24(5):662-3. [PubMed:25793081].
- [8]. Riahinerzhadm et al. Two unusual sites of cystic lymphangioma in a child: A report of imaging profile with surgical and histopathologic findings. *Adv. Biomed. Res.* 2015;4:169. doi:10.4103/2277-9175.162546. [PubMed:26436083].
- [9]. Ravi Kapoor et al. Sonographic Appearances of Lymphangiomas. *Indian Pediatrics* Volume :31, November 1994: Page 1447-1450.
- [10]. Lal A et al. Abdominal lymphatic malformation: Spectrum of imaging findings. *Indian J Radiol Imaging* . Year :2016 I Volume:26 I issue:4I Page:423-428.
- [11]. Arora A et al Cystic hygroma of chest wall. *Indian J Radiol Imaging* [serial online] 2003 [cited 2019 Sep 28]; 13:120-1.
- [12]. Sandeep K Rahul et al . Unusal Site for Cystic Hygroma: A Single Centre Experience. *Journal of Cutaneous and Aesthetic Surgery*- October-December 2016, Volume 9, Issue4. WWW.jcasonline.com
- [13]. Tran Ngoc n et al. Cystic hygroma in children: A report of 126 cases. *J Pediatr. Surg.* 1974;9(2):191-5. doi:10.1016/S0023-3468(74)80120-X [PubMed:4825790].



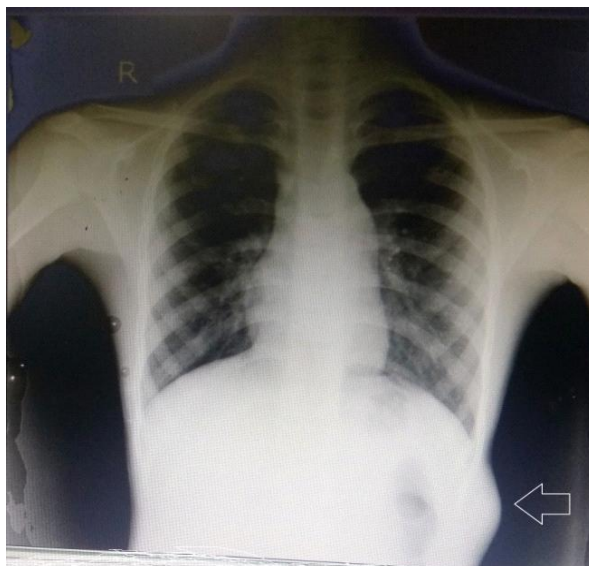
Swelling in left upper abdominal wall.

Figure 1

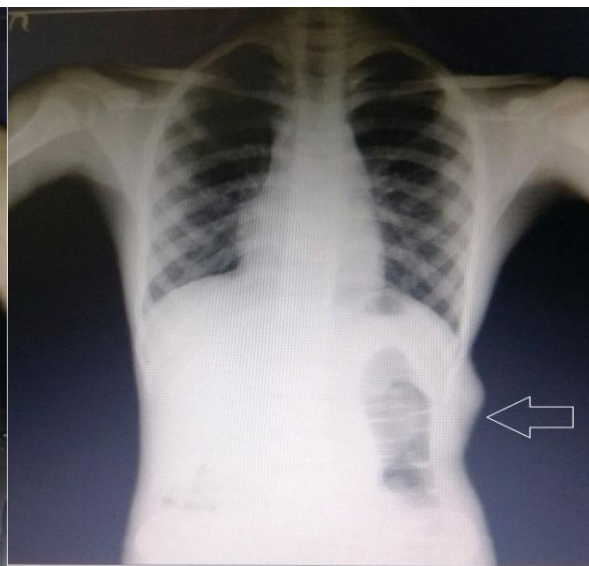


Swelling in left upper abdominal wall.

Figure 2



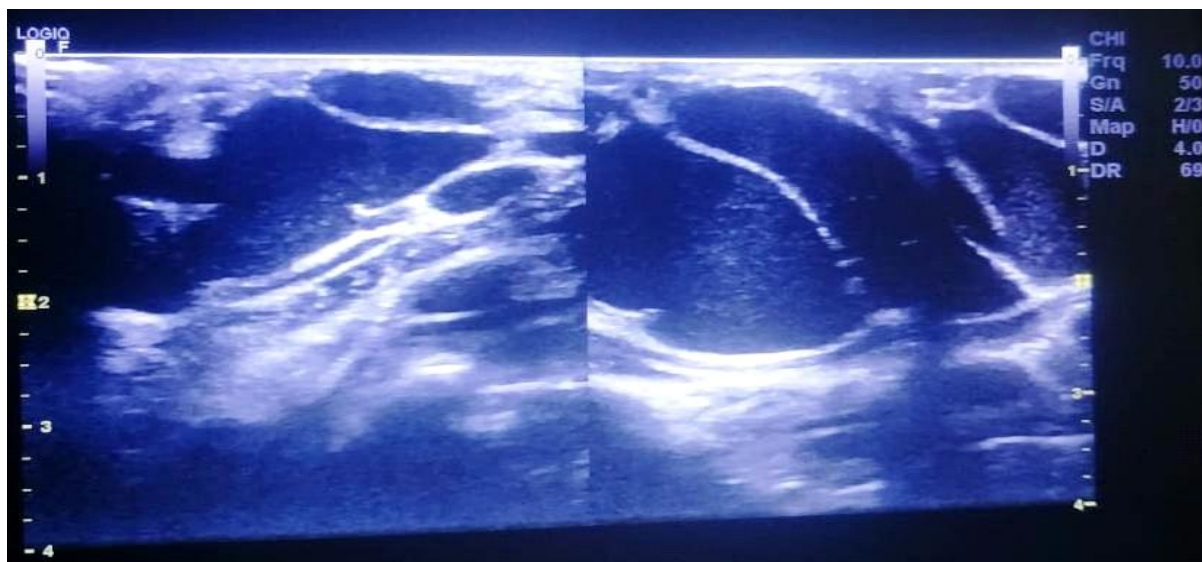
Radiograph- Soft tissue swelling over left upper lateral abdominal wall.(arrow)



Radiograph- Soft tissue swelling over left upper lateral abdominal wall.(arrow)

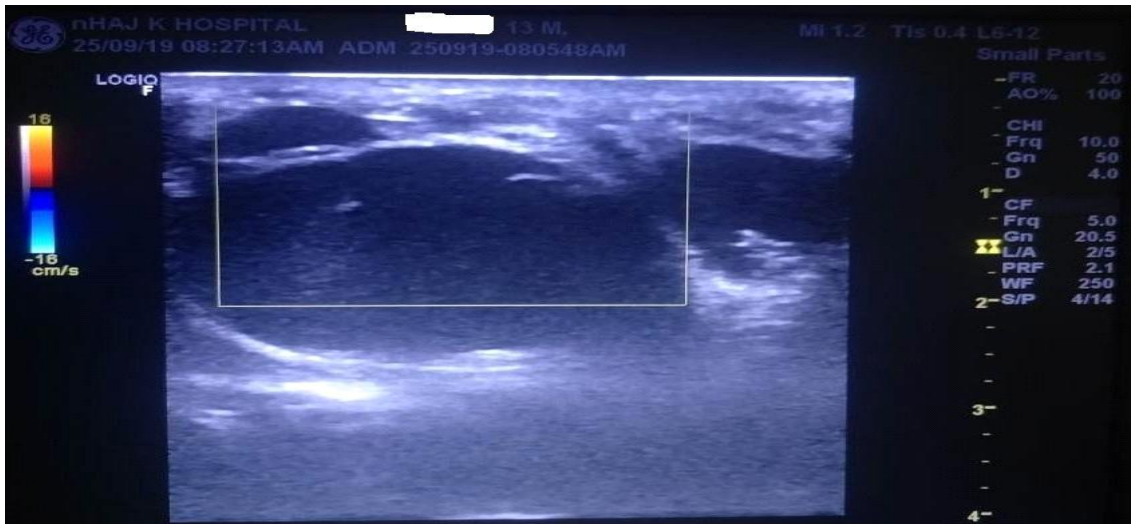Figure 3

Figure 4



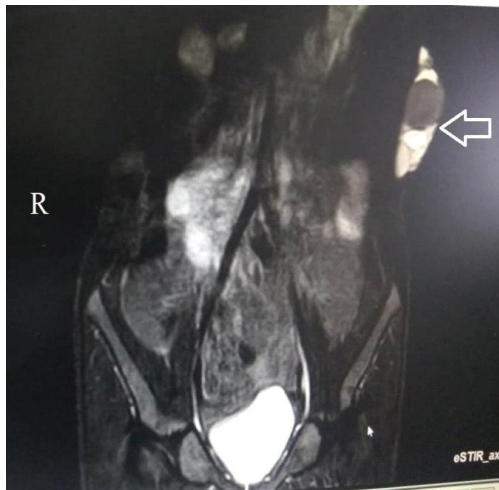
Multiloculated cystic lesion with septae in left upper lateral abdominal wall.

Figure 5



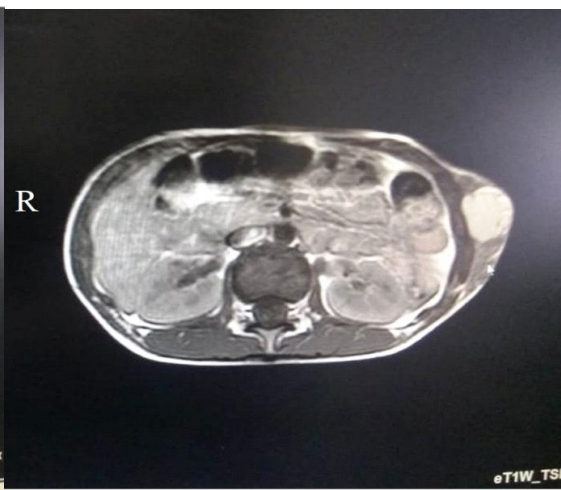Multiloculated cystic lesion with septae in left abdominal wall.No vascularity on color doppler.

Figure 6



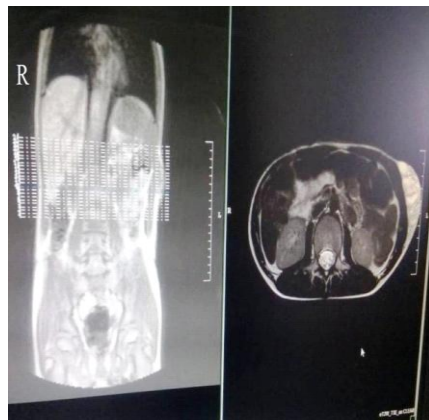Coronal and saggital MR images- Hyperintense lesion with fluid component.

Figure 7



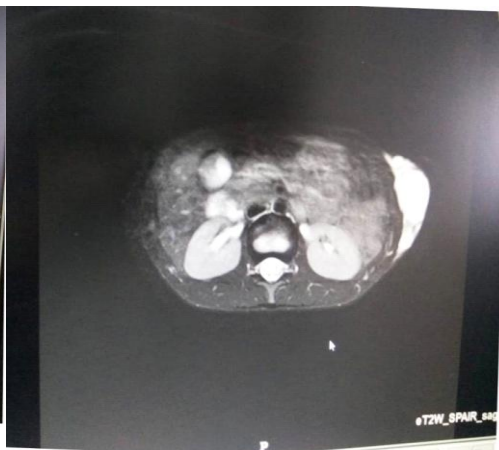Coronal and saggital MR images- Hyperintense lesion with fluid component.

figure 8



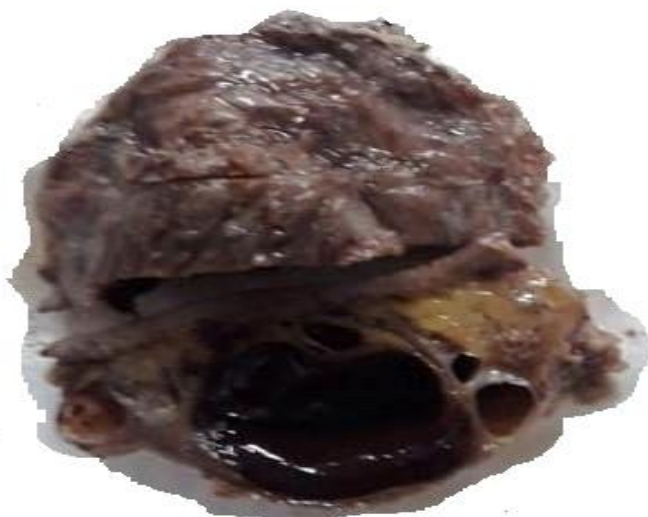Coronal and saggital MR images- Hyperintense lesion with fluid component.

Figure 9



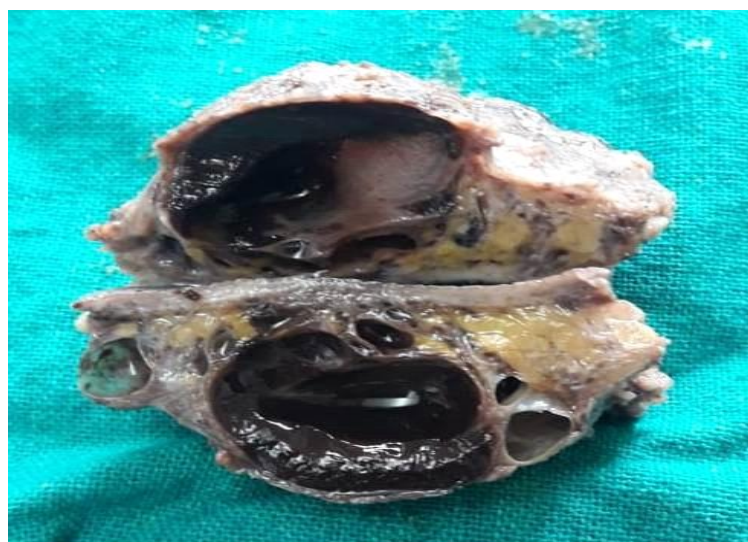
Coronal and saggital MR images-Hyperintense lesion with fluid component.

Figure 10



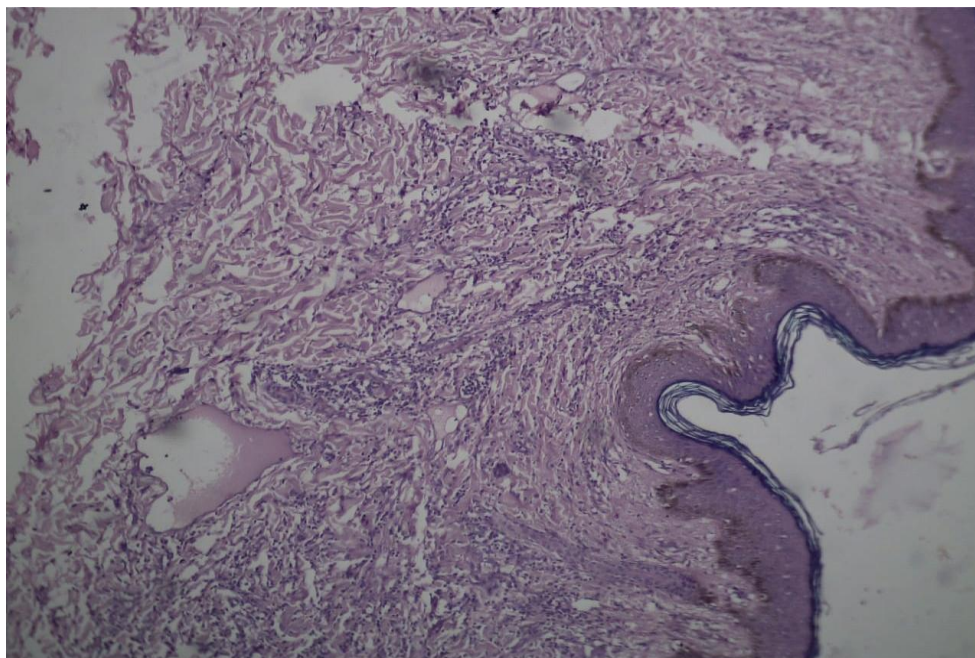
Excised specimen of cystic lymphangioma from abdominal wall showing cysts with septae.

Figure 11



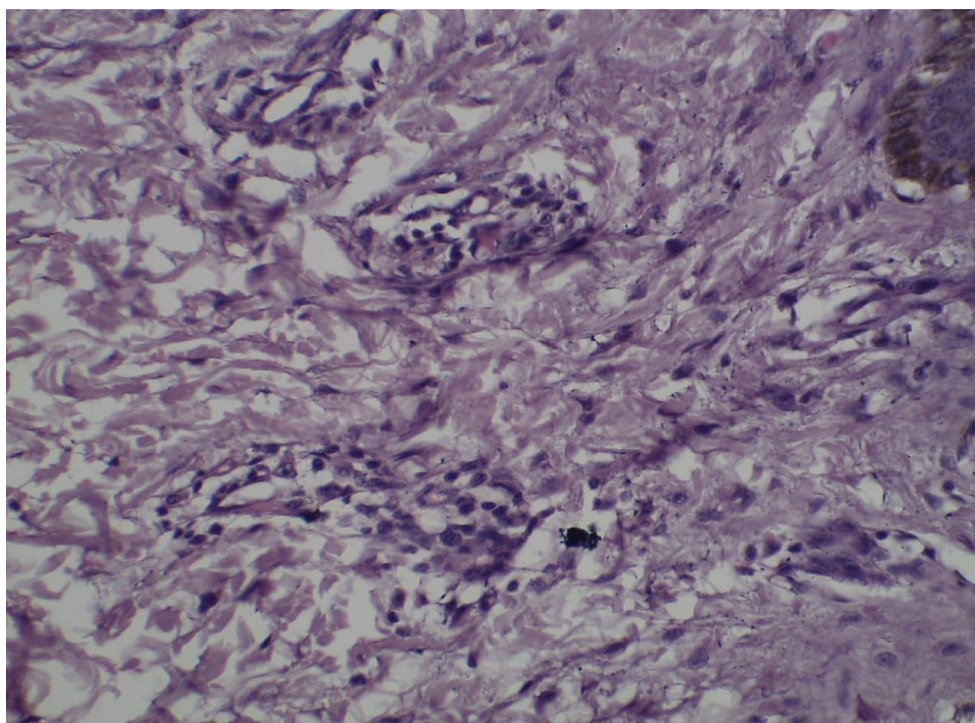
Excised specimen of cystic lymphangioma from abdominal wall showing cysts with septae.

Figure 12



HP S/O- Cystic Lymphangioma

Figure 13



HP S/O- Cystic Lymphangioma

Figure 14

Dr Pranav K Dave. "Cystic Lymphangioma of Abdominal Wall in a Child, a Rare Site."
IOSR Journal of Dental and Medical Sciences (IOSR-JDMS), vol. 18, no. 10, 2019, pp 57-63.