

# **Undetected Portal Cavernoma Encountered During Laparoscopic Cholecystectomy**

**Gupta M S**

*Corresponding Author: Gupta M S*

---

Date of Submission: 21-09-2019

Date of Acceptance: 10-10-2019

---

## **I. Introduction**

Portal cavernoma, also called cavernous transformation of the portal vein, consists of a network of venous channels, which replaces a previously stenosed or occluded portal vein.

Portal cavernomacholangiopathy (PCC) is defined as abnormalities in the extrahepatic biliary system including the cystic duct and gallbladder with or without abnormalities in the 1st and 2nd generation biliary ducts in a patient with portal cavernoma. For the diagnosis of PCC to be established, the following criteria should be fulfilled - presence of a portal cavernoma, typical cholangiographic changes on ERC or MRCP and absence of other causes of these biliary changes like bile duct injury, primary sclerosing cholangitis, cholangiocarcinoma etc (1). PCC manifests as biliary pain, jaundice, cholestasis or cholangitis along with derangement of liver functions (2).

Evidence suggests that Gallstones are more than two times common in portal hypertension patients either cirrhotic or non cirrhotic(3). It has been reported that laparoscopic cholecystectomy can be safely performed in cirrhotic patients, within Child-Pugh classes A and B, with acceptable morbidity and conversion rate (4). However there have been fewer cases associated with Extra Hepatic Portal Venous Obstruction and cavernomas who have been reported to have undergone laparoscopic cholecystectomy

## **II. Case Report**

We encountered a 32 year old female who presented to our emergency with history of pain upper abdomen for 2 days without jaundice or upper GI bleed. Physical examination revealed tender epigastrium, with no other positive finding. On investigating, she was found to have a single mobile gall stone. The CBD and Gall Bladder wall thickness was normal. No other abnormality was reported on USG.

The patient was posted for laparoscopic cholecystectomy. We used a standard four port approach. The gall bladder was overdistended. To ensure adequate exposure aspiration was carried out. Dense adhesions were encountered around the neck of the GB. On further progression a large tortuous venous malformation was noted around the callot's triangle (Fig 1). Dissection was tried for some time, but the callot's anatomy could not be defined. A decision to convert was taken and open cholecystectomy was done. Post Operative period was uneventful and the patient was later attached to Gastroenterology unit for further management.

## **III. Discussion**

The presence of gall stones in the presence of portal cavernoma has been discussed on numerous occasions; however there is little discussion in the literature about laparoscopic cholecystectomy in these patients. Few authors have reported successful laparoscopic cholecystectomy in patients in whom the condition was diagnosed pre-operatively (5,6). Incidental detection of on portal cavernoma during laparoscopic cholecystectomy has not been discussed much in the literature.

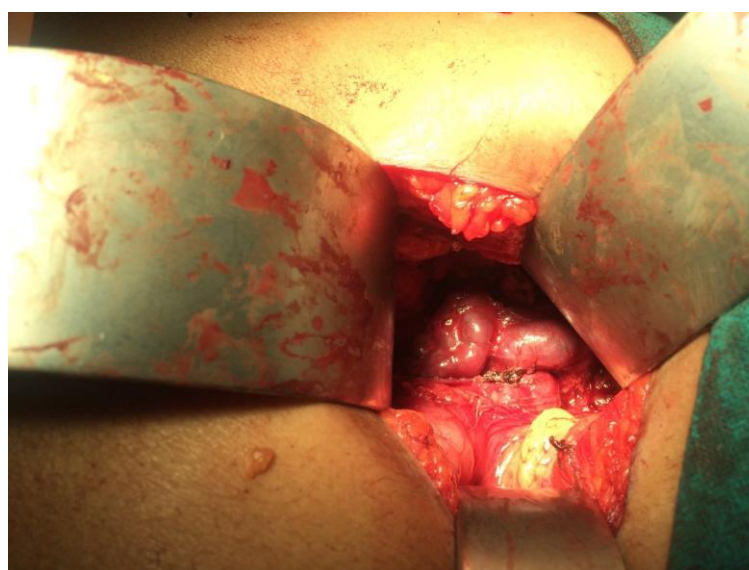
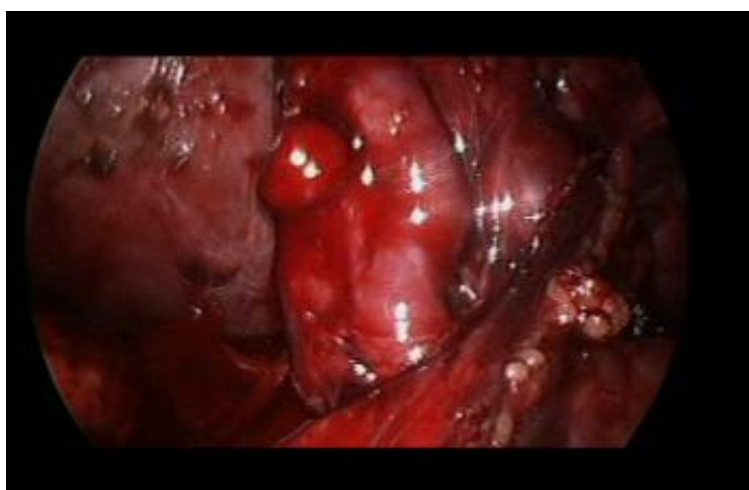
A portal cavernoma significantly obscures the anatomy of the callot's triangle. It may also cause profuse bleeding leading to morbidity and even mortality. Venous hemorrhage during cholecystectomy due to involvement of the gall bladder by venous collaterals is also well known(7). It is suggested that optimal pre-operative preparation and a cautious surgical strategy be used for avoiding such complications.

Ultrasonography has been acknowledged as a good screening modality for picking up a portal cavernoma. However a triple phase CT or an MRA needs to be done in order to chalk out a surgical plan. CT demonstrates biliary and vascular changes, however MRCP with MR portography is the current gold standard as it helps delineate biliary and CBD architecture better.

Our case is unique as here the portal cavernoma was missed on USG and was seen only during laparoscopy. Having to deal with such an entity unprepared can lead to complications like severe bleeding and even mortality. It is better to convert to open surgery in the presence of such anomalies.

### References

- [1]. Radha K. Dhiman, Vivek A. Saraswat; Portal CavernomaCholangiopathy: Consensus Statement of a Working Party of the Indian National Association for Study of the Liver; J ClinExpHepatol. 2014 Feb; 4(Suppl 1): S2–S14.
- [2]. Kumar M, Saraswat V; Natural History of Portal CavernomaCholangiopathy; Journal of clinical and experimaentalhepatologyFebruary 2014Volume 4, Supplement 1, Pages S62–S66 x
- [3]. Sarin SK, Guptan RC, Malhotra S. Increased frequency of gallstones in cirrhotic and non-cirrhotic portal hypertension.J Assoc Physicians India. 2002 Apr;50:518-22.
- [4]. Machado NO. Laparoscopic cholecystectomy in cirrhotics.JSLS. 2012 Jul-Sep;16(3):392-400.
- [5]. Bhatia P, John S, Kalhan S, Khetan M. Primary laparoscopic cholecystectomy in patients with portal cavernoma and non-obstructive portal biliopathy: Two case reports. J Min Access Surg 2014;10:161-2
- [6]. Kalra, Naveen, Shiva Shankar, and NiranjanKhandelwal. “Imaging of Portal CavernomaCholangiopathy.” Journal of Clinical and Experimental Hepatology 4.Suppl 1 (2014): S44–S52. PMC. Web. 29 May 2016.
- [7]. Panda N, Das R, Das S, Bandopadhyay SK, Barman D. Laparoscopic Cholecystectomy in a Patient with Portal Cavernoma. Journal of Surgery [Jurnalul de chirurgie] 2015; 10(4): 315-316.
- [8]. Palanivelu C, Rajan PS, Jani K, Shetty AR, Sendhilkumar K, Senthilnathan P, et al. Laparoscopic cholecystectomy in cirrhotic patients: The role of subtotal cholecystectomy and its variants. J Am CollSurg 2006;203:145-51.



Gupta M S. “Undetected Portal Cavernoma Encountered During Laparoscopic Cholecystectomy”. IOSR Journal of Dental and Medical Sciences (IOSR-JDMS), vol. 18, no. 10, 2019, pp 79-80.