

A Rare Case Report of Triple X syndrome associated with depressed nasal bridge and sandal gap

Leelavathy N, Sudeep Nagaraj

(Department of Anatomy, Sapthagiri Institute of Medical Sciences and Research Center, Bengaluru, India)

Abstract: Triple X syndrome, 47,XXX is a sex chromosome abnormality characterized by presence of an extra X chromosome. Usually a neonate diagnosed with triple XXX is very rare since there are no signs and symptoms. In the present case a three day old female baby with depressed nasal bridge and sandal gap features was confirmed with 47,XXX.

Keywords: Depressed nasal bridge, Sandal gap, Super female, Triple X syndrome, 47,XXX

Date of Submission: 24-09-2019

Date of Acceptance: 12-10-2019

I. Introduction

The X chromosome is one of the largest chromosomes and contains hundreds of genes most of which have nothing to do with sex determination. At birth it is very difficult to diagnose triple X syndrome since there will be no signs and symptoms. However, the incidence is 1 in 1000 normal females, but it might be on higher side since most of the cases are undiagnosed [1,2]. Triple X syndrome results from non disjunction of X chromosome during meiotic division. The risk, as in other aneuploidies (Down syndrome, Turner syndrome, Klinefelter syndrome, Edward syndrome, Patau syndrome) increases if mother's age is more than 35 years. The extra X chromosome is very rarely of paternal origin. The common signs and symptoms include delayed development of speech and language skills, as well as motor skills, learning disabilities such as difficulty with reading (dyslexia), understanding or math, behavioral problems such as attention-deficit / hyperactivity disorder (ADHD) or symptoms of autism spectrum disorder, psychological problems such as anxiety and depression, problems with memory, judgment and information processing. Rarely it has been reported about vertical folds of skin that cover the inner corners of the eyes (epicanthal folds), widely spaced eyes, abnormally curved pinky fingers, flat feet, abnormally shaped breastbone, weak muscle tone (hypotonia), seizures, kidney abnormalities, premature ovarian failure or ovary abnormalities, sandal gap, myopia, cleft lip and palate, dental abnormalities, hydramnios, primary amenorrhea with socially acceptable intelligence [3,4,5,6,7,8].

II. Case Report

A three days old female baby was referred to Human Genetics Lab, Sapthagiri Institute of Medical Sciences and Research Centre, Bengaluru, for karyotyping due to depressed nasal bridge and sandal gap. She was the only live born child for the couple with three miscarriages and 4th pregnancy was medically terminated at 5th month due to hydrocephalus. The neonate was a term baby and on examination she had a female phenotype with lower mean birth weight of 2.66 kg. The hormonal study resulted in normal levels of total bilirubin, direct bilirubin, c-reactive protein (CRP), S. Sodium.

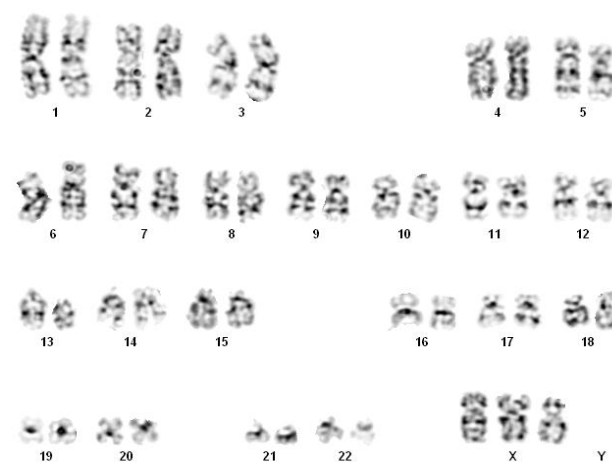


Figure 1: Karyotype showing triple X.

Cytogenetic investigations included modified leucocyte microculture, Giemsa-Trypsin-Geimsa (GTG) banding and karyotyping. 15 metaphase spreads were analysed which revealed 47,XXX chromosomes in all spreads (Fig. 1).

III. Discussion

Majority of the individuals with triple X syndrome may go unnoticed and undiagnosed due to the normal phenotype, socially acceptable intelligence, and normal sexual development and fertility even though they have several other problems like low IQ and cognitive functions. Only few will have physical abnormalities. Their performance in the school might not be to the level of their peer groups since there might be delay in language development, reading impairment, poor arithmetic performance and verbal comprehension and reasoning. There might be chances of getting socially isolated due to problems in psychosocial adaptations [3,6].

Individuals with triple X might have delayed puberty and or early menopause. They might also have reproductive problems [9,10] and those who are associated with autoimmune thyroid disorders may have complications in pregnancies leading to premature births and malformation [11].

Most of the cases are diagnosed during the referral for amenorrhea, fertility problems, and premature ovarian failure. But diagnoses of triple X syndrome in infants are very rare. One of the studies by Jagadeesh showed the sandal gap as one of the feature in the infant which was observed in the present case also. Along with this feature in the present case depressed nasal bridge also was associated. Early detection and treatment are very beneficial for girls with XXX. They might have fewer issues later in life with early detection and appropriate treatment.

IV. Conclusion

In the present case report the proband is a neonate at the time of referral. The pediatrician and parents can observe the child for the language, neuromotor, learning and behavioral skills during her development. Accordingly the parents have to be counseled. Early diagnosis might help the child to be near to normal during the schooling and later in life. Pediatricians, obstetricians and gynecologists should be aware that they have to refer the female neonates with depressed nasal bridge and sandal gap for cytogenetic investigations. There might not be possible association of XXX with depressed nasal bridge and sandal gap, but if confirmed through karyotype it might help the parents in upbringing of the child.

References

- [1] KH Gustavson, Triple X syndrome deviation with mild symptoms. The majority goes undiagnosed, *Lakartidningen*, 96, 1999, 5646-5647.
- [2] M Otter, CT Schrandt-Stumpel, LM Curfs, Triple X syndrome: A review of the literature, *Eur J of Hum Gen*, 18, 2010, 265-271.
- [3] J Rovet, C Nestley, J Bailey, M Keenan, D Stewart, Intelligence and achievement in children with extra X aneuploidy: A longitudinal perspective, *Am J Med Genet*, 60, 1995, 356-63.
- [4] Jagadeesh, Triple X syndrome with rare phenotype presentation, *Indian Journal of Pediatrics*, 75, 2008, 629-31.
- [5] NR Tartaglia, S Howell, A Sutherland, R Wilson, L Wilson, A review of trisomy X (47,XXX), *Orphanet Journal of Rare Diseases*, 5, 2010, 8. doi: 10.1186/1750-1172-5-8
- [6] Anjum Afshan, Triple X syndrome, *J Pak Med Assoc*, 62(4), 2012, 392-394.
- [7] E Gurkas, HM Genc, E Kilic, Triple X Syndrome with a rare finding: Cleft Palate, *J Pediatr Res*, 5(2), 2018, 100-102
- [8] T Nishi, N Ogata, High Myopia Associated with Triple X Syndrome, *Neuro-Ophthalmology*, 40(3), 2016, 136-138
- [9] R Harmon, B Bender, M Linden, A Robinson, Transition from adolescence to early adulthood: Adaptation and psychiatric status of women with 47, XXX. *J Am Acad Child Adolesc Psychiatry*, 37, 1998, 286-91.
- [10] BG Bender, RJ Harmon, MG Linden, B Bucher-bartelson, A Robinson, Psychosocial Competence of unselected young adults with sex chromosome abnormalities, *Am J Med Genet*, 88, 1999, 200-6
- [11] R Goswami, D Goswami, M Kabra, N Gupta, S Dubey, Prevalence of the triple X syndrome in phenotypically normal women with premature ovarian failure and its association with auto-immune thyroid disorders, *FertilSteril*, 80, 2003, 1052-4

Leelavathy N. "A Rare Case Report of Triple X syndrome associated with depressed nasal bridge and sandal gap." *IOSR Journal of Dental and Medical Sciences (IOSR-JDMS)*, vol. 18, no. 10, 2019, pp 23-24.