

Modified Bleach Method - An Edge over Conventional Ziehl Nielsen Staining For the Diagnosis of Acid Fast Bacilli in Tuberculous lymphadenopathy in Paediatric Population

Ravi Rani¹, S. Manazir ali²

¹Ravi Rani, Department of pathology, Motilal Nehru Medical college, KGMU, India

²Syed Manazir Ali, Department of Paediatrics Jawaharlal Nehru Medical college, AMU, India

Corresponding Author: Ravi Rani

Abstract: The aim of this study was early and accurate diagnosis of tuberculosis in lymph node. Fine needle aspiration cytology by Modified bleach method. A total of 237 cases of cervical lymphadenopathy were taken into account. The acid-fast bacilli positivity by routine staining was compared with modified bleach methods of Ziehl Nielsen staining. The routine Ziehl Nielsen staining detected acid fast bacilli in 97 (40.9%) of cases and the modified bleach method in 159 (67.08%). Modified bleach method showed acid fast bacilli positivity in additional 62 cases where routine Ziehl Nielsen staining was negative. The modified bleach method was more effective and safer than routine Ziehl Nielsen staining.

Date of Submission: 23-09-2019

Date of Acceptance: 12-10-2019

I. Introduction

Tuberculosis (TB) is an important cause of morbidity and mortality in children worldwide, especially in developing countries [1]. Children carry a great burden of disease. They are more likely to develop extrapulmonary and severe disseminated disease than adults. [2]. Diagnosis of TB in children is based on clinical examination and investigations that include complete Hematogram, Chest radiograph, Mantoux test, Fine needle aspiration cytology (FNAC), culture and advanced diagnostic methods like Polymerase chain reaction (PCR) [3]. Conventional culture of Mycobacteria is sensitive but time-consuming investigation which takes around 6 to 8 weeks for results. Recent diagnostic technique like PCR is accurate but costly [4]. Although conventional Ziehl Nielsen (ZN) stain is most commonly used to detect acid fast bacilli, it is limited by its low efficacy. [5]. Modified bleach method of lymph node aspirate significantly improves microscopic detection of acid-fast bacilli (AFB). [6].

II. Materials And Methods

This prospective study was carried out on patients of Department of Paediatrics at Jawahar Lal Nehru medical college Aligarh, India from June 2012 to June 2014. A total of 237 patients (both male and female) aged <14 years were included in the study.

Study design: Prospective study

Study Location: This was a tertiary care teaching hospital-based study done in Department of Pathology, at Jawahar Lal Nehru Medical College, Aligarh, Uttar Pradesh.

Study Duration: June 2012 to June 2015

Sample size: 237 patients.

Subjects & selection method: The study population was drawn from children presenting with cervical lymphadenopathy.

Inclusion criteria:

- 1-Patients of tubercular lymphadenopathy
- 2-Paediatric age group
- 3- Either sex

Exclusion criteria:

1-Patient already on antitubercular (ATT) drugs for more than 3 months.

A total of 237 patients were included. FNAC was done by 25-27 gauge needle and 10 ml syringe. All the lymphnode aspirates were processed for routine cytology, conventional ZN stain and modified bleach method. Fine needle aspiration of cervical lymph node was performed, 5 to 6 smears were made and stained with Hematoxylin(H&E), Papanicolaou(PAP) and ZN stain as per routine procedure. The residual aspirated material in the needle was flushed out and subjected to liquefaction with 2 ml of 5% sodium hypochlorite solution in a test tube at room temperature for 30 minutes. The aspirated material along with the bleach solution was then centrifuged for 15 minutes at 3000 round per minute. The supernatant was discarded and smears were made from the sediment on clean glass slides, followed by ZN staining. The slides were mounted and screened under oil immersion lens. As a control, ZN staining was done on 2 ml of distilled water to rule out any error due to contamination.

III. Result

The present study was conducted on 237 patients of Paediatric age group. There were 132 (56%) females and 105 (44%) males in the study group. Maximum number of cases on FNAC were of tuberculous lymphadenopathy 171 cases (72.1%), followed by 53 cases (22.3%) of reactive lymphadenopathy, 11 cases (4.6%) of abscess and 2 cases (0.8%) of lymphoproliferative disease. ZN stain and modified bleach technique were applied on all 237 cases. The cytological diagnosis of reactive lymphadenopathy was based on morphology showing mixed population of lymphoid cells showing centrocyte, centroblast, immunoblast and tingible body macrophages. Out of 53/237 cases diagnosed as reactive lymphadenitis, modified bleach method showed positivity in 12/53 cases while all the cases were negative by the conventional ZN stain. Pyogenic abscess were diagnosed on FNAC showing lymphocytes and polymorphs in the background of necrosis. Modified bleach yielded positivity in 5/11 cases while ZN stain was positive in 1/11 case. On FNAC tuberculosis was diagnosed on the basis of showing Epithelioid granuloma with or without caseous necrosis or cases only with caseous necrosis and degenerated polymorphs. Among 171 cases of tubercular lymphadenitis ZN stain was positive in 97(40.9%) cases while modified bleach turned out to be positive in 159(67.1%) cases. On FNAC lymphoproliferative disease were diagnosed on the basis of monotonous population of lymphoid cells with coarse chromatin, prominent nucleoli and atypical mitosis. Both modified bleach and ZN stain turned out to be negative in these cases.

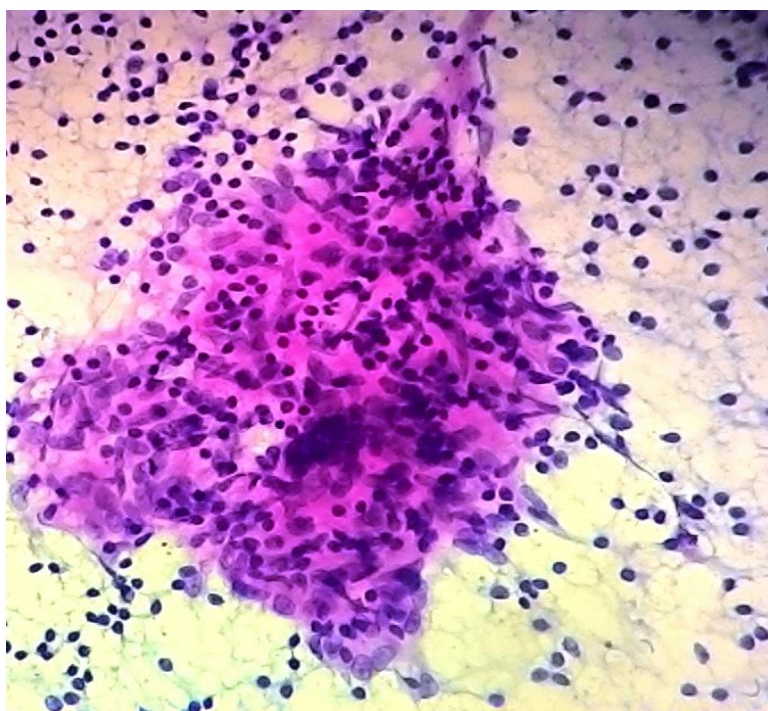


Fig 1: TB Lymph Node showing epithelioid granuloma with necrosis (H&E:40X)

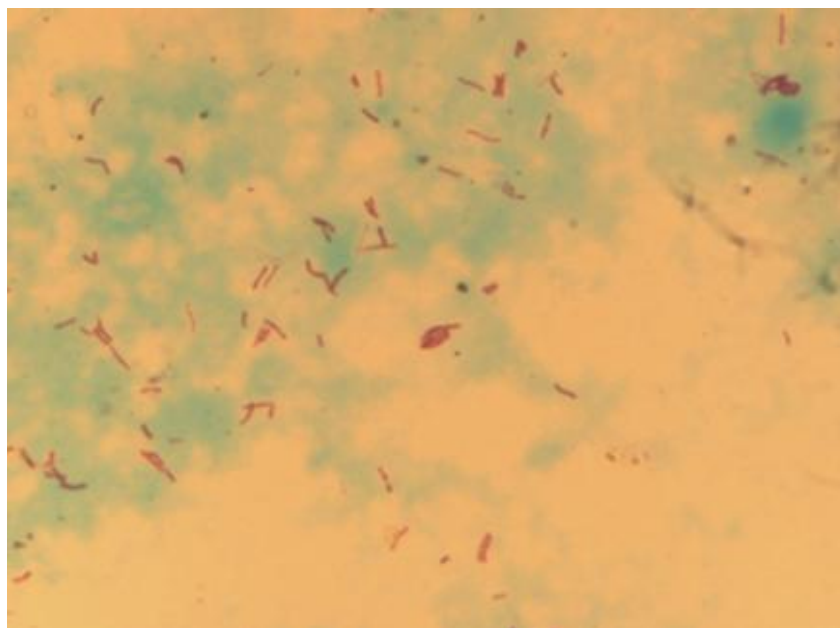


Fig 2: smear showing red acid-fast bacilli against green background(Modified bleach method: 100X)

Cytomorphological diagnosis	FNAC	AFB positive on Modified bleach	AFB positive on ZN stain
TB lymphadenitis	171	159	97
Reactive lymph node	53	12	0
Pyogenic abscess	11	05	01
Lymphoproliferative disease	02	0	0

Table1- Cytomorphological correlation of modified bleach and ZN stain

IV. Discussion

Conventionally ZN staining is most widely used staining technique for demonstration of acid fast bacilli in various samples. To augment the low sensitivity of ZN staining, concentration methods like modified bleach technique is being used to improve the diagnosis of tuberculosis.[7]Bleach apart from being a good disinfectant, concentrate and preserve the morphology of acid fast bacilli so it complements the early diagnosis and treatment of tuberculosis.[8]In the present study ZN staining detected AFB in 40.9% cases while modified bleach technique has detected acid fast bacilli in 67.1% of cases. The present study was compared with the following similar studies done on modified bleach technique.

Study	Detection of AFB by ZN stain	Detection of AFB by modified bleach method
Present study	40.9%	67.1%
Singh P et al 2015	40%	63.5%
Patel et al 2013	27.8%	61.7%
Dwivedi et al 2013(9)	35.5%	68%
Chandrasekhar et(10) al 2012	12.5%	60.7%
Annam et al 2009(11)	33.3%	63.4%
Gangane et al (2008)[8]	27%	72%
Khubnani et al(2005)[12]	21.8%	70.9%

Table 2: Comparison of other similar studies to the present study

The present study was comparable to the results of Dwivedi et al (2013)where modified bleach technique detected AFB in 68% of cases. The results in present study was higher than the studies done by Singh P et al (2015), Patel et al (2013),Chandrasekhar et al (2012) and Annam V et al (2009). Higher rate of AFB detection by bleach method could be explained by increased sedimentation of AFB due to change in the surface properties of the bacteria and denaturation of specimen.However results of modified bleach in the present study were found to be lower than the studies done by Gangane et al (2008) and Khubnani et al (2005). This difference in various studies could be attributed to the variable bacillary load in the sample apart from the difference in the expertise of the technique.

As bleach is a disinfectant, optimal results are obtained only when the method is to be used within one hour of a specimen collection.[11]Bleach method detected AFB in 159/237(67.1%) cases of reactive lymphadenitis on cytology.This is explained by the masking of scattered epithelioid cells amidst the

polymorphous population of lymphoid cells. [14] Thus, granulomas could be missed in these cases. Furthermore, ZN stain could not detect bacilli in any case which was diagnosed as reactive on cytology smears. Thus, bleach method could be of immense utility in such cases.

Out of 11/237 specimen diagnosed as suppurative lymphadenitis, 05/11 cases were positive by conventional ZN method while bleach method yielded positivity in 01/11 cases, the reason may be loss of the bacilli among the debris.

Makaen et al(2014)[14] emphasized on the role of bactericidal properties of bleach method which helps in containing the spread of infection along with better detection of acid fast bacilli

Thus modified bleach technique is:

- A sensitive method to detect AFB than routine ZN staining.
- Rapid method as morphology of AFB is better appreciated
- Safer method, owing to the bactericidal property of bleach

V. Conclusion

A thorough clinical assessment along with relevant investigations is required for early and precise diagnosis of TB. Fine needle aspiration supplemented with modified bleach technique is an effective and cost efficient tool in the work up of suspected case of tubercular lymphadenopathy especially in TB endemic country like india. Therefore implementation of bleach method is an important contribution in the management of tuberculosis which ensures early and effective treatment of the patients.

References

- [1]. Shah K Abhay, Shah A Ashay. Diagnosis of Childhood Tuberculosis. Pediatric Infectious Disease. 2019; 1(1):8.
- [2]. Dawani A, Gupta A, Imaging in Paediatric Extrapulmonary Tuberculosis. The Indian journal of Pediatrics. 2019; 86(5):459-467.
- [3]. D Aygun, N Akcakaya. Evaluation of Clinical and Laboratory Characteristic of Children with Pulmonary and Extrapulmonary Tuberculosis. Medicinia. 2019; 55(8):428.
- [4]. S Manali, B Ullas. PCR in tuberculosis: An extremely useful tool?. 2018; 4(2):60-63.
- [5]. A Gehan Mohammed, A seed Ahmed Mohammed. Comparison of the Microwave -Heated ziehl-Neelsen Stain and Conventional Ziehl Neelsen Method in the Detection of Acid Fast Bacilli in Lymph Node Biopsies. Open Access Maced J Med Sci. 2019; 7(6):903-907.
- [6]. Singh P, Rathi M, Verma N, Singh N, Tapparwal V. Modified bleach method for detection of acid fast bacilli in lymph node aspirates and its comparison with the conventional Ziehl-Neelsen stain. Int J Adv Med Health Res 2015; (2): 83-6.
- [7]. Patel MM, Patel KK, Italiya SL. Improved diagnosis of tuberculosis in lymph node cytology by bleach method for detection of acid fast bacilli in comparison to conventional ziehl neelsen staining method. Int J Med Sci Public Health. 2013; 2(4): 935-939.
- [8]. Gangane N, Anshu, Singh R. Role of modified bleach method in staining of acid-fast bacilli in lymph node aspiration. Acta Cytol. 2008; 52: 325-328.
- [9]. Dwivedi G and Mathur C. Modified Bleach Method – Improving Microscopic Detection of Acid Fast Bacilli in Fine Needle Aspiration Smears of Lymph Nodes. Journal of Medical Science and Clinical Research. 2013; 1(4):176-183.
- [10]. Chandrasekhar B, Prayaga AK. Utility of concentration method by modified bleach technique for the demonstration of acid-fast bacilli in the diagnosis of tuberculous lymphadenopathy. J Cytol 2012; 29:165-8.
- [11]. Annam V, Karigoudar MH, Yelikar BR. Improved microscopical detection of acid-fast bacilli by the modified bleach method in lymph node aspirates. Indian J. Pathol. Microbiol 2009; 52(3): 349-352.
- [12]. Khubnani H, Munjal K. Application of bleach method in diagnosis of extra-pulmonary tuberculosis. Indian J Pathol Microbiol. 2005 Oct; 48(4):546-50.
- [13]. Satyanarayana S, Kalgthgi AT, Muralidhar A, Prasad RS, Jawed KZ, Trehan A. Fine needle aspiration cytology of lymph nodes in HIV infected patients. Med J Armed Force India 2002; 58:33-7.
- [14]. Makaen J, Maure T. Bleach processed smear for acid fast bacilli staining in papua new guinea. Lab Med. 2014; 45(4):p140-141.

FIGURES

Figure 1: TB Lymph Node showing epithelioid granuloma with necrosis (H&E:40X)

Figure 2: smear showing red acid fast bacilli against green background (Modified bleach method: 100X)

TABLES

Table 1, Table 2

Ravi Rani. "Modified Bleach Method - An Edge over Conventional Ziehl-Neelsen Staining For the Diagnosis of Acid Fast Bacilli in Tuberculous lymphadenopathy in Paediatric Population." IOSR Journal of Dental and Medical Sciences (IOSR-JDMS), vol. 18, no. 10, 2019, pp 39-42.