

Clinical application of Collum femoris-preserving (CFP) prosthesis in Total Hip Arthroplasty

Hasibul Hasan¹ , Xiong ChuanZhi , Xiao Yi, Yan LianQI , Shan YuZhou ,
Lu ZhiHua , Zhang AiHua

Department of Orthopedic Surgery, Clinical Medical school of Yangzhou University (Northern Jiangsu People's Hospital), Yangzhou 225001, China

Address correspondence to: Dr. Xiong ChuanZhi, Department of orthopedics, Northern Jiangsu people's Hospital, 98 Nantong West Road, Yangzhou 225001, Jiangsu Province, China.

Abstract

Objective: To retrospectively analyze and compare the clinical application of CFP prosthesis and traditional straight handle prosthesis in total hip arthroplasty.

Methods: From February 2013 to April 2015, patients who underwent THA with CFP prosthesis and traditional prosthesis and had perfect clinical and imaging data were followed up. There were 33 CFP prostheses with an average age of 54.2 ± 8.7 years. Thirty-two cases of traditional prosthesis were treated with an average age of 55.3 ± 9.0 years. The patients were followed up by Harris Hip Score (HHS) and Western Ontario and McMaster University Osteoarthritis Index (WOMAC). The imaging findings and the incidence of complications were routinely followed up.

Result: There was significant difference in WOMAC score between CFP group and traditional group after 1 year follow-up ($P < 0.001$). At the last follow-up, the HHS score of CFP group was significantly different from that of traditional group ($P=0.04$). During other follow-up periods, there was no significant difference in HHS score and WOMAC score between the two groups. There was no significant difference in the incidence of complications between the two groups. There were significant differences in blood loss and hemoglobin change between CFP group and traditional straight handle group. The survival rates of CFP group and traditional straight stem group were 100% and 96.8% respectively.

Conclusion: Both CFP prosthesis and traditional straight handle prosthesis can significantly improve hip joint function. There is no significant difference between the two groups in terms of postoperative efficacy and complication rate.

Key words: total hip replacement; femoral neck preservation; hip joint

Date of Submission: 04-10-2019

Date of Acceptance: 21-10-2019

I. Introduction

The femoral neck is the strongest bone structure in the proximal femur. The femoral neck retains the trabecular system of the cancellous bone in the metaphyseal end, which makes the stress distribution in the proximal femur more uniform. The CFP prosthesis retains part of the femoral neck bone mass, which will provide sufficient bone mass for future revision surgery, while protecting the proximal femoral blood supply and ensuring the growth of the femoral neck [1,2]. Although most reports in recent years confirm the efficacy and survival rate of CFP prosthesis and traditional straight handle prosthesis, up to now, there is no standardized data to compare the clinical effect, complication rate and survival rate of CFP prosthesis and traditional straight handle prosthesis. In order to solve these problems, this study used CFP prosthesis. Patients with prosthesis and traditional prosthesis were retrospectively analyzed.

II. Materials And Methods

2.1 Clinical data

General Information Patients who underwent THA with CFP prosthesis and traditional prosthesis and who had complete clinical and imaging data from February 2013 to April 2015 in Jiangsu Subei People's Hospital were followed up. A total of 65 cases, 33 males and 32 females. All patients were divided into two groups according to the type of prosthesis. There were 33 patients in the CFP prosthesis group, 16 males and 17 females with an average age of 54.9 years. There were 32 patients in the traditional prosthesis group, 13 males and 19

females with an average age of 55.2 years. There were no significant differences in the general aspects of age, gender, BMI, and disease types between the two groups. The data were comparable (Table 1).

2.2 Prosthesis materials

All surgeries were performed independently by two experienced surgeons. The acetabular screws were placed according to the patient's bone quality. The traditional straight shank prosthesis was from Tianjin Zhengtian Company and the CFP total hip prosthesis was from German Link.

2.3 surgical data

All THAs use the posterolateral approach. Postoperative limbs maintained the external booth, routine antibiotics were used for 3 days, prophylactic use of 6-7 days low molecular weight heparin 3000u anticoagulation, after anesthesia, the patient was guided by the isometric contraction training of the quadriceps muscle, routine use of sputum pump to prevent lower extremity venous thrombosis. On the second day after surgery, the assisted patient walked with weight-bearing part of the walking device. On the 3rd day, the position of the prosthesis was reviewed by X-ray. After 2~4 weeks, the exercise was carried out according to functional exercise and lower limb muscle strength.

2.4 postoperative follow-up

During the hospitalization period, the operation time, the amount of surgical bleeding and the amount of hemoglobin were routinely collected, and the pelvic anterior and posterior hip joint X-ray films were reviewed. At 1 year, 3 years, and the last follow-up, the pelvic anterior film and the lateral articular radiograph of the hip joint were retrospectively reviewed. The imaging data were followed up to the end of the last follow-up. The clinical functional follow-up included preoperative and postoperative 1 year. HNS score, WOMAC score [7, 8] and postoperative complications occurred at 3 years and at the last follow-up. Imaging follow-up evaluation was performed according to the Delee-Charley zoning method and the Gruen zoning method [9, 10] to evaluate the position of the prosthesis, the X-ray changes of the bone and prosthesis interface, and the occurrence of osteolysis [11, 12].

2.5 statistical methods

Statistical data were statistically analyzed using SPSS 19.0 software. The chi-square test is used for the counting data. The measurement data is tested for normality and homogeneity. If the data between the two groups is normal distribution, the independent sample t test is used. If not, the non-parametric test is used (Mann-Whitney U test), $P < 0.05$ was statistically significant.

III. Results

A total of 65 patients who underwent total hip arthroplasty were enrolled, with a mean follow-up of 55 months. As of the last follow-up, a total of 64 patients (65 patients) were followed up, including 33 patients in the CFP group and 31 patients in the traditional prosthesis group. The follow-up rate was 98.4%, and one of them was lost to follow-up due to contact changes (1 in the traditional group). Compared with the perioperative index, the operation time and hemoglobin reduction in the CFP group were significantly lower than those in the traditional group, and the difference was statistically significant. There was no significant difference in the amount of intraoperative blood loss between the two groups.

In both groups, the WOMAC score was significantly lower in the CFP group than in the conventional group ($P < 0.001$). At the last follow-up, the HFS score was higher in the CFP group than in the conventional group ($P=0.04$). There were no significant differences between the two groups in HHS scores and WOMAC scores during the other follow-up periods (Table 2).

Compared with the conventional straight stalk group, the CFP group had lower blood loss and hemoglobin changes than the conventional straight shank group ($P=0.01$; $P=0.09$) (Table 3).

There were 4 cases of fracture around the CFP group and 1 case of the traditional group. Among them, 4 cases in the CFP group were femoral stem tip femoral lateral fractures, 3 cases because the femoral neck dry angle was larger than the prosthetic neck dry angle, and 1 case because the femoral medial cortical bone was too hard. There were no special treatments in the 3 cases. On the 3rd day after the operation, the practice part of the weight was standing, and gradually increased to full weight after 3 months. One patient was fixed with titanium wire during operation and started to support in March. The weight of the next exercise part. All patients had a fracture that healed after 6 months. One patient in the traditional group underwent revision due to a periprosthetic fracture occurring 3 months after surgery.

In the CFP group, imaging findings showed that one patient had periprosthetic osteolysis in the Gruen 1 and Gruen 7 regions, whereas in the conventional group, 2 patients had periprosthetic osteolysis (1 in the Gruen 7 region). And Gruen 6 area, 1 case in Gruen 1 area). There was no significant difference in the incidence of

osteolysis between the two groups ($P>0.05$).

Heterotopic ossification was found in 3 patients, 1 in the CFP group and 2 in the conventional group. The difference was not statistically significant ($P>0.05$).

There were 3 cases of central thigh pain in the CFP group and 1 case in the traditional group. The difference was not statistically significant ($P>0.05$).

There was 1 case of prosthetic dislocation in CFP group and 1 case in traditional group, the difference was not statistically significant ($P>0.05$).

There was no statistically significant difference in the thrombosis of the lower extremities and the loosening of the prosthesis ($P>0.05$).

A total of 1 case was reconstructed in the traditional group, which was a distal fracture of the prosthesis. The survival rate of the prosthesis was 96.8%. There were no revisions in the CFP group and the survival rate of the prosthesis was 100% (Table 4).

IV. Discussion

Total hip arthroplasty is one of the most common surgical procedures in joint surgery. It is rapidly developed because it can improve hip function and improve the quality of life of patients. Only 2.5 million people in the United States have received THA. More than 1 million people receive THA each year [13, 14]. General total hip arthroplasty will affect the proximal femoral stress balance after resection of the femoral neck. Abnormal stress changes will change the self-regulation and remodeling of the bone tissue, and the latest development of hip replacement surgery aims to not affect the joint prosthesis. The bone is preserved to the maximum extent under stability. Therefore, CFP was first designed and applied by Pipino in 1983 and has achieved good surgical results [15-17].

To investigate the clinical effects of CFP prostheses and conventional straight stem prostheses in total hip arthroplasty, we retrospectively compared the use of 33 patients with CFP prostheses and 31 patients with conventional straight stem prostheses, with a mean follow-up of 55 patients. Both clinical efficacy and imaging findings showed good performance in both groups of prostheses. We followed up and found that the CFP prosthesis was not significantly superior to the traditional straight stalk prosthesis in terms of postoperative HHS score and WOMAC score, similar to previous studies [18]. Gill et al [19] performed an average of 43 months of follow-up in 75 patients with THA in the CFP prosthesis, and found that the patient's HHS score increased from 50 points before surgery to 94 points at the last follow-up, while at the same time, In a 10-year follow-up study, Hutt et al [20] found that the patient's HHS score increased from 50 points before surgery to 91 points after surgery. Whether the clinical efficacy of CFP prosthesis is better than traditional straight stem prosthesis, the results still need further analysis.

In this study, there were 4 cases of fractures in the distal femur of the CFP group, and 3 cases because the femoral neck stem angle was greater than the neck stem angle. 1 cases had excellent osseous bone in the medial cortex of the femur. On the one hand, it might be due to the selection of a large prosthesis trial, or because the Chinese neck bone stem angle was greater than that of the CFP neck stem angle design (126 degrees and 117 degrees) [10, 21].

Osteolysis was detected in both groups in imaging evaluation. One reason was that stress shielding effect led to osteolysis in Gruen 7 area. Another reason might be wear particles [22,23] at the prosthetic joint interface, which caused inflammation and release of inflammatory mediators in surrounding tissues, leading to bone loss. Despite periprosthetic osteolysis in the CFP group, studies have confirmed that proximal femoral osteopenia and aseptic loosening do not affect the clinical stability of femoral prosthesis [24, 25], but Lazarinis et al [23] found that CFP prosthesis may also be unable to prevent proximal femoral bone loss. In addition, Burchard et al [26] concluded from a virtual model that CFP prosthesis still has certain stress. Shielding effect, therefore, will affect the long-term clinical efficacy and long-term survival rate. This study has some limitations. Firstly, the number of cases in the study is insufficient and the follow-up time is short, so it is difficult to obtain good statistical effect. Secondly, the study was retrospective. All patients came from a medical institution, which easily constituted selection bias.

V. Conclusion

Both CFP prosthesis and traditional straight handle prosthesis can significantly improve the hip function of patients. There is no significant difference between the two groups in the curative effect and the incidence of complications. However, in the long-term follow-up, whether the clinical effect of femoral neck preservation is better than that of the traditional straight handle group still needs further randomized controlled trials.

References

- [1]. KRESS A M, SCHMIDT R, NOWAK T E, et al. Stress-related femoral cortical and cancellous bone density loss after collum femoris preserving uncemented total hip arthroplasty: a prospective 7-year follow-up with quantitative computed tomography [J]. Arch Orthop Trauma Surg, 2012, 132(8): 1111-9.
- [2]. MOLFETTA L, CAPOZZI M, CALDO D. Medium term follow up of the Biodynamic neck sparing prosthesis [J]. Hip Int, 2011, 21(1): 76-80.
- [3]. PIPINO F, MOLFETTA L, GRANDIZIO M J J O O, et al. Preservation of the femoral neck in hip arthroplasty: results of a 13- to 17-year follow-up [J]. 2000, 1(1): 31-9.
- [4]. WACHA H, DOMSEL G, HERRMANN E J E J O T, et al. Long-term follow-up of 1217 consecutive short-stem total hip arthroplasty (THA): a retrospective single-center experience [J]. 2018, 44(3): 457-69.
- [5]. BERND B, CHRISTIAN H, THOMAS B, et al. 9- to 11-year results of cemented titanium mueller straight stem in total hip arthroplasty [J]. 2007, 30(7): 551-7.
- [6]. WEISSINGER M, HELMREICH C, P?LL G. %J ACTA CHIRURGIAE ORTHOPAEDICAE ET TRAUMATOLOGIAE CECHOSLOVACA. Results covering 20 years use of the cement-free Zweymüller Alloclassic total endoprosthesis of the hip joint [J]. 2010, 77(3): 186.
- [7]. BELLAMY N, BUCHANAN W W, GOLDSMITH C H, et al. Validation study of WOMAC: a health status instrument for measuring clinically important patient relevant outcomes to antirheumatic drug therapy in patients with osteoarthritis of the hip or knee [J]. 1988, 15(12): 1833-40.
- [8]. HAWKER G, MELFI C, PAUL J, et al. Comparison of a generic (SF-36) and a disease specific (WOMAC) (Western Ontario and McMaster Universities Osteoarthritis Index) instrument in the measurement of outcomes after knee replacement surgery [J]. 1995, 22(6): 1193-6.
- [9]. DELEE J G, CHARNLEY J. Radiological demarcation of cemented sockets in total hip replacement [J]. Clin Orthop Relat Res, 1976, 121): 20-32.
- [10]. GRUEN T A, MCNEICE G M, AMSTUTZ H C. "Modes of failure" of cemented stem-type femoral components: a radiographic analysis of loosening [J]. Clin Orthop Relat Res, 1979, 141): 17-27.
- [11]. HODGKINSON J P, SHELLEY P, WROBLEWSKI B M. The correlation between the roentgenographic appearance and operative findings at the bone-cement junction of the socket in Charnley low friction arthroplasties [J]. Clin Orthop Relat Res, 1988, 228): 105-9.
- [12]. ZICAT B, ENGH C A, GOKCEN E. %J JOURNAL OF BONE, et al. Patterns of osteolysis around total hip components inserted with and without cement [J]. 1995, 77(3): 432-9.
- [13]. MARADIT KREMERS H, LARSON D R, CROWSON C S, et al. Prevalence of Total Hip and Knee Replacement in the United States [J]. The Journal of bone and joint surgery American volume, 2015, 97(17): 1386-97.
- [14]. PIVEC R, JOHNSON A J, MEARS S C, et al. Hip arthroplasty [J]. Lancet, 2012, 380(9855): 1768-77.
- [15]. GHERA S, BISICCHIA S. The collum femoris preserving stem: early results [J]. Hip Int, 2013, 23(1): 27-32.
- [16]. VAN O J, SCHAFFROTH M U, RIJK E, et al. Learning curve analysis of the Collum Femoris Preserving total hip surgical technique [J]. 2013, 23(2): 154-61.
- [17]. MINGQING L, YIHE H, JIE X J A O E T T. Analysis of the complications of the collum femoris preserving (CFP) prostheses [J]. 2015, 48(6): 623-7.
- [18]. LI M, XU C, XIE J, et al. Comparison of collum femoris-preserving stems and ribbed stems in primary total hip arthroplasty [J]. J Orthop Surg Res, 2018, 13(1): 271.
- [19]. GILL I R, GILL K, JAYASEKERA N, et al. Medium term results of the collum femoris preserving hydroxyapatite coated total hip replacement [J]. Hip Int, 2008, 18(2): 75-80.
- [20]. HUTT J, HARB Z, GILL I, et al. Ten year results of the collum femoris preserving total hip replacement: a prospective cohort study of seventy five patients [J]. Int Orthop, 2014, 38(5): 917-22.
- [21]. NAN J, LIN P, MOHAMMED A Q, et al. Femoral version, neck-shaft angle, and acetabular anteversion in Chinese Han population: a retrospective analysis of 466 healthy adults [J]. 2015, 94(21): e891.
- [22]. GRANT P, AAMODT A, FALCH J A, et al. Differences in stability and bone remodeling between a customized uncemented hydroxyapatite coated and a standard cemented femoral stem A randomized study with use of radiostereometry and bone densitometry [J]. Journal of orthopaedic research : official publication of the Orthopaedic Research Society, 2005, 23(6): 1280-5.
- [23]. LAZARINIS S, MATSSON P, MILBRINK J, et al. A prospective cohort study on the short collum femoris-preserving (CFP) stem using RSA and DXA. Primary stability but no prevention of proximal bone loss in 27 patients followed for 2 years [J]. Acta Orthop, 2013, 84(1): 32-9.
- [24]. NOWAK M, NOWAK T E, SCHMIDT R, et al. Prospective study of a cementless total hip arthroplasty with a collum femoris preserving stem and a trabeculae oriented pressfit cup: minimum 6-year follow-up [J]. Arch Orthop Trauma Surg, 2011, 131(4): 549-55.
- [25]. PIPINO F, KELLER A J J O O, TRAUMATOLOGY. Tissue-sparing surgery: 25 years' experience with femoral neck preserving hip arthroplasty [J]. 2006, 7(1): 36-41.
- [26]. BURCHARD R, BRAAS S, SOOST C, et al. Bone preserving level of osteotomy in short-stem total hip arthroplasty does not influence stress shielding dimensions – a comparing finite elements analysis [J]. 2017, 18(1):

Table 1 Baseline Demographic and Patient characteristics

	CFP stems (n=33)	Straight Stems (n=31)	P value
Gender (m/f)	18/15	13/18	0.44
Age (years)	54.2±8.7	55.3±9.0	0.64
BMI (kg/m ²)	24.6±1.7	25.4±1.9	0.09
Preoperative function			
HHS score	48.9±5.0	49.2±6.7	0.88
WOMAC score	60.5±6.9	59.8±4.6	0.86

Table 2 Results of HHS , WOMAC score in the two groups

	HHS			WOMAC			
	CFP stems(n=33)	Straight Stems (n=31)	P value	CFP stems(n=33)	Straight Stems (n=31)	P value	P value
Preoperative	48.9±5.0	49.2±6.7	0.88	60.5±6.9	59.8±4.6	0.86	

Clinical application of Collum femoris-preserving (CFP) prosthesis in Total Hip Arthroplasty

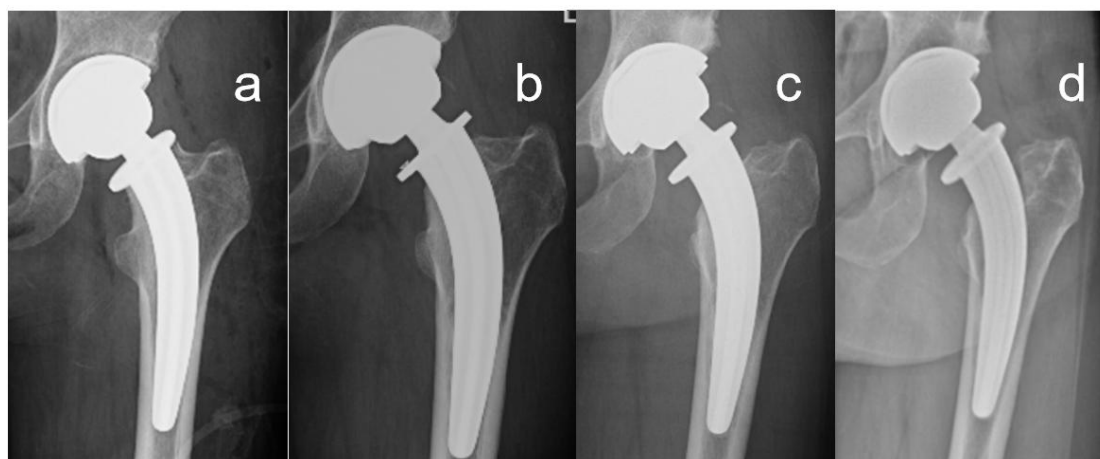
1 year	87.2±2.9	85.7±3.3	0.06	8.1±2.2	9.8±1.8	0.00
3 year	90.8±1.5	91.6±1.9	0.07	7.3±1.6	7.6±1.5	0.10
Last follow-up	92.8±1.7	91.9±1.7	0.04	7.2±1.6	7.2±1.4	0.69

Table 3 Results of perioperative outcome in the two groups

	CFP stems(n=33)	Straight Stems (n=31)	P value
Operative time (min)	67.6±14.3	77.1±17.1	0.01
Change in hemoglobin (g/l)	34.4±12.9	40.7±19.0	0.09
Blood loss(ml)	193.9±99.8	188.7±142.4	0.38

Table 4 Summary of complications in each group

	CFP stems(n=33)	Straight Stems(n=31)	P value
Osteolysis	1 (3.0%)	2 (6.5%)	0.61
Thigh pain	3 (9.1%)	1 (3.2%)	0.61
Dislocation	1 (3.0%)	2 (6.5%)	1
Periprosthetic fracture femoral	4 (12.1%)	1 (3.2%)	0.36
Aseptic loosening	0	3 (9.7%)	0.11
Deep venous Thrombosis	2 (6.1%)	1 (3.2%)	1
Ectopic ossification	1 (3.0%)	2 (6.5%)	0.67
Deep infection	0	0	1
Survival rate	100%	96.8%	



Post-operative anteroposterior radiograph of a 31-year-old woman of the left hip (a). Anteroposterior radiograph 1-year after THA using a CFP stem (b). Anteroposterior radiograph at 3-year follow-up showing osteolysis in Gruen zone 7 (c) Anteroposterior radiograph at 5-year follow-up showing osteolysis in Gruen zone 1 and 7 (d)

Hasibul Hasan. "Clinical application of Collum femoris-preserving (CFP) prosthesis in Total Hip Arthroplasty." IOSR Journal of Dental and Medical Sciences (IOSR-JDMS), vol. 18, no. 10, 2019, pp 80-84.