

Class III Malocclusion: A Case Report

*Elena Petrova¹, Maja Pop Stefanova Trposka², Vesna Fiser³, Iva Manevska⁴,
Trajan Nikolov⁵, Emina U Kadric⁶

¹Department of Orthodontics, Faculty of Dentistry, Skopje, North Macedonia

²Faculty of Dentistry, European University, Skopje, North Macedonia

³Private dental practice "Jankulovski", Skopje, North Macedonia

⁴Richmond Orthodontics, London, United Kingdom

⁵Private dental practice "Nova Naselba", Veles, North Macedonia

⁶Resident at Department of Orthodontics, Faculty of dentistry, Skopje, North Macedonia

Abstract: Class III malocclusion or mandibular prognathism has long been viewed as one of the most severe facial deformities. This malocclusion does not appear to be a sex associated trait, since the sex distribution of the probands in some investigations was approximately equal. Neither was there a significant difference in the sex of affected parents and sblings of probands. The frequency of mandibular prognathism and Class III malocclusion is relatively small in the general population. This report presents a case of 10.5 years old boy with a hypodivergent class III malocclusion combined with impaction of the maxillary cuspids. Treatment had major impacts on self-esteem, masticatory function, speech and facial esthetics.

Date of Submission: 28-10-2019

Date of Acceptance: 12-11-2019

I. Introduction

Class III dental malocclusion is anterioposterior dentoalveolar relationship characterized by a more anterior position of mandibular teeth relative to the maxillary teeth. An increase in the frequency of mandibular prognathism from childhood to adulthood has been reported. There is a study that confirms that going more east, the percentage of Class III increases, so Angle Class III malocclusion is common characteristic in the Japanese people. A wide range of environmental factors have been suggested as contributory to the development of mandibular prognathism., but the quantitative role of heredity in the etiology of this condition has also been reported.

The object of treatment is, first to improve the skeletal imbalance by orthopedic forces and, second to improve tooth alignment and establish intercuspal relations by orthodontic means.

II. Case report

A 10.5 year old boy with class III malocclusion came to our clinic at the Department of orthodontics. Extraoral and intraoral investigation suggested a concave profile, hypodivergent type of class III, deep reverse frontal bite and absence of space for maxillary cuspids. The orthopan film showed as impaction of the maxillary cuspids.

On the other side by the cephalometric analysis we found out skeletal class III malocclusion, proclination of the maxillary incisors combined with retroinclination of the mandibular ones, decreased basal angle NSBa= 122°, negative ANB angle (-5°), Wits appraisal of -9mm, SNB= 89°-increased.

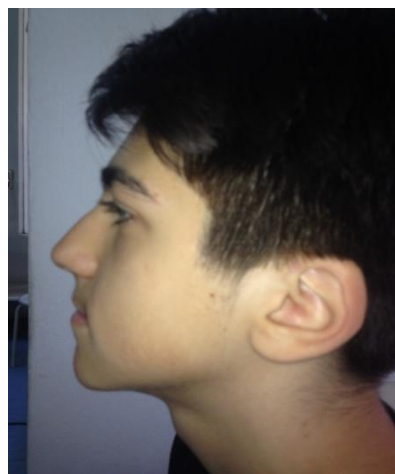The treatment plan consists first of facial mask, disclusion of the deep prognathic bite by a removable orthodontic splint appliance so the facial mask can be more efficient. Also a self-ligating fixed appliance in the maxilla. After 3 months of wearing the facial mask we got normal overbite in the frontal area.

Comparison of the cephalometric tracings showed also some skeletal improvements. SNB angle decreased to 83°, ANB=1°, Wits=-1mm. Next step of our treatment was to get enough space for the impacted cuspids. Afterwards on the right cuspid a corticotomy was done and by a technique of double arch (main wire SS 0.16x0.16, and accessory wire NiTi 0.12), we have aligned the cuspid from palatal ectopic position to its right one. The left cuspid had better position and only gingivectomy with a soft tissue laser was enough to be done for its alignment.

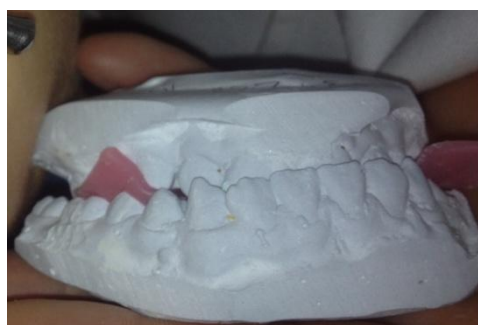Before removing the fixed appliances a new cephalogram was done and the analyze showed more skeletal corections. As a summery: proinclination of the upper incisors, retroposition of the B point, incrise of the total and lower anterior facial hight, correccion of the ANB angle and the Wits appraisal and a happy face of the patient.



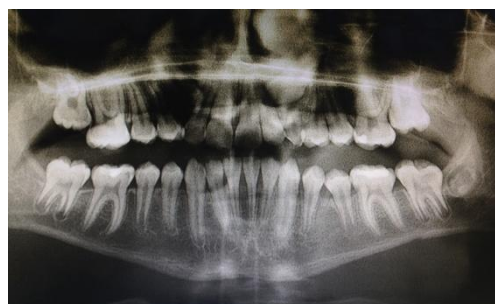Picture no1: En face photograph of the patient



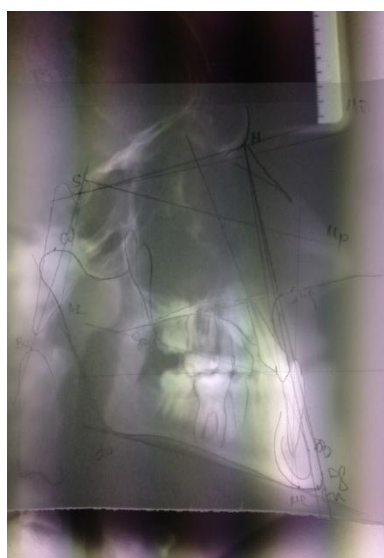Picture no2: Profile photograph of the patient



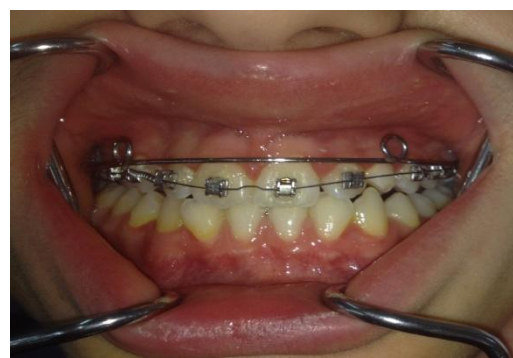Picture no3: Plaster model of the patient




Picture no4: Orthopantomograph of the patient



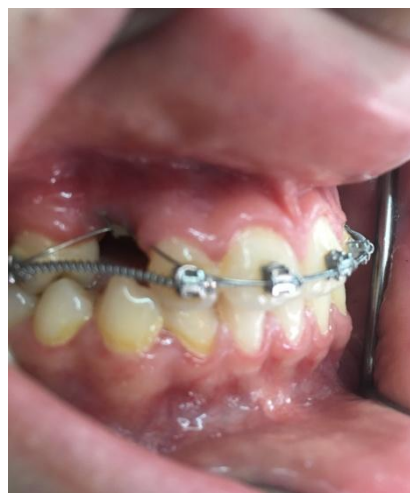Picture no5: Lateral cephalometric radiograph with analysis



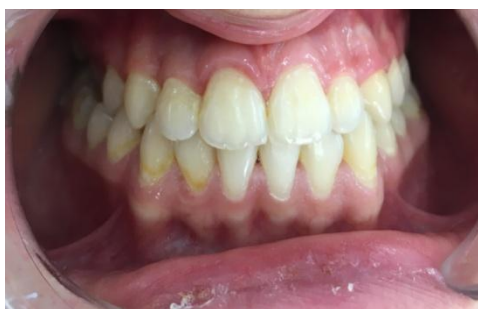Picture no6: Progress of the therapy



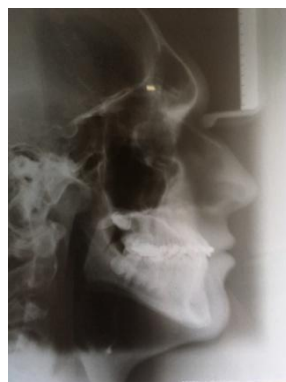Picture no7: Lateral cephalometric radiograph after maxillary protraction



Picture no8: Traction of the impacted canines with double arch technique



Picture no9: Intraoral photograph after the treatment



Picture no10: Lateral cephalometric radiograph after the treatment

III. Conclusion

Class III malocclusion has been divided into two basic morphologic types: hyperdivergent and hypodivergent. Depends of the type of class III we have to decide what protocols will be best for correction of this severe dentofacial anomaly. The mode of treatment have to be based on a proper diagnosis of the cause of the malocclusion, such as retrusive maxilla, protrusive mandible or both. The treatment has to be started as soon as possible because of the specific morphology and the psychological impact of the affected facial lines.

References

- [1]. Baccetti T, Franchi L, Cameron C, Mc Namara Jr JA. Treatment timing for rapid maxillary expansion. *Angle Orthodontist* 2001; 71 (3):343-350
- [2]. Baccetti T, Reyes CB, Mc Namara Jr JA. Gender differences in class III malocclusion. *Angle Orthod* 2006; 75, (4):510-520
- [3]. Cho HJ, Nguyen T. A classification system of mandibular prognathism. *Oral surgery* 2008; 1:125-34
- [4]. Chang HP, Kinoshita Z, Kawamoto T. Craniofacial pattern of class III deciduous dentition. *Angle Orthodontist* 1992; 62 (2): 139-44
- [5]. De Toffol, Pavoni C, Baccetti T, Franchi L, Cozza P. Orthopedic treatment outcomes in Class III malocclusion. *The Angle Orthodontist* 2008; 78 (3):561-573
- [6]. Houston WJB. Mandibular growth rotations-their mechanisms and importance. *Eur J Orth* 1988; 10:369-73 Kanno Z, Kim Y, Soma K. Early correction of a developing skeletal Class III malocclusion. *Angle Orthodontist* 2007; 77 (3):549-56
- [7]. Kuc-Michalska, Baccetti T. Duration of the pubertal peak in skeletal Class I and Class III subjects. *Angle Orthodontist* 2010; 80 (1):54-57
- [8]. Moon W, Khullar R. Ngan T, Deguchi EW, Roberts LE. Class III orthopedic treatment of malocclusion. Benthami Science Publisher Ltd, SharjahUAE, 2014: 116-150