

## Tuberculous Lymphadenitis with Papillary Carcinoma Thyroid

Dr Ann Rhoda Abraham<sup>1</sup>, Dr Viaji Raveendran<sup>2</sup>, Prof Dr G Rekha<sup>3</sup>

<sup>1</sup>Post Graduate in General Surgery Saveetha Medical Hospital and College Saveetha Nagar, Thandalam  
Chennai – 602 105 India

<sup>2</sup>Senior Resident in General Surgery Saveetha Medical Hospital and College Saveetha Nagar, Thandalam  
Chennai – 602 105 India

<sup>3</sup>Chief of General Surgery Saveetha Medical Hospital and College Saveetha Nagar, Thandalam Chennai – 602  
105 India

Corresponding Author: Dr Ann Rhoda Abraham

---

**Abstract:** Papillary thyroid cancer (PTC) is the most frequent histological subtype of thyroid cancer. In a high proportion of patients with PTC at the time of surgery, lymph node metastasis is identified. Tuberculous lymphadenitis is a common cause of cervical lymphadenopathy in Asian countries. (1)

A 25-year-old female presented with papillary thyroid carcinoma and was diagnosed to have tuberculous lymphadenitis also. She was subsequently managed for both.

The cervical tuberculosis co-existence should be considered in the etiology of an enlarged lymph node for patients with PTC. (2) (3)

**Keywords:** Papillary thyroid cancer, tuberculous lymphadenitis, thyroid, tuberculosis.

---

Date of Submission: 30-10-2019

Date of Acceptance: 15-11-2019

---

### I. Introduction:

Papillary thyroid cancer management is based on the general and local conditions involving tumor site, size, and lymph node metastasis. Total thyroidectomy is performed in most cases. Lymph node metastasis is identified by ultrasonography, computed tomography (CT) scanning, or fine-needle aspiration biopsy or cytology. Tuberculous lymphadenitis is a common cause of cervical lymphadenopathy in Asian countries. Here we report a case of tuberculous lymphadenitis mimicking metastatic lymph nodes from PTC and emphasize that the coexistence of cervical tuberculosis should be considered in the etiology of an enlarged lymph node for the patients with PTC.

### II. Case presentation:

25-year-old female presented with swelling in the anterior aspect of the neck for 2 weeks. It was incidentally noticed with no pain or fever. No features of hyper or hypo-thyroidism were present. She did not have history of fever or dysphagia or other pressure symptoms. There was no history of contact to an open case of TB. No history of malignancy in the family.

She had no comorbid history and no prior surgical history. Her menstrual cycles are regular and she is unmarried.

On examination, she was moderately built and nourished. Systemic examination was normal. Local examination of the neck revealed a 5\*3cm swelling of the neck at the region of the thyroid to the left. The swelling was found to move on deglutition and was deep to the deep cervical fascia. It was hard in consistency with no warmth or tenderness. Also, a 1\*1cm firm swelling was palpable in the left upper jugular region, deep to deep cervical fascia. It was a single lymph node which was mobile, non-tender and skin over the node was normal.

Routine investigations were normal except for an elevated esr. The thyroid function test and serum calcium was normal. Ultrasound of the neck showed a well-defined heterogeneous lesion – 3.2x1.8x2.2 with no significant lymphadenopathy. CECT of the neck was reported to have a heterogeneously enhancing nodule in

the left lobe of the thyroid with infiltration of the left lateral wall of the trachea, oesophagus. Chest x-ray showed a thin walled cavity in the left upper lobe with fibrosis and consolidation. FNAC of the thyroid swelling was done and the cellular smears showed well defined cell margins, increased cytoplasmic density and vacuolation, enlarged nucleus, intra-nuclear lesions, nuclear grooving, foam cell change and associated multinucleated and langhanooid giant cells, epithelial giant cells and hurthle cells.

Patient was taken up for total thyroidectomy with functional and central node dissection and specimen was sent for histopathology study. Post-operatively there was no complication and the patient was discharged after 12 days.

Histo-pathology report was that of papillary carcinoma thyroid (T2N1M0) with no angio-invasion, no lymphatic or capsular or peri-neural invasion, and no extra-thyroidal invasion. (Fig 1) Also, out of the 14 nodes, around 6 showed metastatic deposits and 2 nodes had caseating granulomatous lymphadenitis (Fig 2).

Chest medicine opinion was obtained and the patient was started on AKT4. Patient was followed up after 3 weeks.

### III. Conclusion

The most common clinical presentation of extrapulmonary tuberculosis is cervical lymphadenitis. There is a history of tuberculous contact in only 21.8% and tuberculous infection in only 16.1% of the cases with cervical lymphadenitis. (4) Cervical tubercular lymphadenitis occurs in the posterior triangle or supra-clavicular region of the neck. They usually present as single or multiple painless matted lymph nodes. Whereas nodal metastasis from papillary thyroid carcinoma involve the jugulo-digastric and pre-tracheal lymph nodes. (5)

Tuberculous lymph nodes are seen as round, hypo-echoic lesions, showing intra-nodal cystic necrosis and calcification in ultrasonography. These features are similar to metastatic PTC cervical nodes. Enhanced conglomerate nodal masses are observed in CT. (6)

FNAC can detect cervical tuberculosis in 25-77% cases. The sensitivity and specificity of FNAC in the diagnosis of tuberculous lymphadenitis are 88% and 96%, respectively. (7)

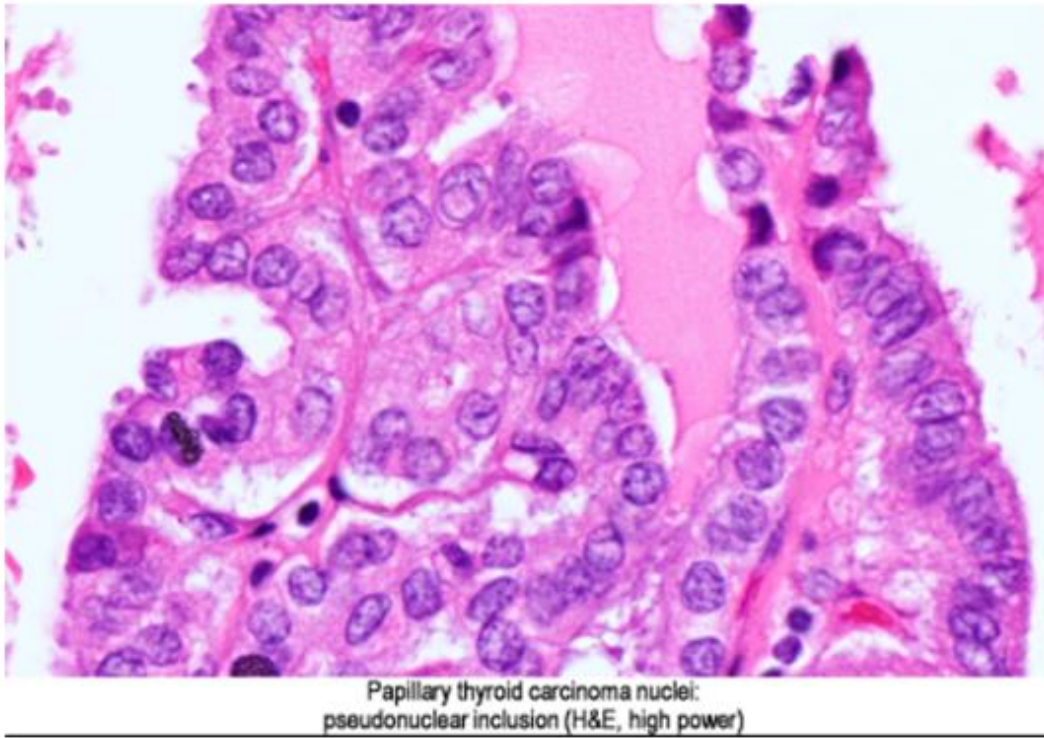
Cervical tuberculous lymphadenitis responds to anti-tuberculous medications and the need for surgery is not warranted unless the development of an abscess, needing incision and drainage.

Total thyroidectomy with neck dissection was done which showed that the involvement of the lateral lymph nodes was not due to metastases but due to tuberculosis.

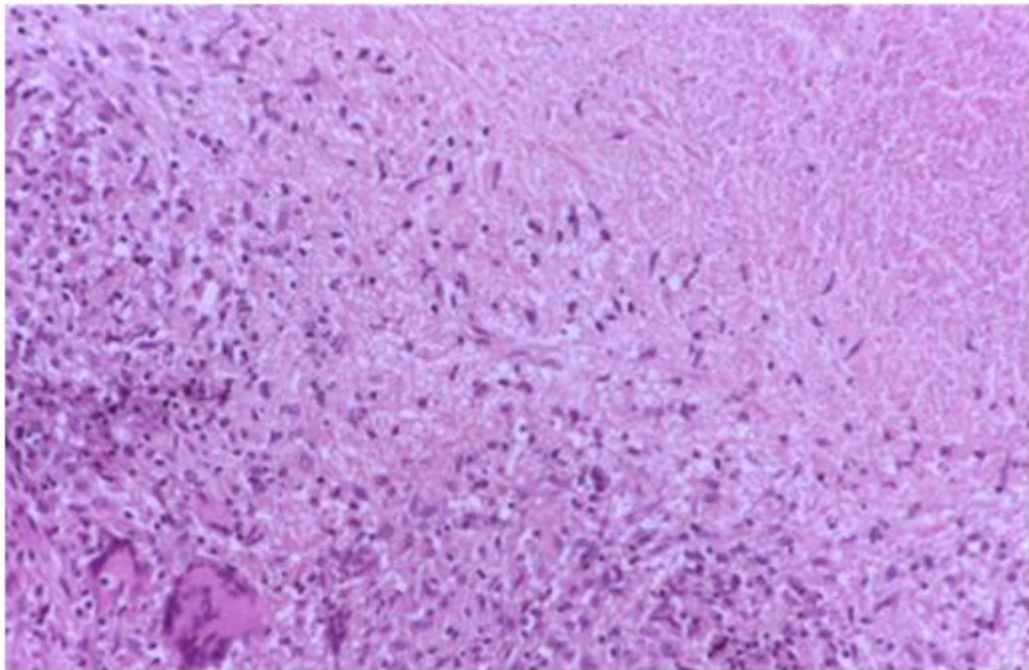
Hence pre-op diagnosis of tuberculous infection is important to avoid unnecessary surgical and secondary complications.

### References

- [1]. Cantrell RW, Jensen JH, Reid D. Diagnosis and management of tuberculous cervical adenitis. *Arch Otolaryngol.* 1975;101:53-57.
- [2]. M.J. Schlumberger Papillary and follicular thyroid carcinoma *N. Engl. J. Med.*, 338 (1998), pp. 297-306
- [3]. E. Mirallic, J. Visset, C. Sagan, *et al.* Localization of cervical node metastasis of papillary thyroid carcinoma *World J. Surg.*, 23 (1999), pp. 970-973 discussion 3-4
- [4]. M. Kanlikama, S. Mumbuc, Y. Bayazit, A. Sirikci Management strategy of mycobacterial cervical lymphadenitis *J. Laryngol. Otol.*, 114 (2000), pp. 274-278
- [5]. S. Noguchi, A. Noguchi, N. Murakami Papillary carcinoma of the thyroid. I. Developing pattern of metastasis *Cancer*, 26 (1970), pp. 1053-1060
- [6]. P.M. Som Detection of metastasis in cervical lymph nodes: CT and MR criteria and differential diagnosis *AJR Am. J. Roentgenol.*, 158 (1992), pp. 961-969
- [7]. S.S. Chao, K.S. Loh, K.K. Tan, S.M. Chong Tuberculous and nontuberculous cervical lymphadenitis: a clinical review *Otolaryngol. Head Neck Surg.*, 126 (2002), pp. 176-179



**Fig 1**



**Fig 2**

Dr Ann Rhoda Abraham. "Tuberculous Lymphadenitis with Papillary Carcinoma Thyroid."  
IOSR Journal of Dental and Medical Sciences (IOSR-JDMS), vol. 18, no. 11, 2019, pp 42-44.