

Intermaxillary Blockade through Enlarge Interdental Wire Technique: Technique's Description

Fabrcio Moreira Serra e SILVA¹, Anderson da Silva dos ANJOS², Matheus de Carvalho URQUIZA³, Gardene Paiva MAGALHÃES⁴,
Beatriz Leal de FREITAS⁵

(DDS, PhD - Mestre e Doutor em Cirurgia e Traumatologia Buco-Maxilo-Facial pela FOP-UNICAMP, Brasil)¹

(Residente em Cirurgia e Traumatologia Buco Maxilo Faciais HU UFMA, Brasil)²

(Especializando em Cirurgia e Traumatologia Buco Maxilo Facial ABCD – Piauí, Brasil)³

(Acadêmica de Odontologia do Centro Universitário UNINOVAFAPI, Brasil)⁴

(Acadêmica de Odontologia da Universidade Estadual do Piauí – UESPI, Brasil)⁵

Abstract: The treatment of maxillofacial fractures usually requires the dental occlusion as a reference for an appropriate reduction. A variety of technique intermaxillary fixation is described in the literature, showing its indications and contraindications. The use of techniques with steel wire, Erich bar and locking screws, are currently the most reported and used. The risk of accidents, surgical time, cost and damage to teeth, are some of the points discussed when evaluating the advantages and disadvantages of each technique. So, we try to describe an option of simplified and efficient technique of inter-jaw lock using caliber of steel wire.

Keywords: Surgery, Oral, Dental Occlusion, Dentists

Date of Submission: 02-11-2019

Date of Acceptance: 18-11-2019

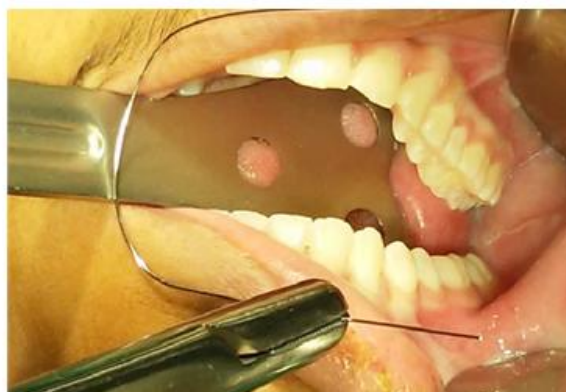
I. Introduction

The dental occlusion is the key point of maxillo-mandibular fractures treatment, both as final objective and as a way to obtain easily a better reduction and also fracture osteosynthesis. Establishing a steady maxillo-mandibular blockade in a fast and secure way is the main objective of the various techniques described in dentistry literature. Some disadvantages as surgery duration, injuries periodontal, surgeon drilling accidents risk and some materials cost are reasons for there are still search for new techniques. [1], [3], [9]. Thus, we will describe a simple and efficient maxillo-mandibular blockade technique that uses gauge steel wire, as option to reestablish in a secure and steady way the occlusal relation of patients with maxillomandibular fractures [5].

II. Technique Description

The interdental enlarge wires technique uses 10 cm length steel wire segments numbered 2, 4 or 5 according to interproximal spaces found. The areas of premolar teeth are preferably chosen, being also possible the chosen for other areas which contains more interproximal contact. (Pic. 1A/B). [6].

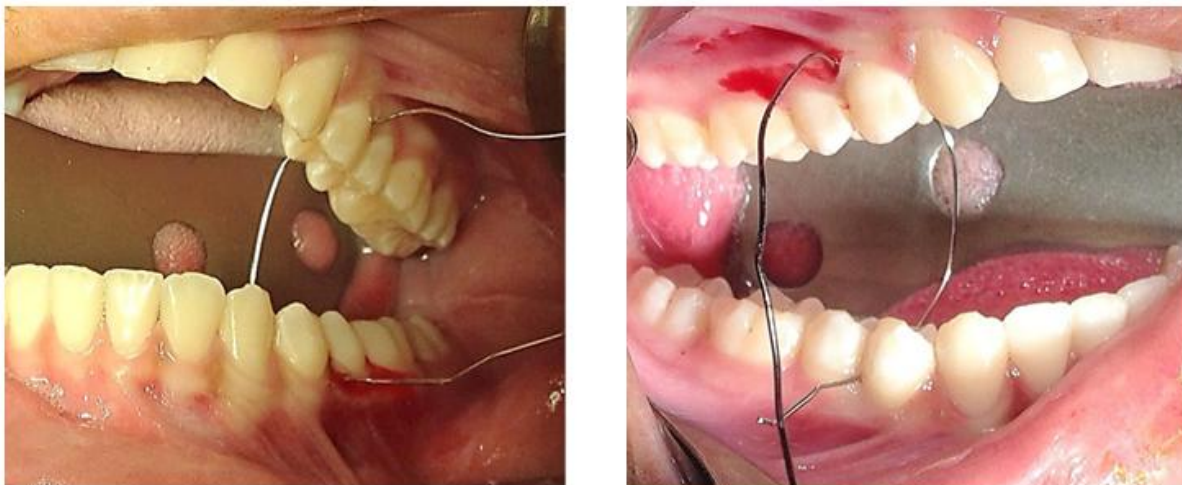
Picture 1A/B – selection and bending of steel wires according to interproximal spaces.



Intermaxillary Blockade through Enlarge Interdental Wire Technique: Technique's Description

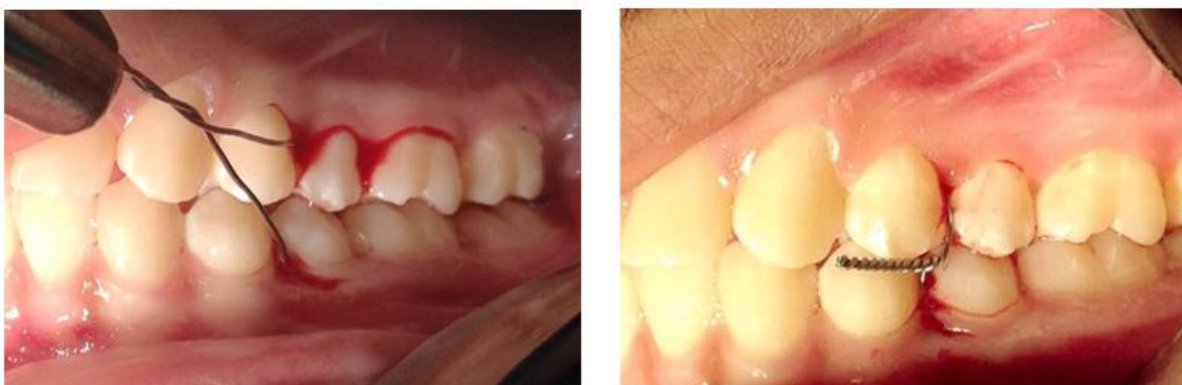After the área chose, the gum is pierced by the wire in the niche in the buccal-palatine directions of the upper teeth, following the lingual-buccal directin of the lower teeth (Pic. 2A/B).

Picture 2A/B – Passage of the wires through the proximal spaces, following the upper buccal-palatine and lower lingual buccal directions.



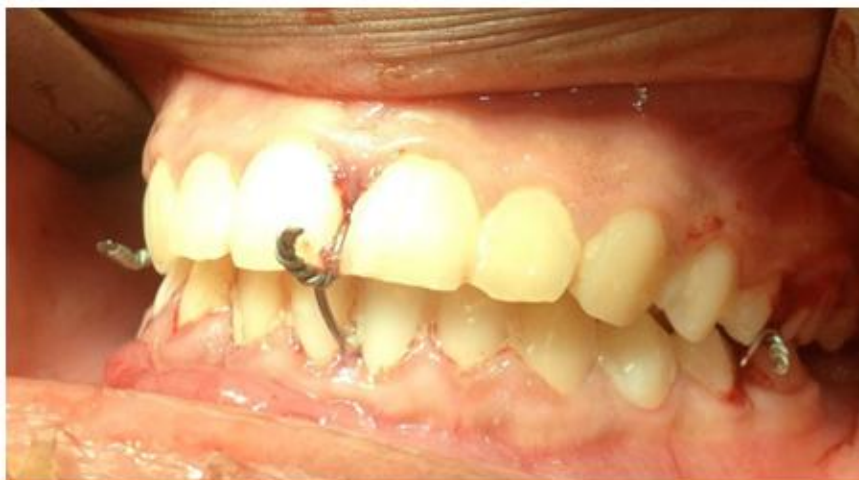After the bilateral setup of one or two wires, the jaw is handled in a way to reestablish the dental occlusion. After that, the wires are twisted and the blockade handled (Pic. 3A/B).

Picture 3A/B – Intermaxillary block in number 4 caliber interdental wire applied bilaterally



In some cases, it is possible to Pierce the gum with the wire through the middle line área what helps the intermaxillary blockade stability (Pic. 4).

Picture 4 – Calibratinh steel wire application applied to midline to ensure stability



To decrease surgical time and risks of team drilling accidents. It is still possible to highlight as advantage the technique low cost. As disadvantage the presence of diastema can hinder, and many times make impossible the application of the technique.[2]. Damage to periodontal resembles damage caused by other techniques, it was not detected insertion concussions or even significant dental trauma when applied to the caliber wires.[10].

III. Discussion

The interdental enlarge wire technique is indicated in cases of easy occlusion reestablishment for fractured segments handling. However, it is not recommended in cases of multiple fractures with dentoalveolar segments or even of unfavorable reduction. [4], [8]. Once well indicated, one of this technique advantages is to achieve intermaxillary blockade stability, using only two or four wires and without the need to twist the wire to the limit of fatigue, what helps.[7].

IV. Conclusion

The interdental enlarge wire technique proves to be an effective, practical and safe option when well indicated.

Reference

- [1]. ARTHUR, G.; BERARDO, N. **A simplified technique of maxillomandibular fixation**. J Oral Maxillofac Surg, v. 47, p. 1234, 2005.
- [2]. BANKS, P. **Fraturas da porção de apoio dos dentes na mandíbula**. In: BANKS, P. *Killey's Fraturas da Mandíbula*. São Paulo: Santos, 2004. capo 6, p. 40-79.
- [3]. BUSCH, RF.; PRUNES, F. **Intermaxillary fixation with intraoral cortical bone screws**. Laryngoscope, v.101, p.1336- 1338, 2014.
- [4]. BUSCH, R F. **Maxillomandibular fixation with intraoral cortical bane screws: a 2 year experience**.Laryngoscope, v. 104, p. 1048- 1050,2014.
- [5]. KARLIS, V; GLICKMAN, R **An alternative to arch-bar maxillomandibular fixation**. Plast Sug, v. 99, n. 6, p.1758-1759, 2014.
- [6]. LASKIN, D. M.; BEST, A M. **Current trends In the management of maxillofacial injuries in the United States**. J Oral Maxillofae Surg, v. 46, p. 595, 1988.
- [7]. MINAMI, R T.; MORRILL, L. R; WEBER, J. Jr. **Intermaxillary fixation with orthodontic brackets bonded to teeth**. Plast Reconstr Surg, v. 54, n. 4, p. 492-494, 2000.
- [8]. SHETTY, V; NIEDERDELLMANN, H. **Maxillomandibular fixation with minihooks: a clinical evaluation**. Oral Surg, v. 64, n. 6, p. 677-679, 2017
- [9]. WIN, K. K. S. et al. **Intermaxillary fixation using screws**. Report of a technique. IntJ Oral Maxillofac Surg ,v. 20, p. 283-284, 2011.
- [10]. VARNATIAN, J.; ALVI,A. **Bone-screw mandible fixation: an intraoperative alternative to arch bar**. Otolaryngol Head Neck Surg, v. 123, n. 6, p. 718-721, 2011.

Fabrcio Moreira Serra e SILVA. "Intermaxillary Blockade through Enlarge Interdental Wire Technique: Technique's Description". IOSR Journal of Dental and Medical Sciences (IOSR-JDMS), vol. 18, no. 11, 2019, pp 79-81.