

## Management and Outcome of Penetrating Head Injury in a Civilian Population

Aliyu Muhammad Koko, Ali Lasseini, Nasiru Jinjiri Ismail, Bello B. Shehu

Department of Neurosurgery, Regional centre for neurosurgery, Usmanu Danfodiyo University Teaching Hospital Sokoto, Nigeria.

Corresponding Author: Aliyu Muhammad Koko

---

### Abstracts:

**Background:** Penetrating head injury (PHI) remains one of the most complex and fatal forms of traumatic brain injury. The management of penetrating head injury presents serious challenges to attending neurosurgeons especially in a low resource setting; where facilities for prompt neurocritical care, neuroimaging and neurosurgical reconstruction are grossly inadequate. The study was designed to describe the pattern and outcome of penetrating head injury in our institution.

**Methods:** This is a retrospective analysis of patients with penetrating head injury (breach of dura by foreign object or piece of bone) managed from July 2015 to June 2019.

### Results

Out of the total of ninety-one patients managed, males constituted the majority (90%). The mean age of presentation was 34 years  $\pm$  19 SD. Road traffic crash was the commonest mechanism of injury (61/91), followed by gunshot injury (15/91). Assaults by armed bandits using machetes and hammers were observed in 11/91 of the cause of penetrating head injury. Cerebral contusions, depressed skull fractures and extradural haematomas were the main cranial computerised tomographic findings. All the patient had debridement and duroplasty. Majority (73/91) were discharged with Glasgow outcome score of  $\geq$  4, superficial wound infection occurred in 11 patients (12.1%) and mortality was recorded in 7/91 (7.7%).

**Conclusion:** Penetrating head injuries were more common in young male population of our society and road traffic crash was the main mechanism of injury. Although, majority had good outcome the rates of mortality and post-operative wound infection were quite significant.

---

Date of Submission: 05-11-2019

Date of Acceptance: 21-11-2019

---

### I. Introduction

Penetrating head injury remains one of the most complex and fatal forms of traumatic brain injury. It's characterized by communication between intracranial cavity with dural breach and external environment.<sup>1</sup> Penetrating head injury is less common than blunt head injury and accounts for about 0.4% of all head injuries.<sup>2-4</sup> The rising arm banditry and cattle rustling in our sub-region has resulted in a greater proportion of civilians presenting with penetrating head injury. Varied aetiological factors have been described including but not limited to road traffic accidents, physical assaults and violence using low and high velocity objects.<sup>3</sup> Cranial computerised tomographic scan is the most accepted imaging modality used in evaluation of patients with penetrating head injuries.<sup>5</sup> Intraoperative ultrasound which is safe and non-invasive has been reported to help in identification and removal of the haematoma, bone fragments and foreign objects from the brain.<sup>6</sup> Penetrating head injury has been associated with fatal outcome with high mortality rates in civilian population ranging from 34% to 88.1%.<sup>7,8</sup> Prompt intensive care in combination with adequate and meticulous neurosurgical care have been shown to reduce morbidity and mortality.<sup>9</sup> The management of penetrating head injury presents a serious challenge to attending neurosurgeons especially in a low resource institution; where facilities for prompt neurocritical care, neuroimaging and neurosurgical reconstruction may not be readily available for use. Due to the paucity of penetrating head injury in civilian population there is inadequate literature on the management and outcome of patients with this form of devastating traumatic brain injury.<sup>5,10</sup> The study was designed to describe the pattern and outcome of penetrating brain injury in our settings.

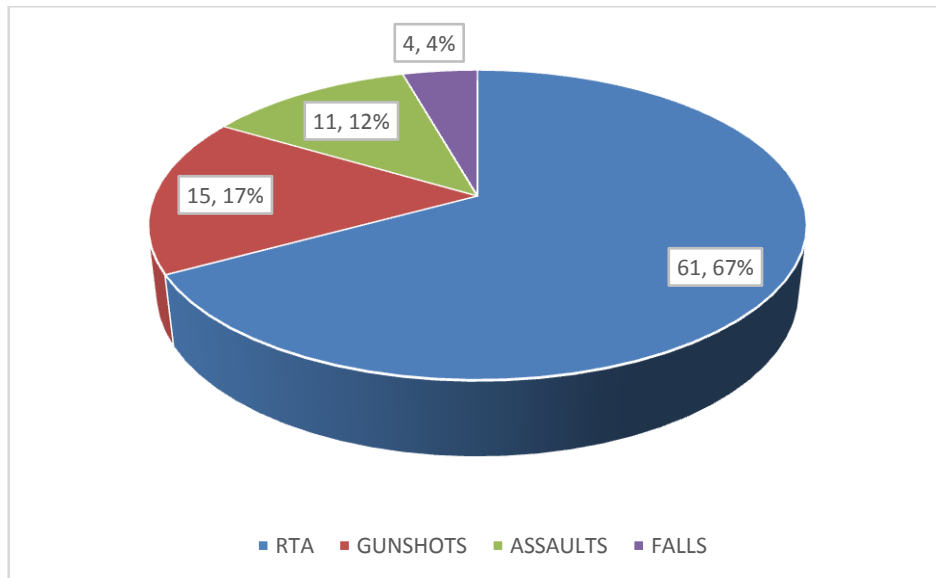
### II. Materials and Method

This is retrospective analysis of cases of penetrating head injury managed from July 2015 to June 2019. Clinical details, neuroimaging and operative findings and outcome were obtained from patient's case files and operation register and analysed using SPSS version 20.0 for windows. Only patients with documented

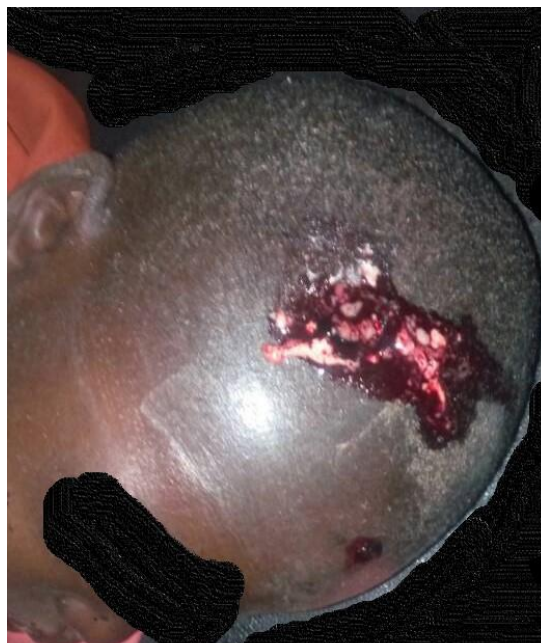penetration of dura by either broken bone or foreign objects with open scalp wound were included in the study. Cases with associated cerebrospinal fluid rhinorrhea or otorrhea were excluded.

### III. Results

Out of the total of ninety-one patients managed over the study period, males constituted the majority (90%). The mean age of presentation was 34 years  $\pm$  19 SD. Road traffic crash was the commonest mechanism of injury 61/91(67.3%) (Figure 1) Depressed skull fractures, extradural haematomas and contusions were the main cranial computerised tomographic findings. All the patient had debridement, duroplasty and evacuation of haematoma where indicated. Majority of patients(73/91) were discharged with Glasgow outcome score of  $\geq$  4, superficial wound infection occurred in 11 patients (12.1%) and the rate of mortality was recorded in 7/91 (7.7%).



**Figure 1:** Distribution based on Aetiology



**Figure 2:** clinical photograph showing brain evisceration

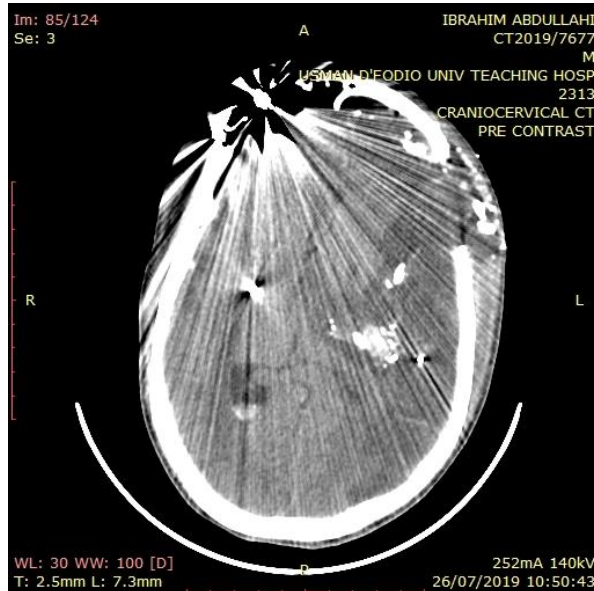


Figure 3: Axial cut CT scan of a of gunshot injury to the head

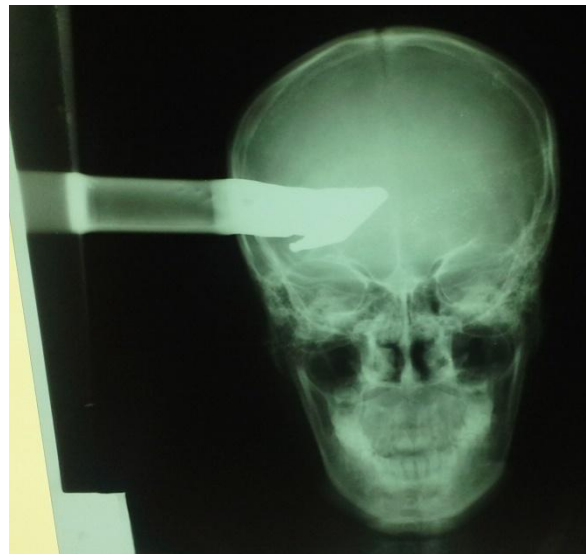

Figure 4: Skull x-ray showing a metallic object penetrating the skull

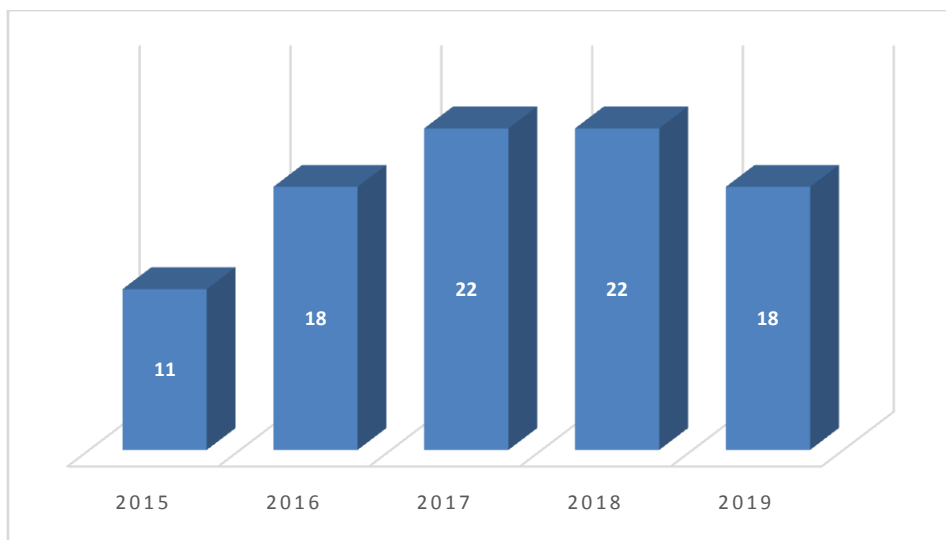


Figure 5: Occurrence of PHI by Year

#### IV. Discussion

As shown in the present study head injury commonly affects young males' individuals worldwide.<sup>5,11-13</sup> We found road traffic accidents to account for the majority of cases of penetrating head injury followed by gunshots (both accidental and violent), assaults by armed bandits and few cases of falls (including both fall from height and fall into water-well). This finding differs from the previous study that reported assault to be the commonest cause followed by accidental machine injury and road traffic crash.<sup>5</sup> As in other studies cerebral contusions, depressed skull fractures and extradural haematoma were the main computerised tomographic scan findings.<sup>5</sup> Debridement craniectomy and duroplasty was done in all patients and additional evacuation of extradural haematoma done where its present. This agrees with the report of a study in India.<sup>5</sup> Although high mortality and severe morbidity have been associated with penetrating head injury in civilian and military cases, majority of our patients had good post-operative outcome (Glasgow outcome score of 4 and above).<sup>14,15</sup> The difference in outcome noted may be attributed to high road traffic crashes compared to firearms related injury found in our series. The rate of mortality found was 7.7% (7/91), this is quite lower than the findings of other study, as high as 93% mortality rate has been reported.<sup>14</sup>

The intracranial bone fragments and foreign objects if not debrided might increase the risk infection. Bone fragments have been found to have high chance of infection than metallic objects.<sup>16</sup> An infection rate of 4-11% was reported in literature.<sup>17,18</sup> In contrast to the index study 12.1% (11/91) infection rate was observed.

#### V. Conclusion

Penetrating head injuries were more common in young male population of our society and road traffic crash followed by firearms related injury were the main mechanism of injury. Although, majority had good outcome the rates of post-operative infection and mortality were significant.

#### Reference

- [1]. Mackerle Z. and Gal P. Unusual penetrating head injury in children: personal experience and review of the literature. *Childs Nerv Syst* (2009) 25:909–913. DOI 10.1007/s00381-009-0901-z
- [2]. Wellingson S.P., Bernardo M., Marcelo P., Matheus S. S., Robson L.O. A, Almir F. A. et al. Surgical treatment of a transorbital penetrating brain injury. *Clinical Ophthalmology* 2010;4 1103–1105
- [3]. Youssef F., Mehdi L., Mohamed S. Penetrating head trauma: 03 rare cases and literature review. *Pan African Medical Journal*. 2017;28:305. doi:10.11604/pamj.2017.28.305.10376
- [4]. Syed F. K., Muhammad S. S, Muhammad Z. T, Syed A.E, Shahan W. Management of penetrating brain injury. *Journal of Emergencies, Trauma, and Shock I*. 2011;4:3
- [5]. Ram A. M, Bal K. O, Anil C, Sunil K. S, Chhitij S, Nagesh C. Outcome of Penetrating Brain Injury in Civilian Practice. *Indian J Neurotrauma* 2015;12:122–127.
- [6]. Deng D, Dan G, Tao J, et al. Conventional and contrast-enhanced ultrasound assessment of craniocerebral gunshot wounds. *GenetMol Res* 2015;14(2):3345–3354
- [7]. Dosoglu M, Orakdogan M, Somay H, Ates O, Ziyal I. Civilian gunshot wounds to the head. *Neurochirurgie*. 1999;45:201Y207.
- [8]. Stone JL, Lichtor T, Fitzgerald LF. Gunshot wounds to the head in civilian practice. *Neurosurgery*. 1995;37:1104Y1110; discussion 10-12
- [9]. Bhat AR, Wani MA, Kirmani AR, et al. Disaster management of civilian gunshot headwounds in north Indian state. *Indian J Neurotrauma* 2009;6(1):27–42
- [10]. Justin M. S, Jonathon J. L, Jorge L. E, Jeroen R. C, Richard D. B and Saleem I. A. Management of Nonmissile Penetrating Brain Injuries: A Description of Three Cases and Review of the Literature. *SKULL BASE REPORTS*. 2011; 1(1)
- [11]. Allison B. W, Carlos R., Randy B., Christopher N., Rocco A, Warren D. et al. Long-term outcomes of combat casualties sustaining penetrating traumatic brain injury. *Trauma Acute Care Surg*. 2012; (73)
- [12]. Ross D. Z, Deborah L. W, Cynthia L. H.F, Nelson V. V and Kertia B. Penetrating head injury: A prospective study of outcomes. *Neurological Research*, 2001; 23:219-226
- [13]. John B, Allen W.H. The Epidemiology of Traumatic Brain Injury: A Review. *Epilepsia*, 2003;44(10): 2-10
- [14]. Nathoo N, Boodhoo H, Nadvi SS, Naidoo SR, Gouws E. Transcranial brainstem stab injuries: a retrospective analysis of 17 patients. *Neurosurgery* 2000;47(5):1117–1122, discussion 1123
- [15]. Siccardi D, Cavaliere R, Pau A, Lubinu F, Turtas S, Viale GL. Penetrating craniocerebral missile injuries in civilians: a retrospective analysis of 314 cases. *Surg Neurol* 1991;35(6):455–460
- [16]. Aarabi B, Taghipour M, Haghnegahdar A, Farokhi M, Mobley L. Prognostic factors in the occurrence of posttraumatic epilepsy after penetrating head injury suffered during military service. *Neurosurg Focus* 2000;8(1):e1
- [17]. Pitlyk PJ, Tolchin S, Stewart W. The experimental significance of retained intracranial bone fragments. *J Neurosurg* 1970;33(1):19–24
- [18]. Brandvold B, Levi L, Feinsod M, George ED. Penetrating craniocerebral injuries in the Israeli involvement in the Lebanese conflict, 1982–1985. Analysis of a less aggressive surgical approach. *J Neurosurg* 1990;72(1):15–21

Ekpenyong, Nnette. "Management and Outcome of Penetrating Head Injury in a Civilian Population." *IOSR Journal of Dental and Medical Sciences (IOSR-JDMS)*, vol. 18, no. 11, 2019, pp 13-16.