

Malignant Mixed Mullerian Tumor of Uterus: A Rare Case Report.

Dr.RukmaPrabhu, Dr.Manjusha Jindal

Abstract

Malignant mixed Mulleriantumour (MMMT) is also known as Carcinosarcoma. It is a malignant neoplasm arising in the uterus, the ovaries, the fallopian tubes or any body part that contains epithelial and mesodermal tissue. It is very rare and aggressive type of malignancy, accounts for 2-5% of all tumours derived from body of uterus. It is considered as a metaplastic carcinoma.

MMMTs of uterus present in postmenopausal women (median age 65) with bleeding per vagina and pain in abdomen. They pose a diagnostic dilemma.

This tumour is usually seen associated with chronic estrogen stimulation, radiation therapy and tamoxifen therapy. Nulliparity, diabetes and obesity are the predisposing factors. The outcome correlates with the stage of disease and depth of myometrial invasion. Five year disease free survival by advancing stage is poor. Combination chemotherapy with ifosfamide and cisplatin may improve progression free survival.

We present a case of 60 year old, who presented to our OPD with complaint of postmenopausal bleeding and on imaging it was considered to be endometrial carcinoma. The biopsy report was inconclusive. She later underwent Hysterectomy with bilateral salpingo-oophorectomy with lymphadenectomy. Histopathology of specimen showed Malignant mixed Mulleriantumour.

It is important that the clinician should have high index of suspicion for postmenopausal patients presenting with per vaginal bleeding and should consider possibility of Malignant mixed Mulleriantumour.

Date of Submission: 18-12-2019

Date of Acceptance: 01-01-2020

I. Introduction

A malignant mixed mulleriantumor/ carcinosarcoma is also known as malignant mixed mesodermal tumour (MMMT). It is a cancer found in the uterus, the ovaries, the fallopian tubes and other parts of the body. It is a biphasic tumour composed of epithelial and mesenchymal element believed to arise from monoclonal origin, giving rise to carcinomatous and sarcomatous changes respectively¹.

It is a rare tumour accounting for only 2-5 % of all uterine malignancies², highly aggressive and tends to occur in postmenopausal and low parity women. It mostly presents as vaginal discharge, abdominal mass or pelvic pain. It is usually diagnosed at an advanced age & because of its rarity, no treatment guidelines are available.

Treatment is usually multimodal including radical surgery followed by adjuvant chemotherapy and radiotherapy, or combined chemo-radiotherapy. Prognosis is usually poor.

II. Case

A 61 year old, nulliparous lady, non-obese, postmenopausal for 15 years presented to OPD with complaint of vaginal bleeding for 15 days and on and off abdominal pain.

No other complaint or systemic illness.

On examination general condition was fair, vitals were stable, on perabdominal palpation, a midline mass arising from pelvis of 14 week size pregnant uterus was felt. Local examination showed fleshy mass at vulva with leucoplakia present all along vulva including clitoris.

On Per vagina examination – necrotic mass felt through os, cervical canal open, uterus was mobile and fornices were free, blood stained foul smelling discharge was present.

The possible diagnosis of Infected fibroid polyp or carcinoma endometrium was made and the patient was subjected to investigations.

Investigations:

USG – uterus bulky 14x8.9x8.7cm ill defined, heterogenous mass distending uterine cavity extending into cervical canal, multiple cystic areas within mass, with thinning of overlying myometrium.

MRI – large polypoidal mass distending endometrial cavity and endocervical canal, enlarged (R) obturator, (R) External iliac, (R) Common iliac LN.
Endometrial sampling – inconclusive.

Hence considering the diagnosis of Carcinoma endometrium, the surgical modality of treatment was planned. After obtaining consent, “extrafascial Transabdominal hysterectomy with salpingo-oophorectomy with pelvic lymphadenectomy” was done.

OT findings:

Uterus enlarged to 14 week size

Puckering of serosal surface was observed

B/L fallopian tubes and ovaries appeared normal

Flimsy adhesion of bowel and posterior uterine wall on right side

Solid nodule 2x1 cm in small bowel wall noticed s/o ? Metastasis

Right side external iliac lymph node enlarged 2x1 cm with necrotic material within.

Right obturator and right common iliac were 2x1 cm no necrotic material within.

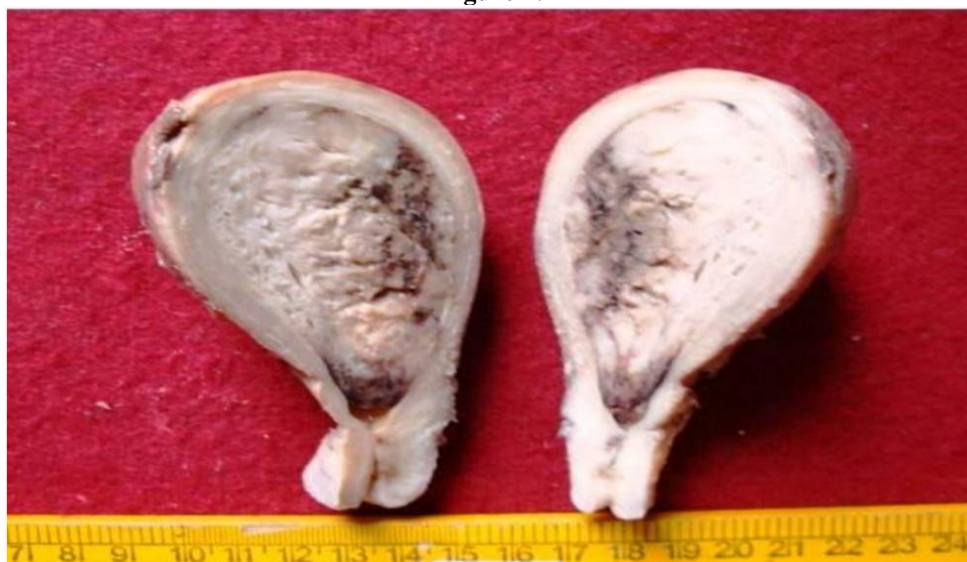No ascites no peritoneal deposits

Cut Section : A greyish white polypoidal growth measuring 6x5x2cm obliterating endometrial cavity and infiltrating outer 1/3rd wall of the uterus. (Figure 1).

Right ovary measured 2.5x1.5cm, fallopian tube 5 cm . C/S- greyish white

Left ovary measured 3.5x2x2cm and fallopian tube measures 2 cm. C/S greyish white material.

Figure 1:



Microscopy:

Multiple sections from walls of the uterus showed malignant mixed mullerian tumor.

Tumor revealed massive areas of necrosis, haemorrhage and giant cells.

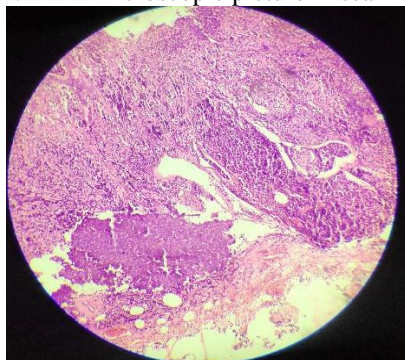
There were Sarcomatoid areas comprising of leiomyosarcoma, rhabdomyosarcoma, chondrosarcoma, squamous cell carcinoma, neuroendocrine carcinoma, poorly differentiated adenocarcinoma. Thus confirming diagnosis of malignant mixed mullerian tumor. (Figure 2)

The growth exhibited an infiltration into outer 1/3rd of uterine wall.

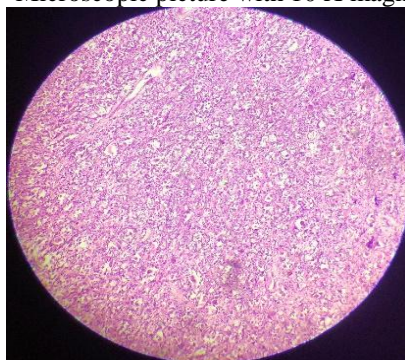
Sections from both ovaries, fallopian tube and Right external iliac lymph node revealed metastasis.

Figure 2:

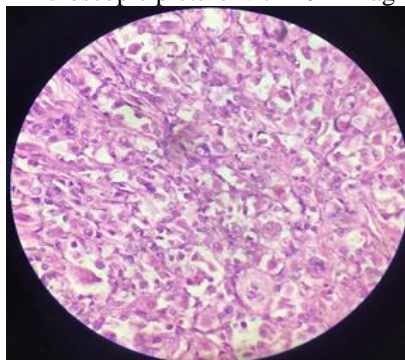
A. Microscopic picture in scanner



B. Microscopic picture with 10 X magnification



C. Microscopic picture with 40 X magnification



Hence final diagnosis was made of malignant mixed mulleriantumor Stage III C 1.

Further plan was to give adjuvant chemoradiotherapy for the patient. However patient did not follow up in the hospital.

III. Discussion

Malignant uterine neoplasm's containing both carcinomatous and sarcomatous elements are designated in the International Society of Gynecological Pathologists (ISGyP) and World Health Organisation (WHO) classification of uterine neoplasm's as carcinosarcomas.³

Carcinosarcoma of the uterus (malignant mixed Müllerian tumor [MMMT]), is a biphasic neoplasm composed of malignant epithelial and mesenchymal components.¹

Incidence:

These are uncommon neoplasms, with an incidence of fewer than 2 per 100,000 women per year⁴. Carcinosarcoma comprises less than 5% of malignant neoplasms of the uterine corpus. Account for 16.4% of all deaths caused by a uterine malignancy.⁵

Although relatively rare, carcinosarcomas of the uterus, and of the gynaecologic and urinary tracts in general, are more common than in other sites, such as lung, possibly because the epithelial stem cells are mesodermal in origin.

They have an extremely poor prognosis, with a 5-year survival rate of 33% to 39%.⁴

Uterine Carcinosarcoma has been identified in decreasing order of frequency in the vagina, cervix, and ovary and most rarely in the fallopian tubes.³

These tumors are currently thought to be monoclonal carcinomas with sarcomatous differentiation.⁴

There are three main theories regarding the histogenesis of Uterine Carcinosarcoma (UC):³

- (1) The collision theory suggests that the carcinoma and sarcoma are two independent neoplasms.
- (2) The combination theory suggest that both components are derived from a single stem cell that undergoes divergent differentiation early in the evolution of the tumor.
- (3) The conversion theory suggests that the sarcomatous elements derive from the carcinoma during the evolution of the tumor.

On exploring the literature we found that W G McCluggage named one more theory: The composition theory which suggests that the spindle cell component is a pseudosarcomatous stromal reaction to the presence of the carcinoma.⁶

Microscopically UC is composed of both epithelial and mesenchymal elements may be intermittently mixed or be seen as two distinct components. The mesenchymal elements may be homologous, containing cells native to the uterus including Stromal sarcoma, fibrosarcoma or leiomyosarcoma (2%) or heterologous with mixed components including rhabdomyosarcoma (18%), chondrosarcoma (10%), osteosarcoma (5%) or liposarcoma (1%).³

According to immunohistochemistry (IHC) visualized tumor markers such as enzymes, oncogenes, tumor-specific antigens, tumor suppressor genes and tumor proliferation markers, efficiently predict oncogenesis.

Immunohistochemistry can be used to assess which tumors are likely to respond to therapy, by detecting the presence or elevated levels of the molecular target.

Immunohistochemistry is typically not required to establish the diagnosis of this entity, although it may be required to distinguish it from a sarcomatoid carcinoma. The epithelial component is usually immunoreactive with cytokeratins, epithelial membrane antigen (EMA), and vimentin. The mesenchymal component usually stains for vimentin, smooth muscle actin, desmin, and focal cytokeratin.⁴ Both the sarcomatous and carcinomatous components often coexpress epithelial markers and vimentin to varying degrees.⁴

Clinical presentation:

Typically seen in post menopausal women with median age of 65yrs. Cases are rarely seen in younger women and children.

Risk factors^{7,8}

- Excess weight
- Exogenous estrogen
- Nulliparity
- Prior pelvic radiation^{9,10}
- Long term tamoxifen¹¹

Protective factors⁷

- Oral contraceptive pills
- Smoking

Presenting symptoms may be

- Abnormal vaginal bleeding
- Vaginal discharge bloody or watery
- Abdominal pain
- Palpable abdominal mass

Diagnosis of Uterine Carcinosarcoma is most often made postoperatively by histopathological examination and Immunohistochemical (IHC) studies.

Carcinosarcomas should be staged like carcinomas of the endometrium.

Prognostic indicator

- Surgical stage

- Myometrial depth invasion

Myometrial invasion beyond the inner third is seen in 80% of tumors and 40% show deep myometrial invasion. However, confinement to an endometrial polyp in absence of myometrial invasion does not preclude extra-uterine spread.

Lymphatic and vascular space invasion is detected in many cases, with extrauterine spread and metastases at the time of presentation

In general, most metastatic deposits and foci of lymphatic and vascular space invasion are composed of the carcinomatous element, with sarcomatous metastases being rare.⁴

Management usually includes:

Total abdominal hysterectomy and bilateral salpingo-oophorectomy with or without pelvic lymph node dissection. Adjuvant therapy with radiation therapy and/or chemotherapy is recommended depending on the clinical and pathological factors, including tumor stage, histological subtype, grade, lymphovascular invasion and distant metastasis.

Adjuvant radiotherapy comprising a combination of external radiotherapy to whole pelvis followed by intravaginal brachytherapy may be recommended to postoperative patients with early stages of carcinosarcoma. Postoperative radiation appears to improve local control.⁴

A critical review of the literature on adjuvant chemotherapy in uterine carcinosarcoma has been described. Patients with higher stage of disease may be considered for ifosfamide plus paclitaxel combination chemotherapy.⁴

Although the effect of chemotherapy treatment varied among patients, adjunctive ifosfamide and cisplatin chemotherapy may also improve progression-free survival. Even after this the incidence of tumor recurrence is high.

IV. Conclusion

To conclude Uterine Carcinosarcoma which arise from female genital tract can have both epithelial and mesenchymal component. If epithelial component is benign and mesenchymal component is malignant then it is called as Adenosarcoma. If both epithelial component and mesenchymal component is malignant then it is called as Carcinosarcoma. UC is a rare, highly aggressive, rapidly progressive neoplasm associated with a poor prognosis.

Patients with Postmenopausal bleeding and large bulky uterus should be treated with high index of suspicion even if the reports of endometrial curetings are inconclusive as in our case.

References:

- [1]. Rani Kanthan, Jenna- Lynn Senser; uterine carcinosarcoma: A Review with Special Emphasis on the Contraversies in Management ;Obstetric and Gynaecology international Volume 2011, Article ID 470795.
- [2]. Yashushi Adachi, Hirofumi Nonogaki, Sachiko Minamiguchi, Ming LI and Susumu Ikehara; Carcinosarcoma of the uterus: A case report, MOLECULAR AND CLINICAL ONCOLOGY 4: 571-573, 2016.
- [3]. Dr. Siva Ranjan D., Dr. J Surendar, Dr. Rama Swamy A S., Dr. Manjunatha H K., Malignant Mixed Mullerian Tumor of the Uterus (Uterine Carcinosarcoma): A Case Report; IOSR Journal Of Pharmacy; Volume 3, Issue 9 (October 2013), Pp 49-52.
- [4]. Bamniya Jaishree, Shah Ami, Dayal Anupama, Kothari Sadhna, Shah Mukul; A Rare Case of Malignant Mixed Mullerian Tumor (MMMT) of Uterus; Int J Res Med. 2015; 4(3):65-68.
- [5]. J. S. Bosquet, S. A. Terstriep, W. A. Cliby et al., —The impact of multi-modal therapy on survival for uterine carcinosarcomas, |Gynecologic Oncology, vol. 116, no. 3, pp. 419–423, 2010.
- [6]. W.G. McCluggage, Malignant biphasic uterine tumors: carcinosarcomas or metaplastic carcinomas?. J Clin Pathol. 2002; 55:321-5.
- [7]. Zelmanowicz A, Hildesheim A, Sherman ME, Sturgeon SR, Kurman RJ, Barrett RJ. Evidence for a common etiology for endometrial carcinomas and malignant mixed mullerian tumors. Gynecol Oncol. 1998 Jun. 69(3):253-7.
- [8]. Ostor AG, Rollason TP. Mixed tumours of the uterus. Fox H, Wells M. Haines and Taylor Obstetrical and Gynaecological Pathology. 4. New York City: Churchill Livingstone; 1995. 1: 587-621.
- [9]. Ali S, Wells M. Mixed Mullerian tumors of the uterine corpus: a review. Int J Gynecol Cancer. 1993 Jan. 3(1):1-11.
- [10]. Pothuri B, Ramondetta L, Martino M, Alektiar K, Eifel PJ, Deavers MT. Development of endometrial cancer after radiation treatment for cervical carcinoma. Obstet Gynecol. 2003 May. 101(5 Pt 1):941-5.
- [11]. Evans MJ, Langlois NE, Kitchener HC, Miller ID. Is there an association between long-term tamoxifen treatment and the development of carcinosarcoma (malignant mixed Müllerian tumor) of the uterus?. Int J Gynecol Cancer. 1995 Jul. 5(4):310313.