

## Endodontic Management of Mandibular Canine with Two Roots and Two Canals- An Unusual Case Report

Dr. Ramesh Chandra, Dr. Rehan Ahmad Khan, Dr. Amaan Khan, Dr. LubnaAfreeen

Department of Conservative Dentistry & Endodontics  
Career Post Graduate Institute of Dental Sciences & Hospital  
Corresponding Author: Dr. Ramesh Chandra

**Abstract-** In majority of cases, mandibular canines have one root and one root canal, although 15% may have two canals. Literature report shows incidence of two-rooted canine as low as 1.7%. This article reports a clinical case of endodontic treatment of mandibular canine with two roots and two canals.

**Index terms-** Anatomic variation, mandibular canine, root canal morphology, root canal treatment

Date of Submission: 04-02-2019

Date of acceptance: 19-02-2019

### I. Introduction

Successful root canal therapy requires a thorough knowledge of tooth anatomy and root canal morphology<sup>(11)</sup>. The aim of endodontic treatment is the elimination of infection from the root canal and the prevention of reinfection. Morphologic features of tooth may also adversely affect endodontic procedures<sup>(12)</sup>. Many clinicians have the perception that a given tooth will contain a specific number of roots and/or canals. Careful evaluation of research material has shown that variations in tooth morphology are common. In mandibular anterior teeth, prevalence of two or three root canal has been reported to be as low as 1% and as high as 43%.<sup>3</sup> Mandibular canines are recognized as having one root and one root canal in majority of cases. The occurrence of two roots and even more than two canals is rare, ranging from 1 to 5%<sup>(3)</sup>. The following is a case report of mandibular canine with separate two roots and two canals

### II. Case Report

A 32 year female patient reported to the department of prosthodontics for fabrication of crown with respect to right mandibular lateral incisor. She was sent to the department of conservative dentistry and endodontics for intentional RCT of right mandibular canine. Endodontic treatment was initiated after administering local anesthesia. Rubber dam was placed and endodontic access was performed with a round diamond point bur and EndoZ tapered safe end bur (DentsplyMaillefer, Switzerland). Negotiation of root canals was done with a size 10 K file. Cervical and middle third was prepared with SX file of ProTaper system (DentsplyMaillefer, Switzerland). Root canal length was determined with an electronic Apex Locator (Root ZX, J Morita, Japan) and reconfirmed radiographically. Biomechanical preparation was done up to ProTaper file size F1 using EDTA lubrication (RC-Prep, Dentalcompare, USA) under constant irrigation of 3% NaOCl and saline at each change of file. Obturation was performed using F1 ProTaper GP cones using AH Plus Sealer (DentsplyMaillefer, Switzerland). After 1 week, patient reported asymptotically and final restoration was performed

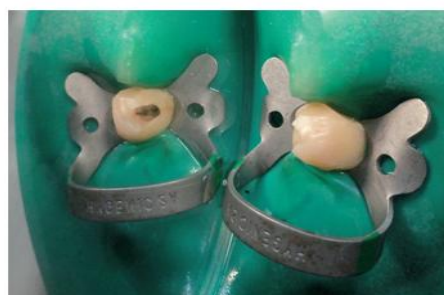

Fig 1: Access Cavity Preparation

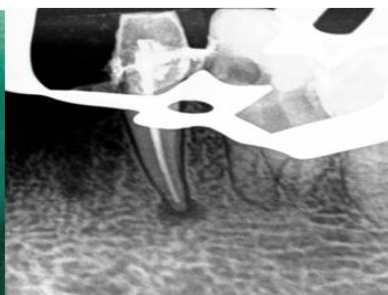
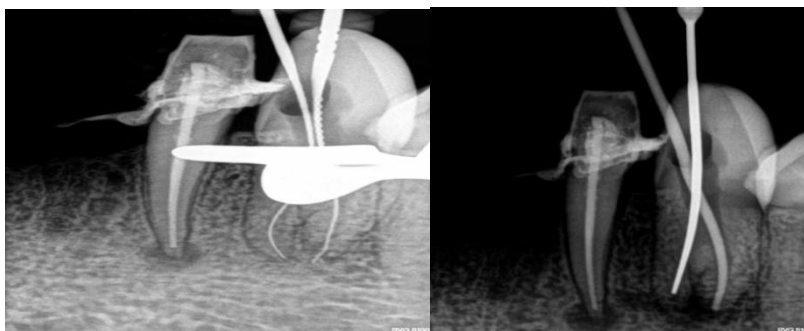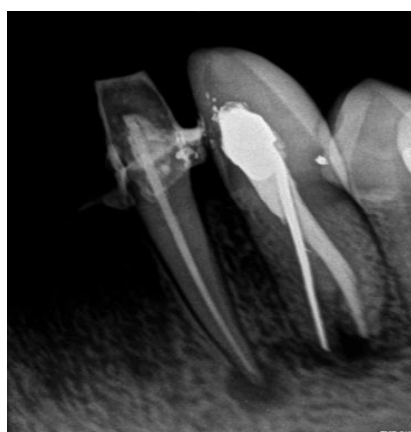


Fig 2: Preoperative radiovisiographic image of mandibular canine showing two roots



**Fig 3:** Radiovisiographic image of working

**Fig 4:** Radiovisiographic image of Length determination master apical file



**Fig 5:** Obturation

### III. Discussion

Diagnosis and identification of the number of roots and root canals are key factors for endodontic treatment. Good quality radiographs taken at different angulations some with file in place are very helpful in finding and locating extra roots. Additional root canals if not detected are major reason for failure of endodontic treatment. On reviewing the literature it becomes apparent that there is divergence of opinion as to the anatomy of root canal of human permanent teeth<sup>(3)</sup>. The incidence of two root canals in single-rooted teeth has been reported to be as low as 0.0% and high as 6.25%. Investigators have reported on the anatomical variations associated with mandibular canines. In a study conducted on internal anatomy of mandibular canines, analysis showed that 98.3% had only one root, 4.9% two canals and one foramen, 1.2% two canals and two foramen. Two canals and two roots were present in 1.7% of cases<sup>(11)</sup>.

In majority of cases, mandibular canines are recognized as usually having one root with one root canal. Our case report demonstrates mandibular canine with two separate roots and root canals<sup>(4)</sup>. Here bifurcation of root and root canal occurred at floor or cervical 1/3 which is in accordance with previous study which states bifurcation at cervical and middle third has been shown to occur in 43% of situation at these sites. One of the recent study states root bifurcation was observed at middle third and apical thirds.<sup>12</sup> Here, CBCT was used as it is more precise than periapical radiograph in confirming extra root and canals. With this coronal and axial view of the mandibular canine were readily produced, confirming two separate root and root canals, exact location and anatomy of root canal system could be assessed<sup>(5)</sup>.

Case reports displaying mandibular canines with two root canals have been published earlier. However, presence of two roots in mandibular canines is rarely observed. D'Arcangelo et al reported two cases of endodontic treatment of mandibular canines with two roots<sup>(6)</sup>. Victorino et al describes a case report of a patient with bilateral mandibular canine with two roots and two canals. Our case also demonstrates bilateral mandibular canines with two separate roots and root canals<sup>(7)(10)</sup>.

### IV. Conclusion

Failure to locate and treat extra canal is one of the most common causes for failure of root canal treatment. This case report shows presence of two separate roots and root canals in mandibular canine. Though such anatomic findings have been cited earlier, our case report highlights the importance of having detailed

knowledge of all possible root canalirregularities practitioners should look for and never assume canal systems are simple. Radiographs and magnification devices are important tools in diagnosing and treating such cases.

## References

- [1]. Alapati S, Zaatar EI, Shyama M, Al-Zuhair N. Maxillary canine with two root canals. *Med Princ Pract* 2006;15:74-76
- [2]. Bharadwaj A, Bharadwaj A. Mandibular canines with two roots and two canals. *Int J Dent Clin* 2011;3(3):77-78.
- [3]. Cantatore G, Berutti E, Castellucci A. Missed anatomy: Frequency and clinical impact. *Endod Topics* 2006;15:3- 31.
- [4]. D'Arcangelo C, Varvara G, de Faizo P. Root canal treatment in mandibular canines with two roots: A report of 2 cases. *Int Endod J* 2001 Jun; 34(4):331-34.
- [5]. Friedman S. Prognosis of initial endodontic therapy. *Endod Topics* 2002;2:59- 88.
- [6]. Green D. Double canals in single roots. *Oral Surg Oral Med Oral Pathol* 1973 May;35(5):689-96
- [7]. Gaikwad A. Endodontic treatment of mandibular canine with two canals—a case report. *Int J Dental Clin* 2011;3(1):118-19.
- [8]. Haapasalo M, Udnaes T, Endal U. Persistent, recurrent, and acquired infection of root canal system post-treatment. *Endodontic Topics* 2003 Nov;6(1):29-56.
- [9]. Ingle JI, Backland LK, Baumgartner JC (Eds). *Ingle's Endodontics* (6th ed). ON, Canada: BC Decker Inc. Publishing 2008.p.151.
- [10]. Mohammad Ahmad Alenezi<sup>1,2</sup>, Abdullah Yousef Al- Hawwas<sup>3</sup>. Permanent mandibular canine with two roots and two root canals: Two case reports. *Saudi Endod J* 2016;6:98-100
- [11]. Ouellet R. Mandibular permanent cuspids with two roots. *J Can Dent Assoc* 1995;61:159- 61.
- [12]. Prashant P Moogi, Reshma S Hegde, BR Prashanth, G Vinay Kumar, Nandini Biradar. Endodontic Treatment of Mandibular Canine with Two Roots and Two Canals *The Journal of Contemporary Dental Practice*, November-December 2012;13(6):902-904
- [13]. Pineda F, Kuttler Y. Mesiodistal and buccolingual roentgenographic investigation of 7,275 root canals. *Oral Surg Oral Med Oral Pathol* 1972;33:101- 10.
- [14]. Pécora JD, Sousa Neto MD, Saquy PC. Internal anatomy, direction and number of roots and size of human mandibular canines. *Braz Dent J* 1992;4(1):53-57.
- [15]. Sikri VK, Kumar V. Permanent human canines: Configuration and deviations of root canals: An in vitro study. *J Conserv Dent* 2003;6(4):151-60.
- [16]. Sert S, Bayirli GS. Evaluation of the root canal configurations of the mandibular and maxillary permanent teeth by gender in the Turkish population. *J Endod* 2004;30:391- 8.
- [17]. Sjogren U, Hagglund B, Sundqvist G, Wing K. Factors affecting the long-term results of endodontic treatment. *J Endod* 1990;16:498- 504.
- [18]. Vertucci FJ. Root canal morphology and its relationship to endodontic procedures. *Endod Topics* 2005;10:3- 29.
- [19]. Wang L, Zhang R, Peng B. Clinical features and treatment of mandibular canines with two root canals: Two case reports. *Chinese J Dent Res* 2009;12(1):61-62

Dr. Ramesh Chandra” Endodontic Management of Mandibular Canine with Two Roots and Two Canals- An Unusual Case Report.” *IOSR Journal of Dental and Medical Sciences (IOSR-JDMS)*, vol. 18, no. 2, 2019, pp 01-03.