

Orthodontic Management of A Mandibular Impacted Canine: Case Report

Dr. Jiju Mohan¹, Prof. Sandhya Maheshwari², Dr. Irum Uzma Siddiquie³,
Dr. Mohammad Zubair Ansari⁴

¹(Department of orthodontics and dentofacial orthopaedics, Dr Ziauddin Ahmad Dental College/ Aligarh muslim University, India)

²(Department of orthodontics and dentofacial orthopaedics, Dr Ziauddin Ahmad Dental College/ Aligarh muslim University, India)

³(Department of orthodontics and dentofacial orthopaedics, Dr Ziauddin Ahmad Dental College/ Aligarh muslim University, India)

⁴(Department of orthodontics and dentofacial orthopaedics, Dr Ziauddin Ahmad Dental College/ Aligarh muslim University, India)

Corresponding Author: Dr. Irum Uzma Siddiquie

Abstract: This case report describes the diagnosis and treatment of impacted mandibular canine in a 14 year old male patient. Patient was treated by surgical exposure of the impacted tooth followed by orthodontic traction. The total time duration of the treatment was 22 months. Impacted teeth are defined as teeth that remain completely or incompletely embedded in the jawbone or mucosa for more than 2 years following physiological eruption time.¹ Canines play an pivotal role in functional occlusion and forms the foundation of an esthetic smile.

Keywords: Orthodontics, Orthodontic management, Mandibular impacted canine, Surgical exposure, Orthodontic positioning

Date of Submission: 09-02-2019

Date of acceptance: 23-02-2019

I. Introduction

Impacted teeth are defined as teeth that remain completely or incompletely embedded in the jawbone or mucosa for more than 2 years following physiological eruption time.¹ The prevalence of impacted maxillary canines is 0.9–2.2%, but mandibular canine impaction occurs less frequently.³ ⁴The occurrence of impaction and/or non-eruption of mandibular canines is unusual, with prevalence rates from 0.05 to 0.4%.⁶ The location of impacted mandibular canines are also more likely to be on the labial aspect of the dental arch than compared to maxillary canines.⁷⁸ There are several treatment options proposed for impacted mandibular canines including surgical removal, exposure and orthodontic alignment, transplantation and observation. Some authors believed that asymptomatic impacted teeth could be left in place, but in these patients a series of successive radiographs should be taken periodically.⁶

Bishara et al. suggested the following sequelae of canine impaction^{9 10}

- Labial or lingual malpositioning of the impacted tooth
- Migration of the neighboring teeth and loss of arch length
- External root resorption of the impacted tooth as well as the neighboring teeth
- Infection particularly with partial eruption resulting in pain and trismus
- Referred pain

The purpose of this paper was to describe the diagnosis and treatment of impacted mandibular canine by surgical exposure and orthodontic positioning of it in the jaw so as to achieve functionally stable and esthetic occlusion.

An 14 year old male patient with chief complaint of irregularly placed upper front teeth and mobile retained teeth and wanted to get the treatment done for the same. He was physically healthy and had no past history of medical or dental trauma. No signs or symptoms of temporomandibular joint dysfunction were noted at the initial examination. On extra oral examination it was observed that the patient had no gross asymmetries. Patient had a mesoprosopic face with convex profile and competent lips and deep mentolabial

sulcus. The smile analysis revealed a reduced incisor display with a non-consonant smile and average buccal corridor space. (Fig.1)




Fig. 1:Pre- treatment Extra-Oral Photographs

On intra oral examination (Fig.2) it was observed that the patient had Class II division 2 incisor relationship and End-on molar relation on right side and Angle's Class I molar relation on left. Missing permanent canine and retained deciduous canine in the third quadrant. Maxillary arch showed spacing of 4mm while in mandibular arch spacing is of 1.6 mm. Overjet of 1mm and deep bite was present.

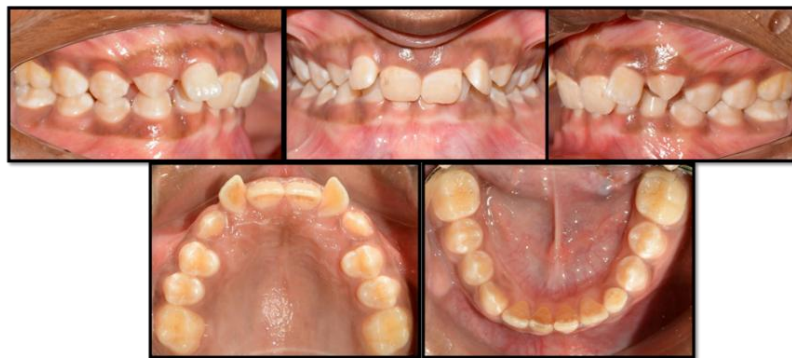

Fig. 1:Pre- treatment Intra-Oral Photographs

Cephalometrically (Fig.3) the patient had a Class II skeletal relationship (ANB angle: 5°) with wits of 1mm and MM bisector of -1mm . A horizontal growth pattern was seen (SN.GoGn: 20°). Maxillary incisors were retruded and retroclined with the upper incisor to NA at -1.5 and 18° . The lower incisors were retruded and retroclined and the lower incisor at 3mm and 20° to NB, with an IMPA of 93° . (Table 1).

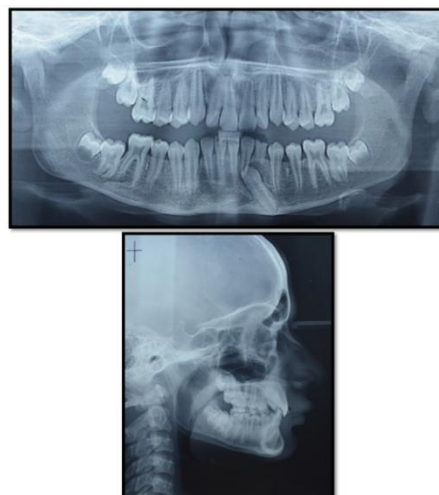


Fig. 3:Pre- treatment Lateral Cephalogram and OPG

	Pre-treatment
SNA	83°
SNB	79°
ANB (3.12°±1.8°)	4°
Wits (-0.01mm)	1mm
FMA (23.83±2°)	17 °
SN-MP (32-35°)	20 °
Y Axis (59.62°±3)	51 °
Gonial angle (123±7°)	122 °
Upper anterior facial height (45%)	51%
Lower anterior facial height (55%)	49%

Table 1-Pre-treatment Cephalometric Findings Shows-Skeletal Class II Pattern With Hypodivergent Growth Pattern

Mx 1 to NA:(4.92±2.05mm)	-1.5mm
Mx 1 to NA:(24.02±5.82°)	12 °
Md 1 to NB (6±1.7mm)	0 mm
Md 1 to NB (27±4.3 °)	16 °
IMPA (108°)	93°
Inter-incisor Angle (123°)	149 °

Table 2-Pre-treatment Cephalometric Dentoalveolar Findings :Retruded And Retroclined Upper And Lower Anteriors

The panoramic radiograph showed all permanent teeth, including the maxillary and mandibular unerupted third molars. The mandibular left canine was impacted and retained C in third quadrant. The labial position of the impacted mandibular canine was confirmed with the help of CBCT imaging. (Fig. 4).

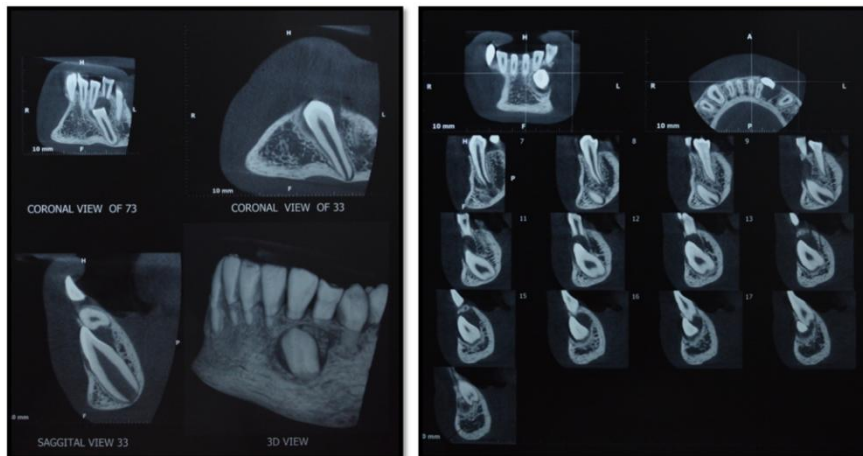


Fig. 4:CBCT Image Confirming The Buccal Position Of Impacted Mandibular Left Canine

II. Treatment objectives were to

- Align and level the maxillary and mandibular dental arches
- Surgical exposure of 33 followed by orthodontic traction
- Obtain normal overjet and overbite
- Achieve bilateral Class I canine occlusion
- Achieve bilateral Class I molar occlusion and attain optimum soft tissue relationship

III. Treatment Progress

The aesthetic concern and the patient's desire recalled in for a challenging solution for an unusual impacted mandibular canine treatment to align into its ideal position in the arch. On considering the diagnostic criteria, treatment plan was formulated for the patient involving surgical uncovering of the impacted mandibular canine followed by traction. The treatment was initiated using an MBT-022X028" slot pre-adjusted edgewise appliance. Initially in the maxillary arch a utility arch was placed to correct the Class II Division 2 incisor relation, and bonded anterior bite plate was placed, after the correction of incisor relation continuous wire was progressed in the upper arch. Archwires was progressed from flexible NiTi wires to stiffer Stainless Steel wire. Progression of wire in the sequence of 0.016", 0.018", 0.016 x 0.022" and 0.019 x 0.025" NiTi wires and 0.019 x 0.025" Stainless Steel wires was used. While in the lower arch extraction of retained C and surgical exposure of lower left canine was done (Fig. 5). Surgical exposure was carried out under local anesthesia. An attachment with a pigtail ligature wire was bonded to the canine during the procedure and flap was closed. A lingual holding arch was placed in the lower arch to maintain space. The ligature wire of piggy tail was tied to the main archwire as we progressed to stainless steel wire and orthodontic traction was applied. Settling was done with 0.014" Stainless Steel archwire. This entire orthodontic procedure took 22 months.

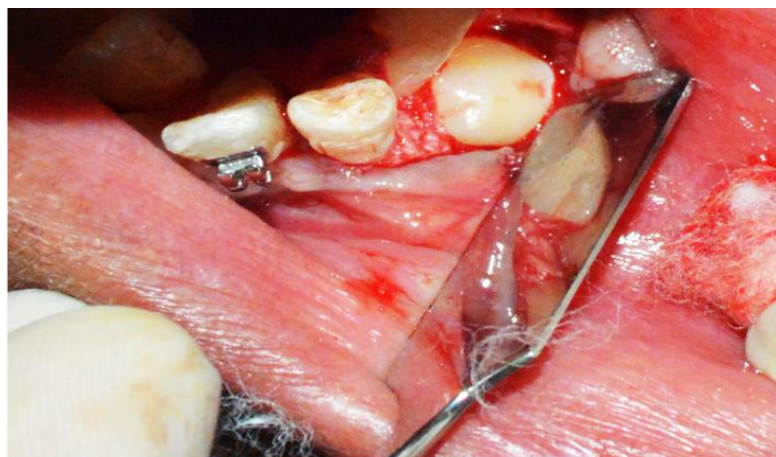

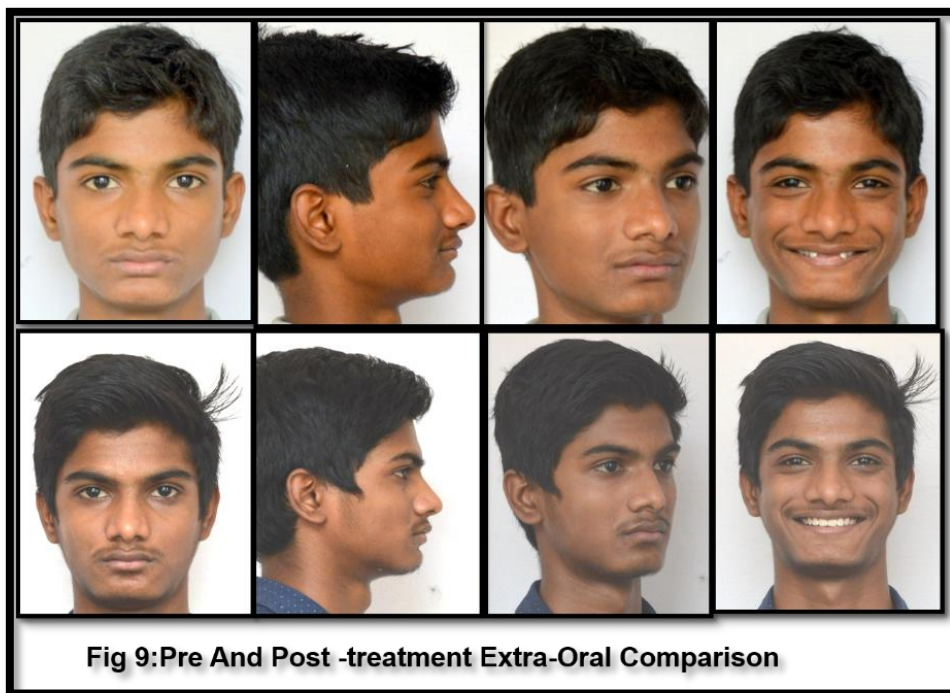
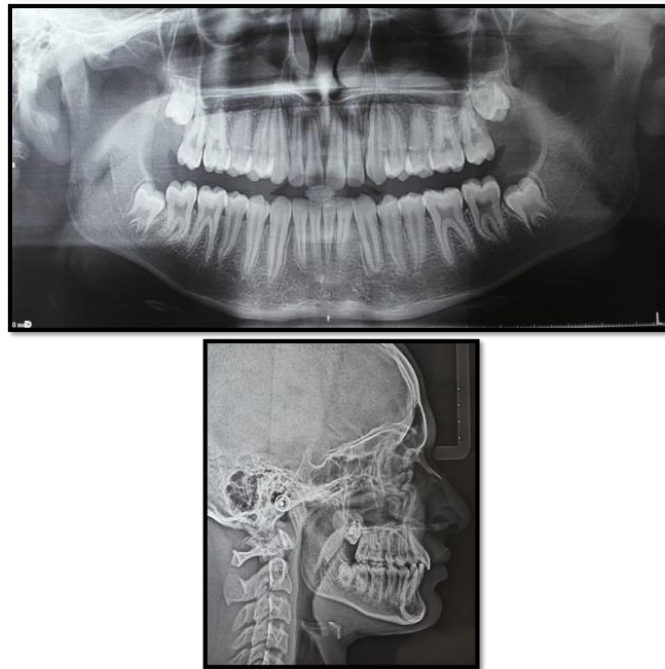
Fig. 5: Surgical Exposure of Lower Left Canine

IV. Treatment results

The facial aesthetic was improved with better lip support (Fig.6). The smile was enhanced and the consonant smile arc was achieved. Intraorally, ideal overjet and overbite was achieved with Class I molar and canine relationship (Fig.7). The post treatment panoramic radiograph showed good overall root parallelism and lack of root resorption. Post treatment lateral Cephalogram (Fig.8) showed satisfactory improvement in ANB angle by 1° and improvement in mandibular position (SNB: 80°). The position of upper and lower incisors were improved, upper incisor at 28° and 4mm to NA and the lower incisor at 26° and 4.5mm to NB with an IMPA of 101°. A favorable change in facial profile angle was seen. A functionally stable and esthetic occlusion was achieved during a period of 22 months. (Table 3 and 4)

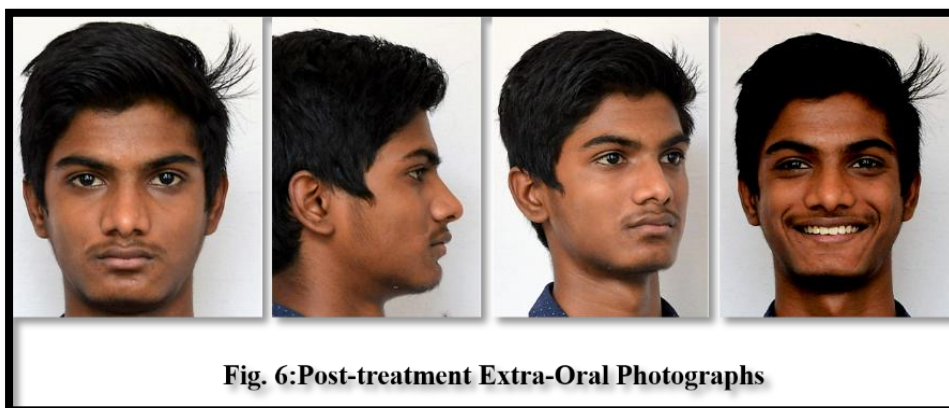

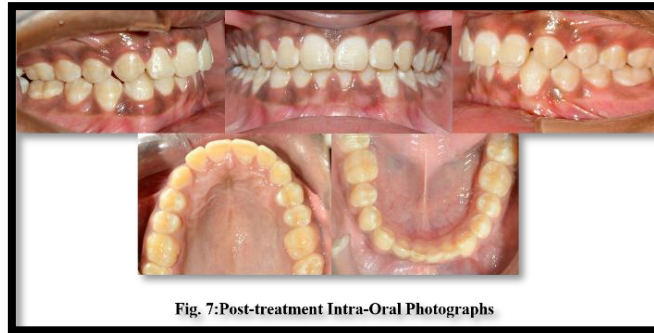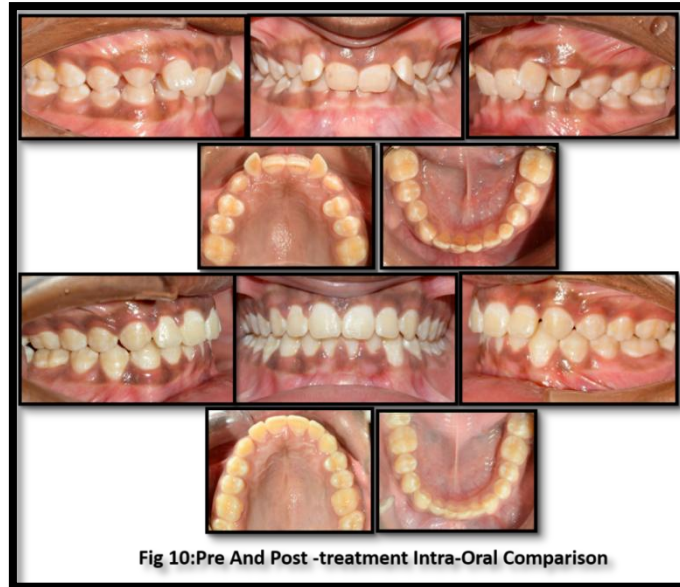Fig. 6: Post-treatment Extra-Oral Photographs





	Post-treatment
SNA	83°
SNB	80°
ANB (3.12°±1.8°)	3°
Wits (-0.01mm)	1mm
FMA (23.83±2°)	19 °
SN-MP (32-35°)	22°
Y Axis (59.62°±3)	54 °
Gonial angle (123±7°)	122 °
Upper anterior facial height (45%)	46.5%
Lower anterior facial height (55%)	53.5%

Table 3-Post-treatment Cephalometric Findings

Mx 1 to NA:(4.92±2.05mm)	4mm
Mx 1 to NA:(24.02±5.82°)	28 °
Md 1 to NB (6±1.7mm)	4.5mm
Md 1 to NB (27±4.3 °)	26 °
IMPA (108°)	101°
Inter-incisor Angle (123°)	128 °

Table 4-Post-treatment Cephalometric Dentoalveolar Findings

V. Discussion

The most important step in the management of impacted teeth is the diagnosis and localization of impacted teeth. Failure of eruption of the mandibular canine is an unusual event.^{8 11} There are limited number of studies revealing the frequency of occurrence of mandibular canine impactions and is regarded as a much rarer phenomenon. Failure of tooth eruption may be the consequence of local factors or systemic factor. Local factors may include mechanical obstruction (by a supernumerary tooth, cyst, or tumor); insufficient space in the dental arch or to the premature loss of deciduous teeth or a tooth arch size discrepancy. Systemic factors such as genetic disorders, endocrine deficiencies, and previous irradiation of the jaws are also associated with a failure of tooth eruption. In systemic conditions multiple teeth are usually impacted. In most cases, however, the specific cause of failure of eruption remains unknown¹². Delayed tooth eruption can cause necrosis of the pulp, ankylosis and external apical root resorption. It is difficult to predict when resorption will start. Thus, all impacted teeth should

be regarded as having a high risk of external apical root resorption or damage to the adjacent tooth. So, radiographic examinations should be used to monitor these risks. Commonly, orthopantomograph is used.^{13 14} In our case, the canine was in favorable position, and since canines are considered important keystones in the dental arch, we decided to orthodontically bring it into its ideal position. Management of impacted canines is often challenging situation for an orthodontist. The distance between canine tip and occlusal plane, long axis inclination of the lateral incisor, and mesiodistal location are strongly correlated with the treatment duration. Two common methods that have been considered for impacted canines are the closed- eruption technique and the open- eruption technique in this case closed eruption technique was planned. Sufficient space should be created prior to application of traction forces to the canine. A rigid stainless steel working wire is required before the traction is applied to prevent undesirable effects on the neighbouring dentition. The treatment difficulty and probability of complications, which interfere with duration of the traction, are related to age, occlusal movement, apical movement, angulation and mesiodistal location of the impacted canine's crown, complex relationship between canine's crown and midline, close contact between canine's incisal facet and adjacent lateral incisor, and presence of transposed lateral incisor or first premolar.¹⁵ All the advantages and disadvantages of surgical and orthodontic repositioning as well as the risks (including that of being unable to achieve the desired goals) and the need for good cooperation were discussed, and these were understood and accepted by the patient.

VI. Conclusion

The impacted canine must be localized prior to the treatment for better access during the surgical exposure. Our results showed a satisfactory improvement in ANB angle and a pleasing external soft tissue profile was achieved. Ideal dental relationships were obtained. The combined effect of surgical exposure of impacted mandibular canine and orthodontically correcting its positing was instrumental in reestablishing the major components of a balanced smile for this patient, whose main concern was his unpleasant smile.

Reference

- [1]. Bass TB. Observations on the misplaced upper canine tooth. *Dent Pract Dent Rec* 1967;18:25-33.
- [2]. Richardson G, Russel I KA. A Review of Impacted Permanent Maxillary Cuspids: Diagnosis and Prevention. *J Can Dent Assoc* 2000; 66:497-501
- [3]. D'Amico RM, Bjerklin K, Kurol J, Falahat B. Long-term Results of Orthodontic Treatment of Impacted Maxillary Canines. *Angle Orthod* 2003; 73:231-238.
- [4]. Aydin U, Yilmaz HH, Yildirim D. Incidence of canine impaction and transmigration in a patient population. *Dentomaxillofac Radiol* 2004; 33:164-9.
- [5]. Alaejos-Algarra C, Berini-Ayres L, Gay-Escoda C. Transmigration of mandibular canines: Report of six cases and review of the literature. *Quintessence Int*. 1998; 29:395-398.
- [6]. Brown LH, Berrkman S, Cohen D, Kaplan AL, Rosenberg MA. A radiological study of the frequency and distribution of impacted teeth. *J Dent Assoc S Afr*. 1982;37:627-30.
- [7]. Fonseca JR. *Oral and Maxillofacial Surgery*. Philadelphia: W.B. Saunders, 2002;1:342-71.
- [8]. Monika R, Mahesh G, Nikhi M. Bilateral Mandibular Canine Impaction: A Rare Case Report. *Journal of Oral Health and Community dentistry*. 2009;3(2):38-4
- [9]. Bishara SE, Kommer DD, McNeil MH, Montagano LN, Oesterle LJ, Youngquist W. Management of impacted canines. *Am J Orthod* 1976; 69:371-87.
- [10]. Bishara SE. Impacted maxillary canines. *Am J Orthod Dentofac Orthop* 1992; 101:159-71
- [11]. Camilleri S, Scerri E. Transmigration of mandibular canines – A review of the literature and a report of five cases. *Angle Orthod* 2003;73:753-62.
- [12]. Fonseca JR. *Oral and Maxillofacial Surgery*. Philadelphia: W. B. Saunders, 2000; Vol. 1:342-371.
- [13]. Kavadia-Tsatala S, Tsalikis L, Kaklamanos EG, Sidiropoulou S, Antoniadis K. Orthodontic and periodontal considerations in managing teeth exhibiting significant delay in eruption. *World J Orthod*. 2004;5:224-229.
- [14]. Peck S. On the phenomenon of intraosseous migration of nonerupting teeth. *Am J Orthod Dentofacial Orthop*. 1998;113:515-517.
- [15]. Cati G, Ghobadlu J, Nieri M, Clauser C. Factors associated with the duration of forced eruption of impacted maxillary canines: a retrospective study. *Am J Orthod Dentofacial Orthop*. 2006; 130: 349-56.

Dr. Jiju Mohan. "Orthodontic Management of A Mandibular Impacted Canine: Case Report."
IOSR Journal of Dental and Medical Sciences (IOSR-JDMS), vol. 18, no. 2, 2019, pp 61-67.