

## Significance of p53 Gene Expression and Its Correlation with Various Clinico-Pathological Parameters in Head and Neck Squamous Cell Carcinomas

Chinmayee Panigrahi<sup>1</sup>, Pranati Misra<sup>2</sup>, Kanakalata Dash<sup>3</sup>

<sup>1</sup>Post- graduate student , Department of Pathology, Kalinga Institute of Medical Sciences and Pradyumna Bal Memorial Hospital, Bhubaneswar, Odisha, India

<sup>2</sup>Assistant Professor, Department of Pathology, Kalinga Institute of Medical Sciences and Pradyumna Bal Memorial Hospital, Bhubaneswar, Odisha, India

<sup>3</sup>Professor, Department of Pathology, Kalinga Institute of Medical Sciences and Pradyumna Bal Memorial Hospital, Bhubaneswar, Odisha, India  
Corresponding Author: Pranati Misra

### Abstract

**Background:** Head and neck cancers are one of the leading cancers by incidence and mortality worldwide, mostly involving the mouth and oropharynx. Despite intense research, its 5-year survival rate remains low. p53 expression has been studied extensively in head and neck squamous cell carcinomas but its utility as a prognostic biomarker is still unclear.

**Aim:** Assessment and clinicopathological correlation of p53 expression in head and neck squamous cell carcinoma.

**Methods:** This prospective study was conducted at Kalinga Institute of Medical Sciences and Pradyumna Bal Memorial Hospital, Bhubaneswar, Odisha in the Department of Pathology for a period of two years and 56 cases were included. p53 expression and its correlation with the various clinicopathological parameters was studied by IHC. The obtained results were analyzed using chi-square test and a p-value of <0.05 was considered significant.

**Results:** In this study out of 56 cases of head and neck squamous cell carcinomas, p53 expression was found in 37 (66.07%) cases. A significant correlation was found between p53 expression and site of origin of the tumour ( $p=0.014$ ) as well as nodal metastasis ( $p=0.039$ ). p53 expression did not show any significant correlation with age, sex, the risk factors (alcohol consumption, paan chewing and smoking), grade or tumor staging.

**Conclusion:** p53 expression was observed in majority of cases originating from buccal mucosa and it may serve as a predictor of lymph node metastasis and eventual aggressiveness in head and neck squamous cell carcinomas.

**Keywords:** head and neck , p53 , prognosis , squamous cell carcinoma

Date of Submission: 08-02-2019

Date of acceptance: 23-02-2019

### I. Introduction

Cancer had been known to mankind since ancient times as it has a great impact on human life.<sup>(1)</sup> Approximately 6,30,000 new cases of head and neck squamous cell carcinomas (HNSCC) are diagnosed annually with 3,50,000 deaths reported every year.<sup>(2)</sup> About 90% of all head and neck cancers are squamous cell carcinoma. Among all the cancers in the human body oral squamous cell carcinoma (OSCC) consistently ranks as the top six cancers worldwide<sup>(3,4)</sup> and top three types of cancer in India.<sup>(5)</sup> HNSCC occurs at various anatomical sites in the head and neck including oral cavity and oropharynx. They typically occur in elderly patients in the fifth to seventh decade of life, but it can also affect young individuals under 40yrs of age with devastating socioeconomic and psychological consequences at the prime of their lives.<sup>(6)</sup>

HNSCC has multifactorial aetiologies such as tobacco smoking, betel quid chewing, alcohol intake, actinic radiation, poor oral hygiene, viral infections (Epstein-Barr virus, HPV, and herpes simplex virus), occupational exposure to carcinogens, immunodeficiency and genetic predisposition.<sup>(7)</sup> In South Asian countries such as India chewing of betel quid or paan is the predominant risk factor. Approximately half of all patients with HNSCC have advanced stage disease at the time of diagnosis, with an expected 5-year survival rate between 10 and 40%.<sup>(8)</sup> Various molecular abnormalities have been proposed in pathogenesis of HNSCC including p53 gene mutation. p53 is the guardian of genome and a tumour suppressor gene, located on the chromosome 17p13.1. It regulates the cell cycle progression, DNA repair, cellular senescence, apoptosis and is the most frequently mutated gene in human cancers. The prevalence of TP53 mutations is 50-69% in HNSCC

and expression of p53 protein in oral premalignant lesions may indicate impending malignancy. Majority of p53 gene mutation are point mutations leading to loss of tumor suppression.<sup>(9)</sup> Although there are numerous studies on role of p53 in oral carcinogenesis its role as prognostic biomarker is still controversial.<sup>(10)</sup> The present study was undertaken to study the expression of p53 in HNSCC and to correlate its expression with various clinicopathological parameters.

## **II. Material and Methods**

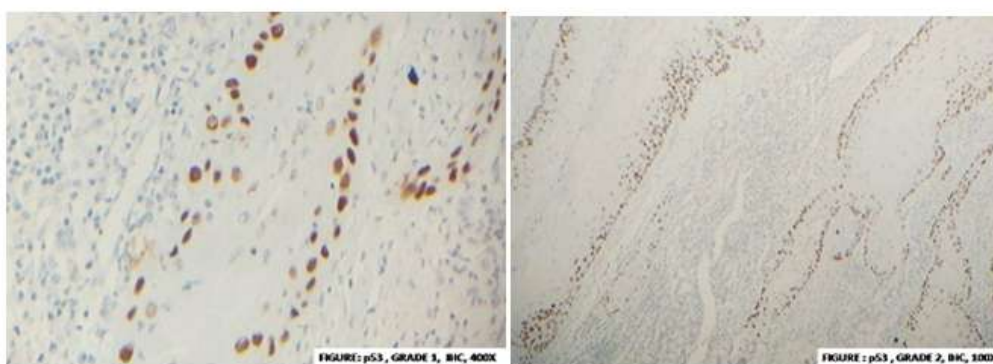
The present study was conducted in our hospital during the period of 2016-2018. In this prospective study, 56 cases of HNSCC with wide local excision and neck node dissection pertaining to oral cavity, oropharynx, hypopharynx and larynx were studied. 10 samples of normal oral mucosa were taken from known cases of HNSCC, which served as normal control. Recurrent cases of HNSCC or patient on/prior treatment with radiotherapy and chemotherapy were excluded from the study. Detail demographic data along with history of various risk factors like tobacco chewing, pan chewing, and alcohol abuse were obtained.

Specimens were fixed overnight in 10% buffered formalin and processed. Grossing of the specimens was done as per the AJCC guidelines.<sup>(11)</sup> Four to five micrometer thick, paraffin embedded tissue sections were subjected for Haematoxylin and Eosin staining. Histologic examination was performed and typing & grading of tumor was done as per the criteria outlined in the World Health Organization (WHO) classification of tumours.<sup>(12)</sup> into Grade I: Well-differentiated, Grade II: Moderately differentiated and Grade III: Poorly-differentiated or anaplastic. Staging of cancer was done according to American Joint Committee on cancer definition of primary tumor.<sup>(11)</sup>

Tissue microarrays were constructed to study p53 expression by immunohistochemistry (IHC). Tissue microarrays are composite paraffin blocks prepared by taking out cylindrical tissue core biopsies from different paraffin donor blocks and re embedding them into a single recipient block.<sup>(13)</sup> After selecting the area of interest in H&E stained sections from the tumor and extracting the corresponding tissue cores using bone marrow trephine biopsy needle from donor blocks they were embedded in recipient blocks. Thus four tissue microarray blocks were prepared. Immunohistochemical analysis for p53 on tumor tissue was done using antibody to p53 [ (clone-BP53-12-1; catalog no.AM195-2) from Biogenex, USA] on 4 µm thick sections from paraffin-embedded tissue microarray blocks, according to streptavidin-biotin immunoperoxidase technique. Positive and negative controls were run simultaneously. Positive control slide was prepared from carcinoma breast known to be positive for p53. Negative control slide was prepared from the same tumour block under study by omitting the primary antibody. Five different areas were evaluated and the immune-expression limit was set at 25% i.e. the TP53 gene mutation was considered positive if 25% or >25% of the tumor cells showed nuclear staining for p53 protein. Further grading was done according to the number of cells that showed positive nuclear staining (Grade1-25%, Grade 2-25-50%, Grade3-50-75%, Grade4-75-100% cells showing positive nuclear expression). The most densely stained area was considered for grading.<sup>(14)</sup> (Figure 1a,b &c)

Analysis of the p53 immunohistochemical expression and its relation with various parameters like age, sex, history of addiction, site of tumor, histological grade and pathological staging was done.

Statistical analysis was done using SPSS software. The relationship between qualitative parameters was determined using the chi – square test. Statistical significance was defined as  $p < 0.05$ .



**Figure 1 a**

**Figure 1 b**




Figure 1 c

### III. Results

The present study was conducted over a period of two years and a total of 56 cases were included. The patients were in the age range 26 - 83 years with a mean age of 52.9 years. The highest number of cases (15/56) belonged to the age group 60-69 years followed by the age group of 50-59 years with (12/56) cases. Out of the 56 cases, 43 (76.79%) were males and 13 cases were females (23.21 %) with a male to female ratio 3.3:1.

In majority of cases the tumor originated from buccal mucosa(22/56) followed by tongue(21/56). Other sites involved were lower alveolus, lip & larynx. For statistical analysis lower alveolus, lip, larynx and tonsil cases were clubbed in one group. Out of 56 patients 53.57% (30/56) were addicted to tobacco, 35.71% (20/56) were habituated for alcohol consumption and 57.14% (32/56) in paan chewing.

In this study, majority of tumors belong to Grade I (71.43%) whereas Grade II constitutes only 26.8% of cases. We did not encounter any Grade III tumor in our study.

Maximum cases belong to stage T2 with 35.71%(20/56) cases followed by T4 with 32.14%(18/56). Nodal metastasis was found in 59% (33/56) cases, of which 30.36% cases belonged to N1 and 28.57% cases belong to N2. 41.07% (23/56) cases did not have any nodal metastasis. While doing statistical analysis N1 & N2 were grouped together as Node positive cases.

It was observed that out of 56 cases, 36 (64.28 %) were p53 positive. No statistically significant correlation was found between p53 expression and age ( $p = 0.152$ ) or gender ( $p = 0.694$ ). Most of the cases of HNSCC were found to arise from buccal mucosa and 86.96 % of these showed positive p53 immunorexpression ( $p = 0.014$ ). (Table-1)

**Table 1:** Correlation of p53 expression with various clinical parameters

PARAMETERS	P53 Expression		P value
	Positive	Negative	
Age (Mean $\pm$ SD) in years	54.32 $\pm$ 14.33	48.47 $\pm$ 14.15	0.152
Sex			0.694
Female (13)	8 (61.54%)	5 (38.46%)	
Male (43)	29 (67.44%)	14 (32.56%)	
SITE			<b>0.014</b>
Buccal mucosa (22)	20 (86.96%)	3 (13.04%)	
Tongue (21)	12 (57.14%)	9 (42.86%)	
Other (13)	5 (25.10%)	7 (53.85%)	

**Table-2:** Percentage p53 expression in relation to exposure to risk factors

PARAMETERS	P53 Expression		P value
	Positive	Negative	
H/o alcohol consumption			0.900
No (36)	24 (66.67%)	12 (33.33%)	
Yes (20)	13 (65%)	7 (35%)	
H/O paan chewing			0.073
No (24)	19 (79.17%)	5 (20.83%)	
Yes (32)	18 (56.25%)	14 (43.75%)	
H/O tobacco smoking			0.505
No (26)	16 (61.54%)	10 (38.46%)	
Yes (30)	21 (70%)	9 (30%)	

In 18 cases (56.25%) with a habit of pan consumption, 30 cases (70%) addicted to tobacco smoking and 20 cases (65%) habituated in consuming alcohol p53 expression was found to be positive .But this was not statistically significant ( $p = 0.073, 0.505, 0.900$  respectively). (Table -2)

With increase in tumor grade p53 expression was found to increase but this was statistically insignificant ( $p = 0.534$ ). (Table -3)

**Table 3:** Correlation of p53 expression with histological grading

GRADE OF TUMOR	P53 Expression		P value
	Positive	Negative	
GRADE I (40)	25 (62.5%)	15 (37.5%)	0.534
GRADE II (16)	12 (75%)	4 (25%)	

**Table 4:** Correlation of p53 expression with depth of invasion

DEPTH OF INVASION	P53 Expression		P value
	Positive	Negative	
T1 (8)	5 (62.5%)	3 (37.5%)	0.861
T2 (20)	12 (60%)	8 (40%)	
T3 (10)	7 (70%)	3 (30%)	
T4 (18)	13 (72.22%)	5 (27.78%)	

**Table 5:** Correlation of p53 expression in the primary tumor with lymph node metastasis

LN metastasis	P53 Expression		P value
	Positive	Negative	
Negative (23)	14 (60.87)	9 (39.13)	<b>0.039</b>
Positive (33)	23 (69.69%)	10 (30.3%)	

Though we did not find any statistically significant correlation between p53 expression and depth of invasion ( $p = 0.861$ ) (Table-4) but significant correlation was found between p53 expression and nodal metastasis with a  $p$  value of  $<0.05$  ( $p=0.039$ ). (Table-5)

#### IV. Discussion

Squamous cell carcinomas represent a bulk of the cancers related to the head and neck originating from the squamous epithelial lining of the upper airways, oral and digestive system. The incidence of these HNSCCs is on the rise in the Indian subcontinent with new patients being diagnosed every day.<sup>(15,16)</sup> Hence continuous research is going on to find out methods for early detection and to find out drugs for targeted therapy to improve the survival rate.

P53 is an important regulator of the G2/M transition and it blocks entry into mitosis by inhibition of CDC2 and by repression of cycling B1 gene causing malignant transformation of cell.<sup>(9)</sup> Thus p53 expression may serve as a biomarker in HNSCC cases.

This study was designed with the primary objective of finding the p53 expression in HNSCC and to correlate its expression with various clinical and pathological parameters.

In our study immunopositivity of p53 was found in 37 (66.07%) cases. Similar results were found in study done by Kaur J et al<sup>(17)</sup> with 64% cases. Still higher expression was found in study done by Dragomir et al<sup>(18)</sup> with 82.3% of cases. Yuen PW et al<sup>(19)</sup> conducted their study on 87 cases and found p53 expression in 52% cases, while Smith et al<sup>(20)</sup> in their study found p53 expression in only 48% cases.

P53 positivity was seen in 29/43 (67.44%) males and 8/13 (61.54%) females. No statistical significant correlation was found between p53 expression with age or gender ( $p = 0.152$ ,  $p = 0.694$  respectively).

With respect to various anatomical sites, highest p53 immunoexpression was seen in buccal mucosa accounting for 20/22 (86.96%) cases. A statistically significant correlation was found between p53 expression and carcinomas arising from buccal mucosa ( $p$  value of **0.014**) (Table-1). But unlike ours, Yuen PW et al<sup>(19)</sup> and Winata et al<sup>(21)</sup> found p53 expression in 45% and 50% respectively in tumors arising from tongue. Majority of the cases included in the present study were habituated for paan chewing but p53 expression was found in 18(56.25%) cases. Marked increase in p53 expression was found in cases those addicted to tobacco(70%)(Table-2). However, it was statistically insignificant. Dragomir et al<sup>(18)</sup> found increased expression of p53 in 85.3% patients addicted to smoking whereas Smith et al<sup>(20)</sup> reported p53 expression in 49.1% of cases in patients addicted to tobacco smoking and 32.7% of cases addicted to alcohol consumption. None of these finding were statistically significant.

With increasing grade p53 expression was found to be increased but it was not statistically significant ( $p = 0.534$ )(Table 3) in our study which is similar to the studies by Winata et al<sup>(21)</sup> ( $p = 0.01$ ) and Kaur J et al<sup>(17)</sup> ( $p = 0.001$ ).

We could not find any statistical significance between p53 expression and depth of invasion( $p=0.861$ ) (Table-4).This was in contrast to study by Kaur J et al<sup>(17)</sup> who observed a statistically significant correlation with a  $p$  value of 0.009.This is probably because of small sample size. Our study was in accordance with study done by Winata et al<sup>(19)</sup> with expression of p53 being highest in cases belonging to T4 stage (72.22%) (Table-4).

Lymph node metastasis is a parameter in the AJCC tumor staging system.<sup>(12)</sup> P53 expression, was seen in 23 (69.69%) cases in which lymph node metastasis was present and it was statistically significant ( $p = 0.039$ ) (Table-5). This is in accordance with study done by Kaur J et al<sup>(17)</sup> and Winata et al<sup>(19)</sup> in which they found p53 expression in 73% and 73.1% cases respectively having lymphnode metastasis and this was statistically significant.

In this study however there were some limitations like small sample size, lack of enough number of moderately and poorly differentiated SCC cases and a shorter duration of study for which the patients could not be followed up. We did not do any ancillary tests to confirm the HPV status which has an important role in pathogenesis of HNSCC.

## V. Conclusion

The role of p53 gene expression as a biomarker in HNSCC has not been clearly established. However, in our study, p53 expression was significantly higher in carcinomas arising from buccal mucosa. p53 positive tumors were frequently associated with lymphnode metastasis with statistically significant results. We did not find any significant association with any risk factors or with grade of tumor however p53 positive tumors were more frequently of higher histological grade. Hence, further large scale studies need to be undertaken in future to evaluate the efficacy of p53 expression as a prognostic indicator in Head and Neck Squamous cell carcinomas.

## References

- [1]. Sudhakar A. History of cancer, ancient and modern treatment method. *J Cancer Sci Ther* 2009; 1(2):1-4
- [2]. Siegel R, Naishadham D, Jemal A. Cancer statistics, 2013. *CA Cancer J Clin.* 2013; 63(1):11-30.
- [3]. Jemal A, Siegel R, Ward E, Murray T, Xu J, Thun MJ. Cancer statistics. *CA Cancer J Clin.* 2007; 57(1):43-66.
- [4]. Boyle P and Bernard Levin. World Cancer Report 2008. International Agency for Research on Cancer.
- [5]. Elango JK, Gangadharan P, Sumithra S, Kuriakose MA. Trends of head and neck cancers in urban and rural India. *Asian Pac J cancer Prev* 2006; 7:108-12.
- [6]. Ralli M, Singh S, Yadav S, Sharma N, Verma R, Sen R. Assessment and clinicopathological correlation of p16 expression in head and neck squamous cell carcinoma. *J Can Res Ther* 2016;12:232-7
- [7]. Robbins and Cotran 's pathologic basis of disease, 9<sup>th</sup> ed.India: Elsevier 2014; 731-32.s
- [8]. Goldberg H, Lockwood S, Wyatt S, Crossett L. (1994) Trends and Differentials in Mortality from Cancers of the Oral Cavity and Pharynx in the United states, 1973-87. *Cancer* 74, 565-572.
- [9]. Olivier M, Hollstein M, Hainaut P. TP53 Mutations in Human Cancers: Origins, Consequences, and Clinical Use Cold Spring Harb Perspect Biol. 2010; Jan 2(1):a001008.
- [10]. Cuevas Gonzalez JC, Gaitan Cepeda LA, Borges Yanez SA, Cornejo AD, Mori Estevez AD, Huerta ER. p53 and p16 in oral epithelial dysplasia and oral squamous cell carcinoma: A study of 208 cases. *Indian J Pathol Microbiol* 2016;59:153-8.
- [11]. Ridge JA, Lydiatt WM, Patel SG, Glastonbury CM, Gensler MB, Ghossein RA, Shah JP. Lip and Oral cavity. *AJCC Cancer Staging Manual*. 8ed.Chicago: Springer: 2017. pp. 79-94.
- [12]. Barnes L, Chiosea SI, Seethala RR. Squamous cell carcinoma-variants. *Head and neck pathology*. 3 ed. New York: Demos medical publishing LLC; 2011. p. 1-18.
- [13]. Nazar M.T, Jawhar. Tissue Microarray: A rapidly evolving diagnostic and research tool. *Ann Saudi Med.* 2009 Mar-Apr; 29(2): 123-127.
- [14]. Cruz I, Snijders PJ, Van houten V, Vosjan M, Van der Waal I, Meijer CJ. Specific p53 immunostaining patterns are associated with smoking habits in patients with oral squamous cell carcinomas. *J Clin Pathol* 2002;55(11):834-840.
- [15]. Kalavathy Jayapal Elango *et al.* Role of Human Papilloma Virus in Oral Tongue Squamous Cell Carcinoma. *Asian Pacific J Cancer Prev*, 12, 889-896.
- [16]. Balaram P *et al.* Human Papilloma Virus in 91 oral cancers from Indian betel quid chewers – high prevalence and multiplicity of infections. *Int J Cancer*; 61: 450-454.
- [17]. Kaur J, Mannan R, Manjari M, Sharma S, Bhasin T, Kaur A. Can p53 expression and staining intensity correlate with histopathological prognostic parameter and clinical staging in head and neck squamous cell carcinoma?. *Journal of Pathology of Nepal* (2017) Vol 7, 1141-1148.
- [18]. Dragomir LP, Simionescu C, Margaritescu C, Stepan A, Dragomir IM, Popescu MR. p53, p16 and Ki-67 immunoexpression in oral squamous carcinomas. *Rom J Morphol Embryol* 2012;53:89-93
- [19]. Yuen PW, Chow V, Choy J, Lam KW, Ho KW, Wei WI. The Clinicopathologic Significance of p53 and p21 Expression in the Surgical Management of Lingual Squamous Cell Carcinoma. *Am J Clin Pathol* 2001; 116:240-245.
- [20]. Smith EM, Rubenstein LM, Hoffman H, Haugen TH, Turek LP. Human papillomavirus, p16 and p53 expression associated with survival of head and neck cancer. *Infect Agent Cancer* 2010;5:4.
- [21]. Wiñata A, Manuela I, Sugars I, Mahadewa T. Association of P53 Protein Overexpression with Clinicopathological Features of Oral Squamous Cell Carcinoma Patients in Bali. *Bali Medical Journal* 2016;5(1):59-64.

Pranati Misra. "Significance of p53 Gene Expression and Its Correlation with Various Clinico-Pathological Parameters in Head and Neck Squamous Cell Carcinomas." *IOSR Journal of Dental and Medical Sciences (IOSR-JDMS)*, vol. 18, no. 2, 2019, pp 70-74