

Solving the Mystery of Chronic Cough.

Kishan Prem¹, Sharanabasava², Bin Ramakanth³, Harsha D S⁴, Vishnu Sharma⁵

1. Post Graduate Resident Department of General Medicine

2. Post Graduate Resident Department of General Medicine

3. Post Graduate Resident Department of General Medicine

4. Associate Professor Department of Pulmonary Medicine

5. Professor and HOD Department of Pulmonary Medicine

A J Institute of Medical Sciences, Mangalore

Corresponding Author: Kishan Prem

KEY Words- Breast Carcinoma, Tuberculosis, Bronchiogenic Carcinoma, Chronic Cough, Pulmonary Metastasis

Date of Submission: 13-02-2019

Date of acceptance: 28-02-2019

I. Introduction

When a patient comes with chronic cough with previous history of carcinoma breast proper evaluation is required to find the cause

II. Case Report

A case of 56 year old female who was previously diagnosed with carcinoma breast in the year 2006 came with a history of dry cough, breathlessness and wheeze since 1 year, on examination patient was found to have no abnormal clinical findings, later Chest X-Ray was done which showed Ill-defined opacities in right upper and mid zone patient was later diagnosed to have pulmonary tuberculosis by GeneXpert and treated with Anti-Tubercular medication for 6 months. After treatment patient's symptoms had subsided but one month after completion of the treatment patient had similar symptoms and did not show any signs of improvement both clinically and radiologically, patient gives a past history of right mastectomy and axillary clearance along with chemotherapy and radiation, patient two years after surgery had also underwent PET-CT and recurrence was ruled out, in view of previous history of malignancy PET-CT was repeated to rule out metastases which showed metabolically active thickening of the right hilar mass with bronchial involvement. In order to know the pathology patient underwent bronchoscopy which showed fleshy lesion in right intermediate bronchus and biopsy was taken for histopathology which was suggestive of adenocarcinoma of lung with ER, PR positivity.

III. Discussion

Common causes of chronic cough are postnasal drip, asthma, acid reflux, infections, malignancy and side effects of drugs. Proper evaluation is required when a patient previously treated for breast carcinoma comes with history of chronic cough. Here the patient gives history of chronic cough with expectoration even after being treated for tuberculosis, various other investigation should also be done in order to rule out malignancy. Radiological investigations like PET-CT should be done to look for any malignancy and should be later confirmed by histopathology either by CTGuided Biopsy or Bronchoscopy. As endobronchial metastasis is rare [1-4], it is not usually a prime consideration when segmental or lobar abnormalities appear on chest radiographs. The diagnosis of metastatic disease may also be delayed by the lack of symptoms or evidence of metastatic disease elsewhere. In a consecutive series by Western Journal of medicine [8] endobronchial metastases were diagnosed for an incidence of 0.4 percent and the median latent interval from the diagnosis of the primary carcinoma until the time of diagnosis of endobronchial metastasis was 21 months [8]. Endobronchial metastasis occurs particularly in breast, kidney, colon and cervical carcinoma. The endobronchial appearance is generally one of mucosal oedema and thickening. The tumour usually involves the submucosal lymphatics rather than the surface of the mucosa. This probably explains the low incidence of positive bronchial cytology and emphasises the need for a deep mucosal biopsy [3-5]. Bronchoscopic and histological findings may be insufficient to distinguish primary from metastatic tumour on bronchus in some clinical situations [4-6]. In the present case, a history of the underlying disease and detailed immunohistochemical examination such as ER/PR was useful to arrive at a further appropriate diagnosis. DeBeer et al [7] reported probably the first case of carcinoma of the breast cancer metastasising to the mucosa of a major bronchus. Treatment of endobronchial

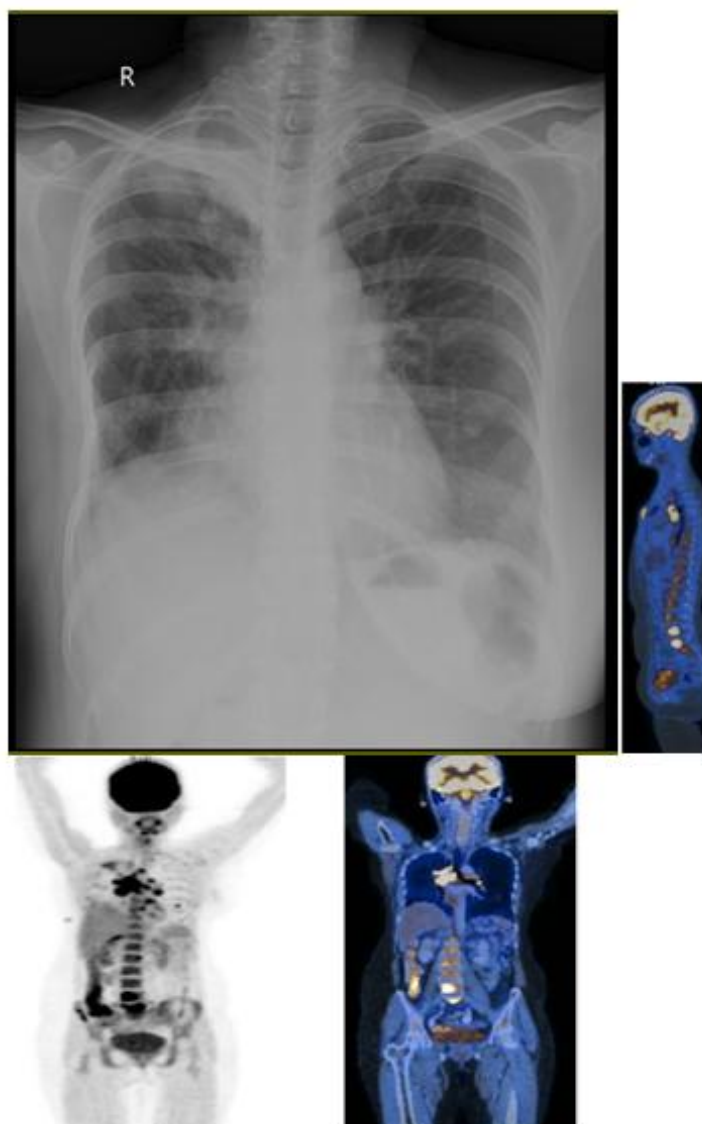
metastases must be planned according to the histology of the primary tumour, location of the lesion in the bronchial tree, number of lesions, evidence of other metastatic sites and medical status of the patient. Patients are usually treated with chemotherapy and radiotherapy.

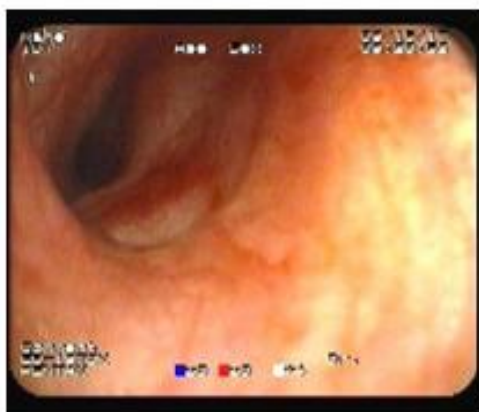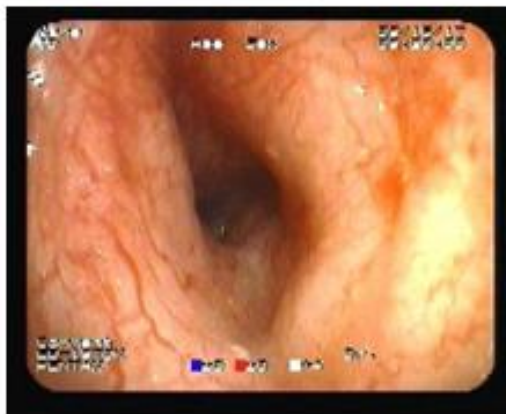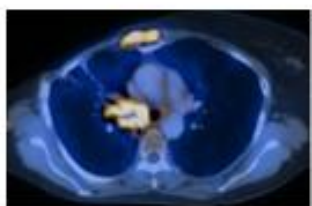
IV. Conclusion

Patient who are diagnosed with carcinoma breast coming with history of chronic cough with expectoration, necessary evaluation needs to be done to know the extent of the lesion in the lung parenchyma. Bronchoscopy should be done to confirm metastasis and to rule out pulmonary Tuberculosis

References

- [1]. Braman SS, Witcomb ME. Endobronchial metastases. *Arch Intern Med* 1975; 135: 543–7.
- [2]. Rovirosa Casino A, Bellmunt J, Salud A et al. Endobronchial metastases in colorectal adenocarcinoma. *Tumori* 1992; 78(4): 270–3.
- [3]. Shepherd MP. Endobronchial metastatic disease. *Thorax* 1982; 37: 362–5.
- [4]. Kiryu T, Hoshi H, Matsui E, Iwata H, Kokubo M, Shimokawa K, Kawaguchi S: Endotracheal/endobronchial metastases: clinicopathologic study with special reference to developmental modes. *Chest* 2001;119:768–775.
- [5]. Salud A, Porcel JM, Rovirosa A, Bellmunt J: Endobronchial metastatic disease: analysis of 32 cases. *J Surg Oncol* 1996;62:249–252.
- [6]. Akoglu S, Uçan ES, Celik G, Sener G, Sevinç C, Kiliç O, İtil O: Endobronchial metastases from extrathoracic malignancies. *ClinExp Metastasis* 2005;22:587–591.
- [7]. Jung JI, Kim HH, Park SH, Song SW, Chung MH, Kim HS, Kim KJ, Ahn MI, Seo SB, Hahn ST: Thoracic manifestations of breast cancer and its therapy. *Radiographics* 2004;24:1269–1285.
- [8]. Endobronchial Metastases in Breast Carcinoma- *Western Journal of medicine*





Kishan Prem. "Solving The Mystery of Chronic Cough." IOSR Journal of Dental and Medical Sciences (IOSR-JDMS), vol. 18, no. 2, 2019, pp 23-30.