

Papillary Carcinoma Thyroid Variants and Immunomarker Expression - An Additional Diagnostic tool

Dr.Sithy Athiya Munavarah¹., Dr.Hemalatha²., Dr. Suresh Durai J³.,
Dr.Johnsy Merla J^{4*}., Dr.Chandru Mari⁵., Dr.Shantaraman K⁶.

¹PG Director & HOD, Department of pathology, Karpaga Vinayaga Institute of Medical Sciences & Research Centre,

²Assistant Professor, Department of pathology, K.A.P Viswanatham Medical College Trichy., ³Professor, Department of pathology, Tirunelveli Medical College, ^{4,5} Assistant Professor, Department of pathology, Tirunelveli Medical College.

⁶ Professor & HOD, Department of pathology, Tirunelveli Medical College.

*Corresponding Author: Dr.Johnsy Merla

Abstract: The incidence of thyroid cancers is on the rise during the recent years with 80% of thyroid malignancies constituted by papillary carcinoma thyroid. The histopathological diagnosis of papillary carcinoma thyroid is easier in typical cases. The two commonly used markers cytokeratin 19 and HBME-1 (Hector Battifora mesothelial 1) can be of great help in grey areas where H&E diagnosis is challenging. A total of 30 cases diagnosed as papillary carcinoma thyroid were included in the study. Most common variant observed in this study was the classical variant (19 cases, 63.33%). Scoring of CK 19 expression based on the percentage of positively stained cells was done. The classical variant showed 4+ positivity in 16 cases (84.21%), 3+ positivity in 2 cases (10.52%) and 2+ positivity in 1 case (5.26%). In the follicular variant 3 cases (50%) showed 4+ positivity, 2 cases (33.33%) showed 3+ positivity and only 1 case (16.6%) showed 2+ positivity. The columnar cell variant showed 3+ positivity. All other variants showed 4+ positivity. In non-neoplastic areas pseudopapillary foci were either negative or weakly positive. HBME-1 showed 4+ positivity in 11 cases (57.89%) of classical variant, 3+ positivity in 3 cases (15.78%) and 2+ positivity in 4 cases (21.05%). In the follicular variant, 1 case (16.66%) showed 2+ positivity, 1 case (16.66%) showed 3+ positivity and 3 cases (50%) showed 4+ positivity. The intracystic variant showed 3+ positivity in 1 case and 2+ positivity in 1 case. All other variants showed 4+ positivity. Associated benign lesions did not show HBME-1 expression. Among the variants both the markers showed positive staining. Therefore, a combined immunostaining with CK19 and HBME1 increases the diagnostic accuracy in papillary thyroid carcinoma.

Keywords: CK 19 expression, HBME-1 expression, Papillary carcinoma thyroid, Thyroid cancers, Variants.

Date of Submission: 25-01-2019

Date of acceptance: 07-02-2019

I. Introduction

The incidence of thyroid cancers is on the rise during the recent years due to quicker diagnosis and recognition of micrometastasis. The most common well differentiated tumor arising from the follicular epithelial cells is papillary carcinoma thyroid^{1,2}. 80% of thyroid malignancies is constituted by papillary carcinoma thyroid.³ The histopathological diagnosis of papillary carcinoma thyroid is easier in typical cases. Difficulty in diagnosis arises when there is focal presence of nuclear features or in the absence of typical architecture such as in follicular variant of papillary carcinoma thyroid. The approach to these challenging lesions should include ancillary techniques such as immunohistochemistry. A panel of markers is usually suggested because no single marker is specific or sensitive for identification of papillary thyroid carcinoma. However cost effectiveness is a major concern. The two commonly used markers cytokeratin 19 and HBME-1 (Hector Battifora mesothelial 1) can be of great help in grey areas where H/E diagnosis is challenging. Even though histopathology remains the gold standard for the diagnosis of papillary carcinoma thyroid, controversy arises in cases which have no papillary architecture and questionable nuclear features.

II. Materials and Methods

This study was conducted in the Department of Pathology, Tirunelveli Medical college. A total of 30 cases diagnosed as papillary carcinoma thyroid were included in the study. Cases of papillary carcinoma thyroid diagnosed by histopathological examination were selected and sub typed and representative blocks were taken. Immunostaining of the sections taken from the representative block was done with CK 19 and

HBME1 .

CK 19 immunostaining was done using monoclonal mouse antibody – DAKO, clone RCK 108, isotype IgG₁ kappa. Normal colonic tissue was taken as positive control and in negative control , one of the sections was treated with buffer instead of primary antibody. HBME 1 immunostaining was done using monoclonal mouse antibody – DAKO, clone HBME 1, isotype IgM kappa. Normal peritoneal tissue was taken as positive control and in negative control , one of the sections was treated with buffer instead of primary antibody. Semi-quantitative scoring was done based on the percentage of positively stained cells. The results were tabulated and statistically analysed.

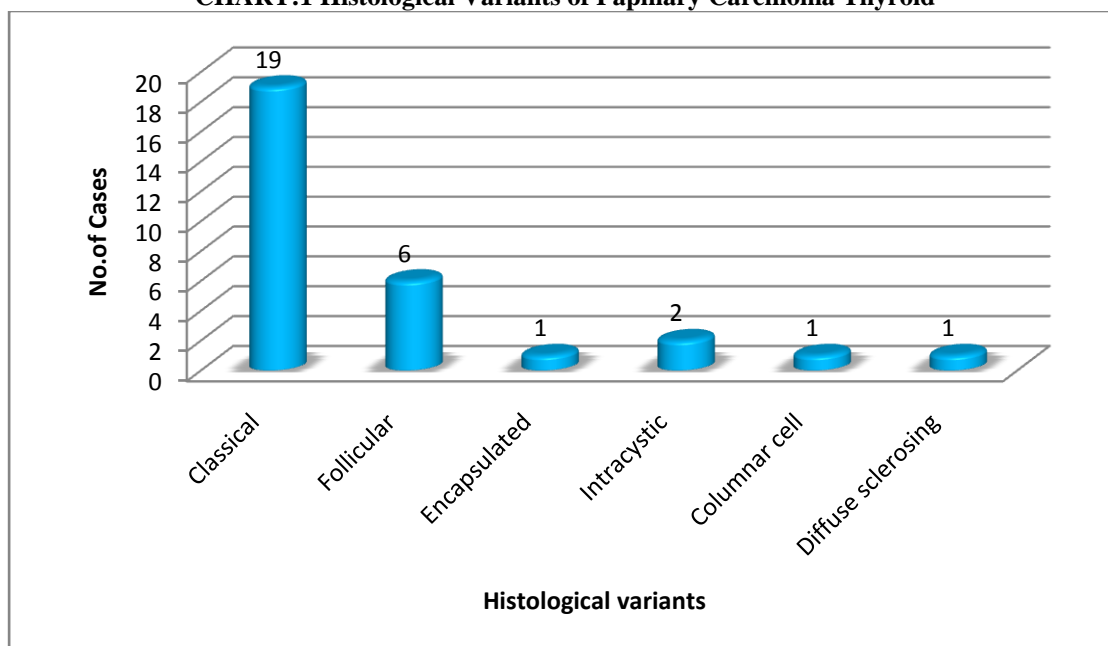
III. Results

Most common variant observed in this study was the classical variant (19 cases, 63.33%) and the next common variant was follicular variant (6 cases 20%) (Table 1 & Chart 1)

Table: 1 Histological Variants of Papillary Carcinoma Thyroid

Sl. No.	Histological	No.of Cases	Percentage (%)
1.	Classical	19	63.33
2.	Follicular	6	20
3.	Encapsulated	1	3.33
4.	Intracystic	2	6.66
5.	Columnar cell	1	3.33
6.	Diffuse sclerosing	1	3.33

CHART:1 Histological Variants of Papillary Carcinoma Thyroid



Associated Conditions

The surrounding neoplastic thyroid tissue showed features of benign lesions associated with the papillary carcinoma thyroid .In 8 cases (26.66%) papillary carcinoma thyroid was associated with colloid goiter, adenomatous hyperplasia was seen in 5 cases (16.66%), Hashimoto’s thyroiditis was seen in 4 cases (13.33%) and one case showed associated parathyroid adenoma.

Cytokeratin 19 Expression

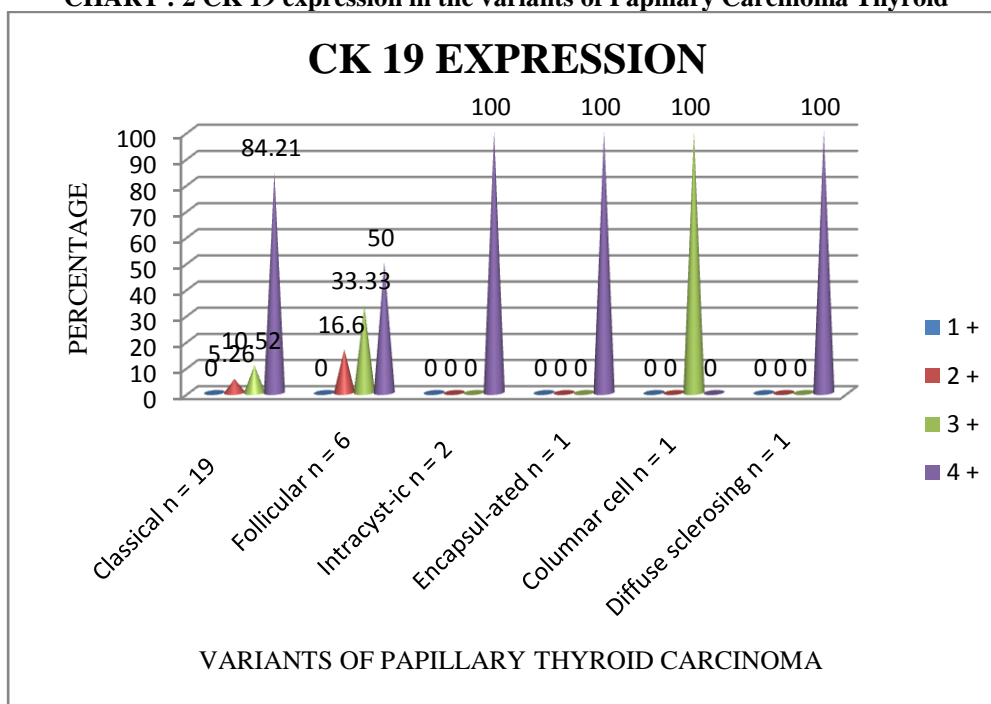
CK 19 expression was seen in all cases (30cases, 100%) of papillary carcinoma thyroid and a semi quantitative scoring of CK 19 expression based on the percentage of positively stained cells was done. The staining pattern was predominantly cytoplasmic. The results were as follows.

Table 2: CK 19 expression in the variants based on the semi quantitative scoring.

Score	Classical variant n = 19	Follicular variant n = 6	Intracystic variant n = 2	Encapsulated variant n = 1	Columnar cell variant n = 1	Diffuse sclerosing n = 1
0	0	0	0	0	0	0
1+	0	0	0	0	0	0
2+	1(5.26%)	1(16.6%)	0	0	0	0
3+	2 (10.52%)	2 (33.33%)	0	0	1(100%)	0
4+	16(84.21%)	3 (50%)	2(100%)	1(100%)	0	1(100%)

The classical variant showed 4+ positivity in 16 cases (84.21%), 3 + positivity in 2 cases (10.52%) and 2 + positivity in 1 case (5.26%). In the follicular variant 3 cases (50%) showed 4 + positivity, 2 cases (33.33%) showed 3 + positivity and only 1 case (16.6%) showed 2 + positivity. The columnar cell variant showed 3 + positivity. All other variants showed 4 + positivity. In non-neoplastic areas pseudopapillary foci were either negative or weakly positive. (Table 2 & Chart 2)

CHART : 2 CK 19 expression in the variants of Papillary Carcinoma Thyroid



HBME 1 expression

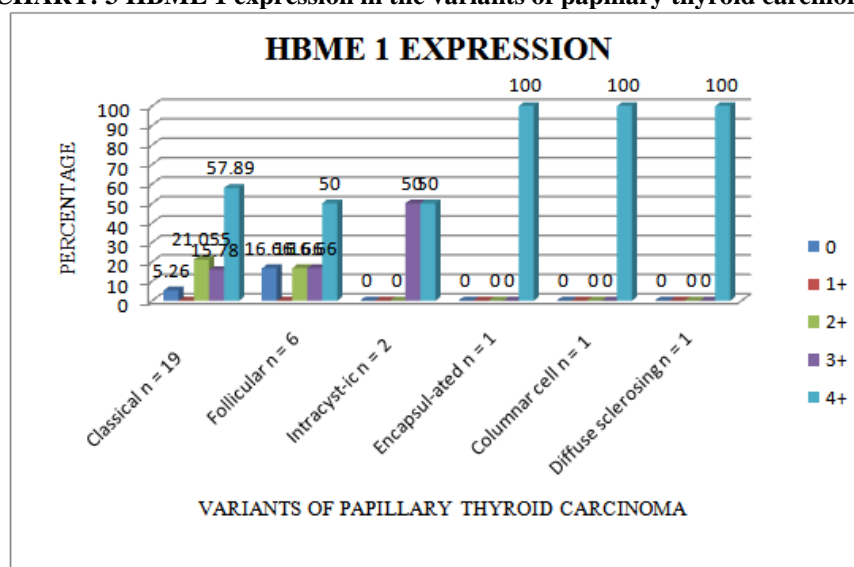
HBME-1 expression was analysed in all the cases. Membranous staining was considered positive. The results were analysed according to the semi-quantitative score.

Table 3: HBME 1 expression in papillary carcinoma thyroid:

Score	Classical variant	Follicular variant	Intracystic variant	Encapsulated variant	Columnar cell variant	Diffuse sclerosing variant
0	1(5.26%)	1(16.66%)	0	0	0	0
1+	0	0	0	0	0	0
2+	4(21.05%)	1(16.66%)	0	0	0	0
3+	3(15.78%)	1(16.66%)	1(50%)	0	0	0
4+	11(57.89%)	3(50%)	1(50%)	1(100%)	1(100%)	1(100%)

The classical variant showed 4+ positivity in 11 cases(57.89%), 3+ positivity in about 3 cases(15.78%) and 2+ positivity in 4 cases (21.05%). The stain was found negative in one case (5.26%). In the follicular variant, 1 case (16.66%) showed 2+ positivity, 1 case (16.66%) showed 3+ positivity and 3 cases (50%) showed 4+ positivity. One case of this variant showed negative staining. The intracystic variant showed 3+ positivity in 1 case and 2+ positivity in 1 case. All other variants showed 4+ positivity. (Table 3).Associated benign lesions did not show HBME-1 expression. (Table 3& Chart 3)

CHART: 3 HBME 1 expression in the variants of papillary thyroid carcinoma.



The chart 3 depicts the HBME 1 expression in the variants of papillary thyroid carcinoma. 4+ membranous positivity was seen in 57.89% cases of classical variant, 50% cases of follicular variant, 50% cases of intracystic variant and all cases of encapsulated, columnar cell and diffuse sclerosing variant. In non-neoplastic areas pseudopapillary foci were negative for immunostain .

IV. Discussion

Apart from the conventional types of papillary carcinoma thyroid , there are a number of variants with different histomorphological features. The prognosis also varies in the different variants. The most common variant in our current study was the classical variant (63.33%) followed by follicular variant (20%). In a study by Khan et al ⁴ in Saudi Arabia, the incidence of the classical variant was 57%, follicular variant 20%, columnar cell variant was 8%, diffuse sclerosing variant 3% .A study by Muzaffar et al⁵ showed an incidence of 70.7% in the classical variant, 15.9% in the follicular variant and columnar cell variant 7.3%. The commonest variant in all the above studies was the classical variant followed by the follicular variant similar to our study. The present study showed strong and diffuse positivity in all cases of papillary thyroid carcinoma.

MR Nasr et al ⁶ studied the expression of CK 19 expression in 51 cases of papillary thyroid carcinoma.He observed diffuse positivity in 100% cases of the classical variant and 90% cases of the follicular variant. The study concluded that strong and diffuse expression of CK19 raises the suspicion of papillary thyroid carcinoma and negative staining is a strong evidence against papillary thyroid carcinoma.

Bose et al ⁷ studied 22 cases of papillary thyroid carcinoma including classical variant, follicular variant and diffuse sclerosing variant. 4 + positivity was seen in 84.62% cases of classical variant and 62.50% of cases of follicular variant. Our study showed 4 + positivity in 84.21% of cases of classical variant ,which correlated with the above study.

Scognamiglio et al ⁸ on analyzing the expression of CK19 in 49 cases of papillary thyroid carcinoma, found that diffuse positivity was seen in 100% cases of classical variant and 90% cases of follicular variant. The study concluded that CK 19 was the most sensitive marker among the four markers (CK19, HBME1, Galectin 3 and CITED 1) studied.

In a study by Y.J. Park et al ⁹ , CK19 strong and diffuse positivity was seen in 96.7% cases of papillary thyroid carcinoma. A study by Haltas et al ¹⁰ showed diffuse 4+ positivity in about 75% of cases and 3.57% of cases were negative or weakly positive. Our present study showed higher percentage (100%) of positivity than the above two studies.

The expression of CK 19 in the associated benign lesions were also studied. MR Nasr et al ⁴ showed CK19 positivity in 68% of benign lesions including adenomatous nodule and Hashimoto’s thyroiditis, but the positivity was weak. In the study by Y.J. Park et al ⁹ , 9.3% cases of adenomatous nodule showed positivity. Haltas et al ¹⁰ showed focal staining of CK 19 in 29.41% cases. In all the studies the staining pattern was focal and weak. The present study showed focal and weak immunostaining in 31.8% cases.

The sensitivity and specificity of CK 19 was calculated based on the expression in papillary carcinoma and associated benign lesions. MR Nasr et al ⁴ showed a sensitivity of 100% and specificity of 32%. Even though non- neoplastic lesions show positive immunostaining for CK 19 , they can be differentiated from papillary thyroid carcinoma by the presence of strong and diffuse positivity in the latter.

HBME1 EXPRESSION:

In the present study, Hector Battifora mesothelial 1 (HBME1) expression was seen in 93.3% cases of papillary thyroid carcinoma. Among the variants, 94.7% cases of classical variant and 83.3% cases of follicular variant showed membranous positivity with variable cytoplasmic positivity.

MR Nasr et al ⁶ showed a positivity in 96% cases of papillary thyroid carcinoma. In a study by Scognamiglio et al ⁸, 88% cases of classical variant and 86% cases of follicular variant showed membranous positivity. The study concluded that the most specific marker among the four markers (CK19, HBME1, Galectin 3 and CITED 1) was HBME 1. The present study had a similar positivity rate compared to MR Nasr et al ⁶. The percentage of positivity in follicular variant was comparable with that of Scognamiglio et al ⁸.

In a study by Y.J. Park et al ⁹, HBME 1 positivity was seen in 91.7% cases of classical variant of papillary thyroid carcinoma, and 94.1% cases of follicular variant of papillary thyroid carcinoma. The present study showed a specificity of 100% .

CK19 expression confirms the presence of papillary differentiation and it is the most sensitive marker according to many studies. It is not specific as it is positive in certain benign lesions. The diffuse , strong staining pattern confirms the diagnosis of papillary thyroid carcinoma whereas benign lesions show focal and weak staining pattern. HBME1 is another immunomarker which selectively stains malignant lesions and it is negative in benign lesions. HBME 1 is the most specific marker for papillary thyroid carcinoma confirmed by many studies. CK 19 was found to be more sensitive and HBME1 was more specific in differentiating benign and malignant lesions.

V. Conclusion

The present study was conducted to assess the degree of expression of CK 19 and HBME1 immunomarkers in papillary thyroid carcinoma and to assess their efficacy as a reliable and cost-effective markers. Immunostaining with CK 19 showed diffuse cytoplasmic positivity in all the cases (100%), but the percentage of positively stained cells was varied. Columnar cell variant showed 3+ positivity and all other variants showed 4+ diffuse positivity. Few of the benign lesions (31.8%) which were found associated with papillary thyroid carcinoma also showed positivity, but it was focal and weak. Immunostaining with HBME1 showed diffuse membranous positivity with variable cytoplasmic staining. 93.3% cases had membranous staining pattern and the associated benign lesions were negative.

Papillary thyroid carcinoma has a number of variants with different morphological features and there is inter and intraobserver variation in the diagnosis of these variants. Immunohistochemistry is useful when there is a difficulty in the diagnosis of tumors with questionable nuclear features. No single marker is 100% sensitive or specific for papillary thyroid carcinoma. A simple reliable basic panel of markers is always very useful. Among the variants both the markers showed positive staining . Therefore, a combined immunostaining with CK19 and HBME1 increases the diagnostic accuracy in papillary thyroid carcinoma.

References

- [1]. Fischer S, Asa SL. Application of Immunohistochemistry to Thyroid Neoplasms. Arch Pathol Lab Med 2008;132: 359-72
- [2]. Cheung CC, Ezzat S, Freeman JL, Rosen IB, Asa SL. Immunohistochemical Diagnosis of Papillary Thyroid Carcinoma. Mod Pathol 2001;14:338-42
- [3]. Bose D , Das RN, Chatterjee U, Banerjee U. Cytokeratin 19 immunoreactivity in the diagnosis of papillary thyroid carcinoma. Indian J Med Paediatr Oncol 2012;33: 107-11
- [4]. Khan ar, Abu-eshy sa. Variants of papillary carcinoma of the thyroid: experience at Asir Central Hospital. J R Coll Surg Edinb 1998; 43:20-5 G Emons et al, Hormonal interactions in endometrial Cancer, Endocrine Related cancer (2000); 7: 227-242.
- [5]. Muzaffar M,Nigar E,Mushtaq S, Mamoon N. The Morphological Variants of Papillary Carcinoma of the Thyroid: A Clinico-Pathological Study. JPMA 1998; 48:133-7
- [6]. Nasr MR, Mukhopadhyay S, Zhang S,Katzenstein AA. Immunohistochemical markers in diagnosis of papillary thyroid carcinoma: utility of HBME1 combined with CK19 immunostaining.Mod Pathol 2006;19:1631-7
- [7]. Bose D , Das RN, Chatterjee U, Banerjee U. Cytokeratin 19 immunoreactivity in the diagnosis of papillary thyroid carcinoma. Indian J Med Paediatr Oncol 2012;33: 107-11
- [8]. Scognamiglio T,Hyjek E,Kao J,Chen Y. Diagnostic Usefulness of HBME1, Galectin-3, CK19,and CITED1 and Evaluation of Their Expression in Encapsulated Lesions With Questionable Features of Papillary Thyroid Carcinoma. Am J Clin Pathol 2006;126:700-8
- [9]. Park YJ, Kwak SH, Kim DC, Kim H, Choe G,Park DJ,Jang H,Park SH,Cho BY, Park SY.Diagnostic Value of Galectin-3, HBME-1, Cytokeratin 19, High Molecular Weight Cytokeratin, Cyclin D1 and p27kip1 in the Differential Diagnosis of Thyroid Nodules.J Korean Med Sci 2007; 22: 621-8
- [10]. Haltas H, Bayrak R, Yenidunya S, Yildirim U.Diagnostic value of cytokeratin 19, HBME-1, and galectin-3 immunostaining of cell block from fine-needle aspiration specimens in papillary carcinoma of the thyroid.Turk J Med Sci 2013; 43: 625-30.

Dr.Johnsy Merla. "Papillary Carcinoma Thyroid Variants and Immunomarker Expression - An Additional Diagnostic tool." IOSR Journal of Dental and Medical Sciences (IOSR-JDMS), vol. 18, no. 2, 2019, pp 39-43.