

Orbito-Ocular Tumours at The Benue State University Teaching Hospital, Makurdi, Nigeria.

Chaha K¹, Ojabo C, Ben-Ameh T, Ogaga U

1. Department of Ophthalmology, Benue State University Teaching Hospital, Makurdi

Corresponding Author: Chaha K

Abstract

Introduction: Orbito-ocular tumours are an important cause of morbidity and mortality. Though studies on orbito-ocular tumours have been carried out in various parts of Nigeria, no formal study has been carried out in Benue state.

Aim: The aim of this study is to highlight the different orbito-ocular tumors and consider other demographics of such as seen in the Benue State University Teaching Hospital, Makurdi.

Methodology: This is a retrospective hospital based study in which all case folders of patients with orbito-ocular tumours in Benue State University Teaching Hospital between 2014 and 2016 were retrieved and analyzed.

Results: Of the 15 cases (16 eyes) analyzed, 8 were female, with a male to female ratio of 1:1.1. 7 cases (46.7%) fell in the age group between 0 and 16 years. 7 cases (46.7%) also fell in the age group between 17 and 45 years. Retinoblastoma was the most common tumour (25%), followed by conjunctival squamous cell carcinoma (18.75%), then orbital rhabdomyosarcoma (12.5%).

Conclusion: Both sexes and all age groups are affected by orbito-ocular tumours. Retinoblastoma was the most common orbito-ocular tumour, followed by conjunctival squamous cell carcinoma.

Key Words: Benue, Orbito-ocular, Tumours.

Date of Submission: 26-01-2019

Date of acceptance: 09-02-2019

I. Introduction

Orbito-ocular tumours are tumours arising from the orbit and its content, and are important causes of morbidity and mortality¹. The orbit is an anatomically complex structure containing the globe, extraocular muscles, fat, vessels, nerves, glandular and connective tissues. The orbito-ocular tumours will therefore include tumours of all the tissues contained in the orbit, together with the ocular adnexal tissues like the lacrimal drainage system and the lids.

These tumours can arise from the eyeball (ocular tumours) or from other structures found in the orbit (orbital tumours). They can be primary or secondary (metastatic). Invasion of the orbital space by malignant tumours from contiguous areas such as the paranasal sinuses, nasal cavity, skin of the eyelids and, parotid glands can also occur.

The most common benign orbital tumour of adults is the cavernous haemangioma, in contrast to the capillary haemangioma for children. Rhabdomyosarcoma is said to be the most common orbital malignant tumour in children, with lymphoma being the most common in adults².

The most common intraocular malignancy globally, in adults is the choroidal melanoma, while that in children is retinoblastoma^{2, 3}.

Orbito-ocular pathologies can cause cosmetic blemish, lead to compromise of vision and even cause death if not treated (see figures 4&5). Though studies on orbito-ocular tumours have been carried out in various parts of Nigeria, no formal study has been carried out in Benue state. This is a study on the pattern of orbito-ocular tumours seen in the Benue State University Teaching Hospital.

AIM

The aim of this study is to highlight the different orbito-ocular tumors and consider other demographics of such as seen in the Benue State University Teaching Hospital, Makurdi.

II. Methodology

All case folders of patients that had surgery for an orbital-ocular tumour in Benue State University Teaching Hospital between 2014 and 2016 were retrieved and analyzed. 20 folders were retrieved. Out of these, 5 cases did not have specific histological diagnosis and were excluded from the study.

The remaining 15 cases (16 eyes- 1 bilateral) with histological diagnosis were analysed. The ethical committee of the hospital gave approval for the study.

III. Results

Out of the 15 cases analyzed 7 cases (46.7%) fell in the age group between 0 and 16 years and 7 cases (46.7%) also fell in the age group between 17 and 45 years and only 1 (6.7%) fell in the age group 46 years and above (fig. 1). The age range was 1-46 years, with a mean age of 21.5 yrs.

There were 7 male cases (46.7%) and 8 female cases (53.3%), with a male to female ratio of 1:1.1 (fig.2) One of the 15 cases analyzed had bilateral retinoblastoma, resulting in 1 eyes analyzed.

There were 4 eyes with retinoblastoma (25% of eyes), 3 eyes with squamous cell carcinoma (18.8% of eyes), and 2 cases of orbital rhabdomyosarcoma (12.5%). The rest of the tumours were 1 each (6.25%), and included squamous papilloma, cystic teratoma, conjunctival hemangioma, plexiform neuroma, severe dysplasia and carcinoma in situ. Retinoblastoma, rhabdomyosarcoma and cystic teratoma were found only in children.

Ocular surface squamous neoplasia was found in 5 eyes of 5 patients (31%). Of these, 4(80%) were HIV positive. All of whom were adults. It was most common in the age group 17-45 years

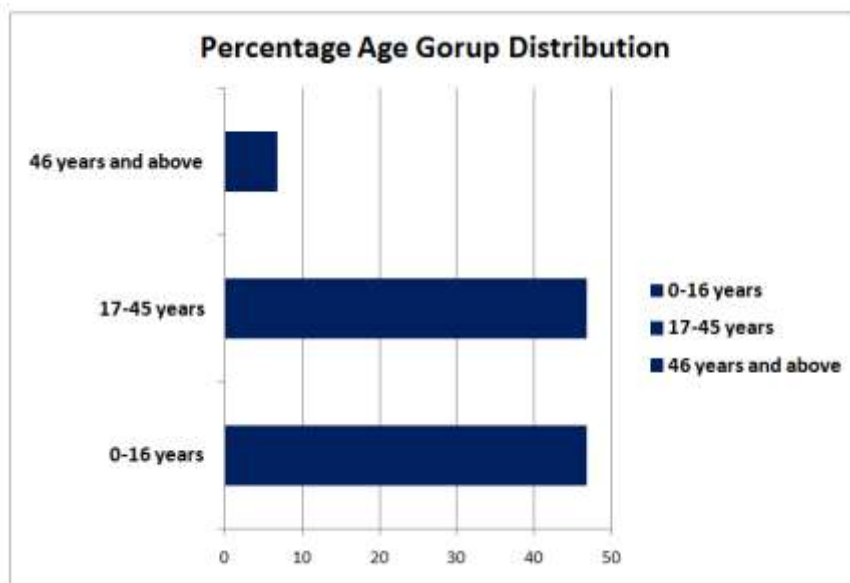


Fig.1

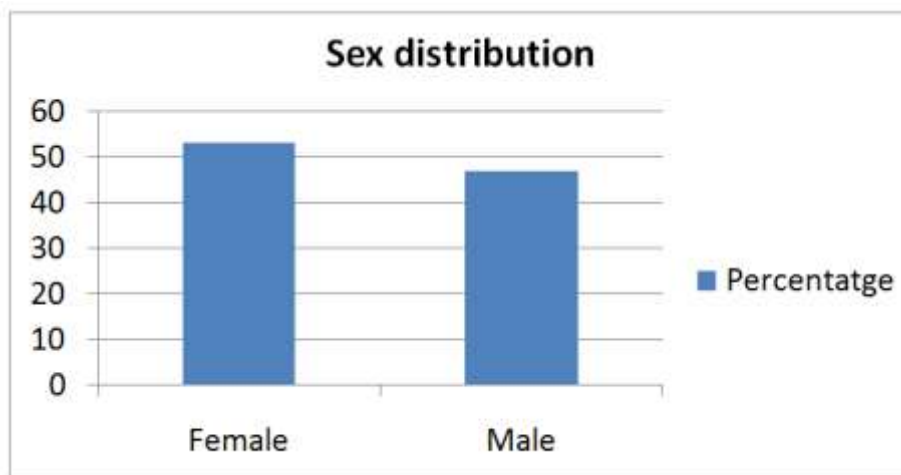


Fig. 2

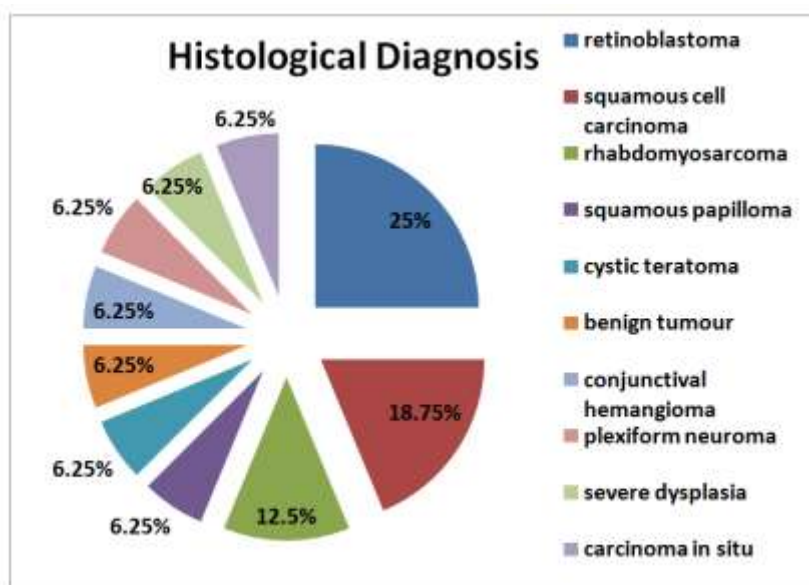


Fig.3

AGE VA	0-16yrs	17-45yrs	46 yrs & above	Total (%)
<6/60	6	2	0	8(50%)
6/24-6/60				
Better than 6/24	2	5	1	8(50%)
TOTAL(%)	8(50%)	7(43.75%)	1(6.25%)	16(100%)

Table 1- Presenting Visual acuity

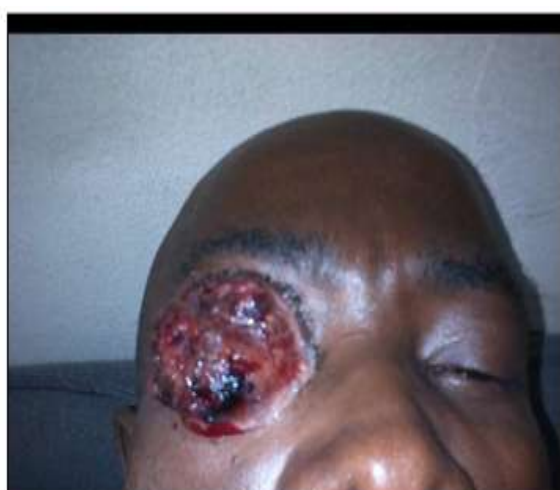

Fig 4: ORBITAL SQUAMOUS CELL CARCINOMA

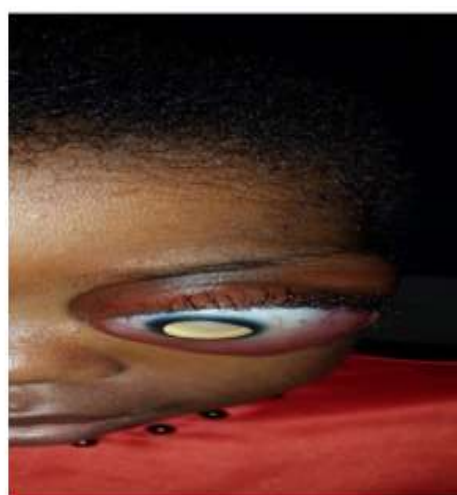

Fig 5: RETINOBLASTOMA

IV. Discussion

Orbital-ocular tumours are tumours of the bony orbital contents, adnexae and structures of the eyeball. Orbital tumours may be benign or malignant.

In general, neoplasms of the orbit may be classified as primary or secondary (infiltration from an adjacent structure, or metastatic from distant structures).

Orbital-ocular tumours have been found to affect all age groups and both sexes. In our study both sexes were almost equally affected, with the males being less affected than the females (46.7% and 53.3%). This in agreement with a study carried out in Enugu by C M Chuka-Okosa et al¹ but in variance to many other studies

in Nigeria where Males were found to be more affected than females^{4,6,7,8,10}. Both children and adults were affected also.

Retinoblastoma occurred only in children (ages 2-5), and was the most common orbito-ocular tumour in our study. This agrees with many other studies where retinoblastoma is said to be the most common orbito-ocular tumour, especially in children^{1,4,5,6,7,8,9,10,11}.

The second leading cause of orbito-ocular tumour in our study was conjunctival squamous cell carcinoma (18.75%). This is in keeping with other studies carried out in Nigeria^{1,4,10,11}, but at variance with a study carried out in Benin by B A Akpe et al⁸, where conjunctival squamous cell carcinoma was the most common.

Ocular surface squamous neoplasia (OSSN), includes varying grades of dysplasia- encompassing conjunctival intraepithelial neoplastic lesions (CIN) and invasive squamous cell carcinoma (SCC) of conjunctiva. This was found in 31% of cases. It was most common in the age group 17-45years.

An increase in the incidence of OSSN, since the HIV pandemic, has suggested that HIV infection increases the risk for OSSN. In Africa, OSSN has been recognized to be strongly associated with HIV¹².

HIV infection is now established as a risk factor for the development of squamous cell neoplasia of the conjunctiva based on studies from Rwanda, Malawi, and Uganda^{13,14}. In our study, 4 of the 5 eyes (80%) with OSSN, were HIV positive.

Rhabdomyosarcoma is said to be the most common 'orbital' malignant tumour in children². Rhabdomyosarcoma was found to be the third (3rd) leading cause of orbito-ocular tumours (18.75%) in our study.

No choroidal melanomas were found in our study. This is not in keeping with studies in other parts of the world^{2,3}. It however reflects what was found in various studies in Nigeria^{5,8,11}.

In our study 8 eyes out of the 16 eyes (50%) had very poor visual acuities ranging from Counting fingers (CF) to No Perception of Light (NPL). This may be due to late presentation to hospital by many of the patients, especially children.

V. Conclusion

Orbito-ocular tumours affect all age groups and can have grave consequences on vision and life of the patient if not managed promptly.

In our study, Retinoblastoma was found to be the most common orbito-ocular tumour. It was found most commonly in children who presented late to hospital.

More effort should be made to educate the public on the early signs of orbito-ocular tumours, and the need to seek appropriate care on time.

References

- [1]. C M Chuka-Okosa, N J Uche, N N Kizor-Akaraiwe: Orbito-ocular neoplasms in Enugu, South-Eastern Nigeria; *West African Journal of Medicine* 2008, 27 (3): 144-7
- [2]. Holland-Frei Cancer Medicine, 6th Edition
- [3]. B V Castillo Jnr, L Kauffman: paediatric Tumours of North America 2003 Feb; 50(1):149-72
- [4]. D Chinda, M O Samaila, E R Abah, F Garba, A L Rafindadi, A Adamu: A clinico-pathological study of orbito-ocular tumours at Ahmadu Bello University Teaching Hospital Shika-Zaria, Nigeria: a 5-year review; *Clin Cancer Invest J* 2012;1:145-7
- [5]. Olurin MB, A O Williams: Orbito-ocular tumors in Nigeria; *cancer Volume30, Issue2 August 1972 Pages 580-587*
- [6]. I M Ifeanyinwa, T M Owoloye, O O Olaofe, K N Ezike: Morphological Spectrum of Orbito-ocular Disease in a Tertiary Health Centre in Keffi, North-Central Nigeria; *Advances in Medicine Volume2015, article ID619414*
- [7]. Fasina, O I Fawole, O A Ayeni: Orbito-Ocular Tumours in Ibadan, South-West Nigeria; *West African Journal of Medicine* 2014 Jul-Sep;33(3):211-5
- [8]. B A Akpe, A E Omoti, E T Iyasele: Histopathology of Ocular Tumour Specimens in Benin City, Nigeria; *Journal of Ophthalmic and Vision Research* 2009, vol.4, no.4, pp232-237, 2009
- [9]. A B Umar, O Ochicha, Y Iliyasu: A pathologic Review of Ophthalmic Tumours in Kano, Northern Nigeria; *Nigerian Journal of Basic and Clinical Sciences* 2012, 9: 23-6
- [10]. C C Anunobi, Akinsola F B, Abdulkarim F B, Aribaba O T, Nnoli M A, Banjo A A: Orbito-ocular lesions in Lagos; *Niger Postgrad Medical J* 2008;15:146-151
- [11]. C O Bekibebe, A O Oluwasola: A clinicopathological study of orbito-ocular diseases in Ibadan between 1991-1999; *Afri J Med Med Sci.* 2003 Jun;32(2):197-202
- [12]. R Mittal S Rath G K Vemuganti: Ocular surface squamous neoplasia – Review of etio-pathogenesis and an update on clinicopathological diagnosis; *Saudi J Ophthalmol.* 2013 Jul; 27(3): 177–186.
- [13]. Thomas J.O. Acquired immunodeficiency syndrome-associated cancers in Sub-Saharan Africa. *Semin Oncol.* 2001;28:198–206.
- [14]. Spitzer M.S., Batumba N.H., Chirambo T. Ocular surface squamous neoplasia as the first apparent manifestation of HIV infection in Malawi. *Clin Experiment Ophthalmol.* 2008;36:422–425.

Chaha K. "Orbito-Ocular Tumours at The Benue State University Teaching Hospital, Makurdi, Nigeria."
IOSR Journal of Dental and Medical Sciences (IOSR-JDMS), vol. 18, no.2, 2019, pp 52-55