

Primary Ewing's Sarcoma of Kidney- a Rare Case Report

Dr. E.Rajesh Goud¹, Dr. Jakkula Srikanth², Dr. Ramakrishna.Ch,³ Dr.Naga Sarika Vennavalli⁴, Dr. Sri Harsha Muvva,⁵Dr. Kanmathareddy Amulya⁶

¹(Senior Consultant Surgical Oncologist –Department Of Surgical Oncology, Century Superspeciality Hospital, Hyderabad, India)

²(Post-Graduate General Surgery, Svs Medical College, Knr University Of Health Sciences, India)

³(Consultant Surgical Oncologist –Department Of Surgical Oncology, Century Superspeciality Hospital, Hyderabad, India)

⁴(Consultant Pathologist –Department Of Pathology, Century Superspeciality Hospital, Hyderabad, India)

^{5,6}(Post-Graduate General Surgery, Svs Medical College, Knr University Of Health Sciences, India)

Corresponding Author: Dr. E.Rajesh Goud

Abstract: First case of Ewing's sarcoma of kidney was reported in the year 1975. They are rarely found high-grade malignant potentials, with poor prognosis. Ewing sarcoma/PNET of the kidney is sparse, with less than 100 cases reported in the literature. We are hereby presenting a case of 19 years old female with complaints of vague abdominal pain.CECT abdomen and pelvis revealed a 16x16x15cms heterogenous hypoechoic mass arising from upper pole of left kidney.Radical nephrectomy was done. Immuno-histochemistry shows positivity for CD99, FLI-1 and negative for WT-1.Morphology in correlation with IHC is consistent with Ewing's sarcoma family of tumours.6 cycles of chemotherapy with VAC regimen was planned and patient was kept on regular follow-up.

Key Words: CD99, Ewings sarcoma family of tumors, Immuno-histochemistry, Radical nephrectomy, VAC regimen.

Date of Submission: 28-02-2019

Date of acceptance: 18-03-2019

I. Introduction

Ewing sarcomas/primitive neuro-ectodermal tumors (EWS/PNET) of the kidney is a member of small round cell "blue tumour"family which are rarely found high-grade malignant tumors, offering poor prognosis. First case of EWS of kidney was reported in the year 1975.⁽¹⁾ EWS arises from neural and neural crest cells that invaginate into kidney during development.⁽²⁾ It is a genetic disease with sporadic pattern due to a translocation type of mutation causing fusion between the EWS gene on chromosome 22 and FLI1 on chromosome 11.Most common site is bone. Less commonly it can affect the skin, soft tissue, or viscera.^(3,4) Total surgical resection is considered as the treatment of choice for these tumors. Herein, we report a case of 19-year-old female diagnosed with EWS with the help of Histopathology, Immunohistochemistry and cytogenetic analysis.

II. Case Report

A 19 years old female presented to hospital with complaints of pain abdomen since 20days, vague pain more localized towards left lumbar region. No other specific symptoms and on palpation single 12X10 cm with firm in consistency, ballotability present however borders are not separately demarcated. USG Abdomen revealed single 16X13cm heterogenous mass noted in retroperitonium. CECT Abdomen and Pelvis revealed a single large 16x16x15 cms well defined hypo dense mass lesion which is predominantly cystic with multiple solid components occupying left hypochondrium and left lumbar region, which on post contrast imaging is showing mild peripheral rim enhancement and mild enhancement of soft tissue components with large central non-enhancing necrotic component. Lesion was causing mass effect on pancreas, spleen, bowel loops and upper pole of kidney displacing it infero-laterally.Left adrenal gland wasn't visualized separately. All the above features were suggestive of left renal mass /left adrenal mass/retroperitoneal mass.

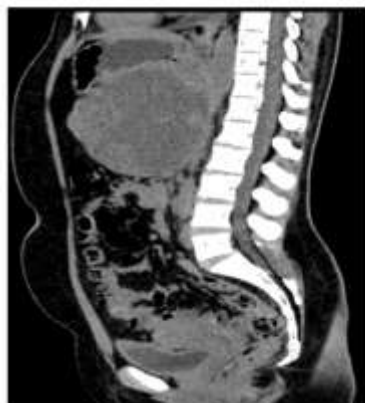

Figure 1:CECT Sagittal section showing mass lesion in the upper pole of kidney

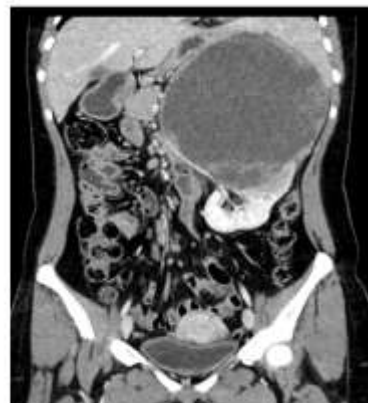

Figure 2:CECT Coronal section showing mass lesion in the upper pole of kidney

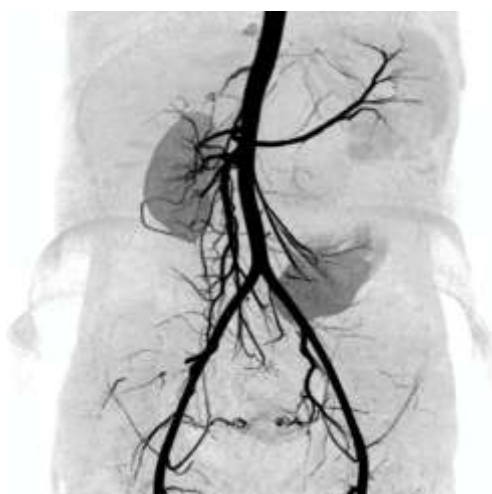

Figure 3: Arterial MIP reconstruction image showing left renal artery displaced inferiorly and mass is supplied by branches from splenic artery.

All haematological investigations were within normal limits including 24 hours urinary vinyl mandelic acid and serum cortisol. USG guided FNAC was done from both solid and cystic components of the lesion which revealed scanty cellular smear showed cyst macrophages against proteinaceous background. There were no inflammatory cells or atypical cells which was suggestive of cystic lesion. Radical nephrectomy done and specimen was sent for histopathological examination. Post-op period was uneventful. Histopathological examination, revealed tumour in sheets intervening fibromyxoid stroma, vague rosettoid pattern with extensive areas of necrosis. Ewing's/PNET arising from the kidney. Tumour cells were mildly pleomorphic with round to oval, mitotic figures were about 3-4/HPF. Immunohistochemistry shows positivity for CD99, FLI-1 and negative for WT-1. Morphology in correlation with IHC is consistent with Ewing's sarcoma family of tumours (pT3aNxMx). Chemotherapy of 6 cycles was planned with VAC regimen (vincristine, dactinomycin, cyclophosphamide) and patient was kept on regular follow up.

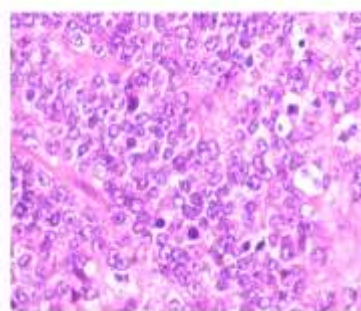
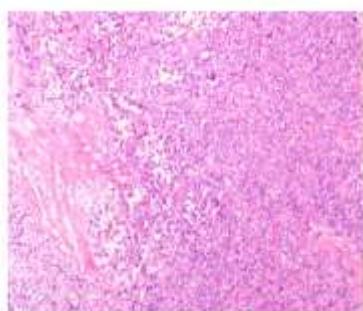


Figure 4 & 5: Microscopic images under 10x and 40x resolution showing vague rosettoid pattern with mild pleomorphic round to oval cells

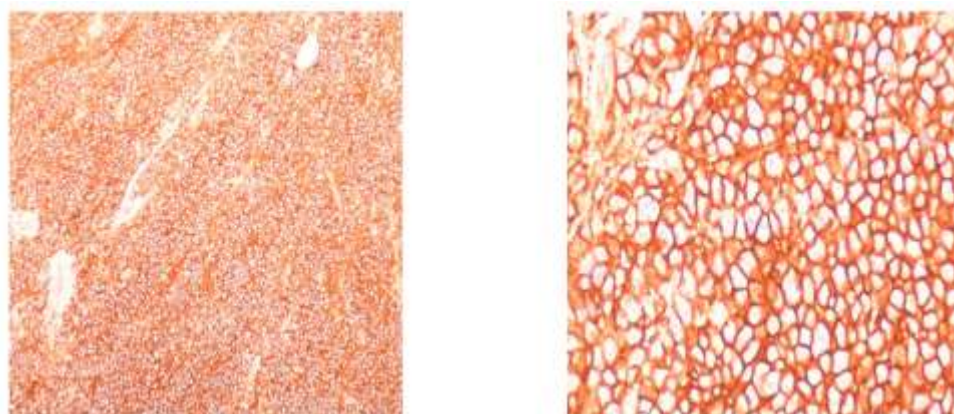


Figure 6 & 7: Immuno-Histochemistry images showing CD99 positivity

III. Discussion

Renal cell carcinoma (RCC) is the most frequent malignant neoplasm of the kidney that constitutes to more than 90% of kidney tumors.^(3,5) Ewing sarcoma/PNET of the kidney is sparse, with less than 100 cases reported globally. Among these, leiomyosarcoma is the most common (40–60%) followed by liposarcoma (10–15%).^(5,6) EWS/PNET is a rare but relatively aggressive renal neoplasm that typically manifests in old children and young adults (mean age of presentation is 28 to 34 years), with a slight male predominance.⁽⁷⁾ Sarcomas of the kidney are usually asymptomatic until they are large enough to produce symptoms which are uncharacteristic such as pain (85%), palpable masses (60%), and hematuria (37%).^(7,8)

Due to its dismal prognosis and aggressive behavior, establishing ESFT/PNET'S diagnosis is pivotal for the treatment and follow-up. No radiological investigation confirms the diagnosis of PNET. It is based on the pathologic findings, assisted by immunocytochemistry and/or molecular analysis. The imaging characteristics of most renal sarcomas are identical to those of RCC.⁽⁹⁾ These tumors appeared as ill-defined, large heterogeneous masses with necrotic and hemorrhagic areas on CT and MRI.⁽⁵⁾ Ellinger et al, Rizzo et al reported venous extension into the renal vein, inferior vena cava, and right heart.^(6,10) Renal PNET often metastasizes to the lung, liver, and bone. MRI and CT provide an accurate assessment of local resectability and the detection of distant metastases. Furthermore, the use of 99-technetium scintigraphy is a sensitive method for the detection of bone metastases.^(5,6)

The differential diagnoses for EWS of kidney includes Wilms tumor, neuroblastoma, blastema rich nephroblastoma, monophasic synovial sarcoma, rhabdomyosarcoma, desmoplastic small round cell tumour, renal cell carcinoma, malignant lymphoma, metastatic renal involvement from sarcoma elsewhere in the body.⁽⁵⁾ Microscopic features associated with ESFT/PNET are considered non-specific as they can be seen in many other tumors. Under microscopy EWS forms spherical grouping of dark tumor cells around a central area that contains neurofibrils called Homer–Wright rosettes.⁽¹¹⁾ On Immunohistochemistry, EWS shows strong positivity for CD99, moderate positivity for FLI -1 and NSE. However CK, EMA, WT-1, LCA, TdT, synaptophysin, desmin and vimentin were negative.^(12,13) Approximately, 85–90% of EWS can be defined by a DNA translocation $t(11;22)(q24;q12)$, which creates a functional oncogene.^(14,15)

Fine needle aspiration plays a vital role in diagnosis. Image-guided renal biopsy is important in determining the preoperative diagnosis as it alters the treatment plan in case of metastatic disease.⁽¹⁶⁾ Guidelines for effective treatment of EWS/PNET seem scarce, presumably due to the rarity of the disease. Radical nephrectomy is the first line of management.⁽¹⁷⁾

EWS/PNET'S are aggressive tumors and may involve the lymph nodes and metastasize to lung, bone, and liver,⁽¹⁸⁾ which shows the need for multi-modality treatment. Surgical resection and adjuvant chemotherapy with or without neoadjuvant chemotherapy and radiotherapy have been implicated in the management of EWS/PNET. These tumors are relatively sensitive to chemotherapy. Initially, vincristine, actinomycin and cyclophosphamide were used, later doxorubicin, ifosfamide and etoposide were added to treat EWS.⁽¹⁹⁾ Radiotherapy (50-60-Gy) was useful in the presence of residual disease after surgical dissection, positive surgical margins, and loco-regional lymphadenopathy.⁽²⁰⁾ Patients with localized tumor have a 5-year disease free survival rate of approximately 45–55% prognosis of patients with metastatic disease is poor, with overall cure rate of 20%.⁽²¹⁾

IV. Conclusion

Ewing sarcoma/PNET of the kidney is sparse, with less than 100 cases reported globally. Due to its dismal prognosis and aggressive behavior, establishing ESFT/PNET'S diagnosis is pivotal for the treatment and follow-up. No radiological investigation confirms the diagnosis of PNET .It is based on the pathologic findings, assisted by immunocytochemistry and/or molecular analysis.Surgical resection and adjuvant chemotherapy with or without neoadjuvant chemotherapy and radiotherapy have been implicated in the management of EWS/PNET

References

- [1]. T. Seemayer, W. Thelmo, R. Bolande, Peripheral neuroectodermal tumors, *Perspect. Pediatr. Pathol.* 2 (1975) 151–172.
- [2]. Parham, D., Roloson, G., Feely, M., Green, D., Bridge, J. and Beckworth, J. (2001) Primary malignant neuroepithelial tumors of the kidney:a clinicopathologic analysis of 146 adult and pediatric cases from the National Wilms' Tumor Study Group Pathology Center. *Am J Surg Pathol* 25: 133–146.
- [3]. T. B. Wedde, I. V. K. Lobmaier, B. Brennhovd, F. Lohne, and K.Hall, "Primary ewings sarcoma of the kidney in a 73-year-old man," *Sarcoma*, vol. 2011, Article ID 978319, 4 pages, 2011.
- [4]. A. F. Fergany, N. Dhar, G. T. Budd, M. Skacel, and J. Garcia, "Primary extraosseous ewing sarcoma of the kidney with level inferior vena cava thrombus," *Clinical Genitourinary Cancer*, vol. 7, no. 3, pp. E95–E97, 2009.
- [5]. N. Lalwani, S. R. Prasad, R. Vikram, V. Katabathina, A. Shanbhogue, and C. Restrepo, "Pediatric and adult primary sarcomas of the kidney: a cross-sectional imaging review," *Acta Radiologica*, vol. 52, no. 4, pp. 448–457, 2011.
- [6]. J. Ellinger, P. J. Bastian, S. Hauser, K. Biermann, and S. C. Muller," "Primitive neuroectodermal tumor: rare, highly aggressive differential diagnosis in urologic malignancies," *Urology*, vol. 68, no. 2, pp. 257–262, 2006.
- [7]. J. R. Angel, A. Alfred, A. Sakhuja et al., "Ewing's sarcoma of the kidney," *International Journal of Clinical Oncology*, vol. 15, pp. 314–318, 2010.
- [8]. R. Venkitaraman, R. Mukkunda, K. T hway et al., "Primary adult renal Ewing's Sarcoma: a rare entity," *Sarcoma*, vol. 2009, Article ID 504654, 5 pages, 2009.
- [9]. T. Ekram, K. M. Elsayes, R. H. Cohan, and I. R. Francis, "Computed tomography and magnetic resonance features of renal ewing sarcoma," *Acta Radiologica*, vol. 49, no. 9, pp. 1085– 1090, 2008.
- [10]. D. Rizzo, G. Barone, A. Ruggiero et al., "Massive venous thrombosis of inferior vena cava as primary manifestation of renal Ewing's sarcoma," *Clinical Nephrology*, vol. 75, no. 6, pp. 560–564, 2011
- [11]. Bing, Z., Zhang, P., Tomaszewski, J. and MacLennan, G. (2009) Primary Ewing sarcoma/ primitive neuroectodermal tumor of the kidney. *J Urol* 181: 1341–1342.
- [12]. Thyavihally YB, Tongaonkar HB, Gupta S, Kurkure PA, Amare P, Muckaden MA, et al. Primitive neuroectodermal tumor of the kidney: a single institute series of 16 patients. *Urology*. 2008;71(2):292–6.
- [13]. R. E. Jimenez, A. L. Folpe, R. L. Lapham et al., "Primary Ewing's sarcoma/ primitive neuro ectodermal tumor of the kidney: a clinicopathologic and immunohistochemical analysis of 11 cases," *American Journal of Surgical Pathology*, vol. 26, no. 3, pp. 320–328, 2002.
- [14]. Ohgaki, K., Horiuchi, K., Mizutani, S., Sato, M. and Kondo, Y. (2010) Primary Ewing's sarcoma/ primitive neuroectodermal tumor of the kidney that responded to low-dose chemotherapy with ifosfamide, etoposide, and doxorubicin. *Int J Clin Oncol* 15: 210-214.
- [15]. Saxena, R., Sait, S. and Mhaweck-Fauceglia, P. (2006) Ewing sarcoma/primitive neuroectodermal tumor of the kidney: a case report. Diagnosed by immunohistochemistry and molecular analysis. *Ann Diagnostic Pathol* 10: 363–366.
- [16]. T. Ekram, K. M. Elsayes, R. H. Cohan, and I. R. Francis, "Computed tomography and magnetic resonance features of renal ewing sarcoma," *Acta Radiologica*, vol. 49, no. 9, pp. 1085– 1090, 2008.
- [17]. Zollner S, Dirksen U, Jurgens H, Ranft A. Renal wing tumors. *Ann Oncol*. 2013;24:2455–61.
- [18]. Rodriguez-galindo C, Marina NM, Fletcher BD, Parham DM, Bodner SM, Meyer WH. Is primitive neuroectodermal tumor of the kidney a distinct entity? *Cancer*. 1997;79:2243–50.
- [19]. Grier HE, Krailo MD, Tarbell NJ, MichaelLink MP, Fryer CJH, Pritchard DJ, et al. Addition of Ifosfamide and Etoposide to standard chemotherapy for Ewing's sarcoma and primitive neuroectodermal tumor of bone. *N Engl J Med*. 2003;348(8):694–701
- [20]. Miser J, Kinsella T, Triche T, Steis R, Tsokos M, Wesley R, et al. Treatment of peripheral neuroepithelioma in children and young adults. *J Clin Oncol*. 1987;5(11):1752–8.
- [21]. T. B. Wedde, I. V. K. Lobmaier, B. Brennhovd, F. Lohne, and K.S.Hall, "Primary ewings sarcoma of the kidney in a 73-year-old man," *Sarcoma*, vol. 2011, Article ID 978319, 4 pages, 2011.

Dr. E.Rajesh Goud. "Primary Ewing's Sarcoma of Kidney- A Rare Case Report." *OSR Journal of Dental and Medical Sciences (IOSR-JDMS)*, vol. 18, no. 3, 2019, pp 24-27.