

“Two Miniplate Technique for Treatment of Mandibular Angle Fracture- Original Study”

**Dr.R.Appadurai MDS^a, Dr.Maruthavanan Rajmohan MDS^b,
Dr.C.KumaraveluMDS^c, Dr.D.Lingeshwar MDS^d
Dr.R.ManjulaBDS^e, Dr.S.Christina Dhivya Rani BDS^f**

^aAssociate Professor, Department of Oral &Maxillofacial Surgery, Tamil Nadu Government Dental College & Hospital - Chennai, India.

^bAssociate Professor, Government Thanjavur Medical College and Hospital - Chennai, India.

^cRetired Principal, Tamil Nadu Government DentalHospital- Chennai, India.

^d Assistant Professor, Department of Prosthodontics, Tamil Nadu Government Dental College & Hospital - Chennai, India.

^e Intern, Government Royapettah Hospital-Chennai, India.

^f Intern, Government Royapettah Hospital- Chennai, India

Corresponding Author: Dr.R.Appadurai MDS

Date of Submission: 05-03-2019

Date of acceptance: 22-03-2019

I. Introduction:

Fractures of the mandibular angle represent the largest percentage of mandibular fractures. Therapeutic goal of any fracture management is to restore form and function at the earliest without any morbidity. Fractures of the mandibular angle represent an important clinical challenge because their treatment is plagued with the highest post surgical complication rate of all mandibular fractures. Traditional modalities include;maxillomandibular fixation alone in favorable fracture cases and open reduction and internal fixation in unfavorable fracture cases. A number of fixation methods have been advocated for treatment of mandibular angle fractures.¹

A study was done to evaluate the usefulness of two miniplate technique on patients who reported to, The Department of Oral and Maxillofacial surgery, Tamil Nadu Government Dental College and hospital, Chennai with mandibular angle fractures.

Patients and methods:

All cases selected for this study were evaluated for the efficacy of “two miniplate technique” in treating mandibular angle fractures using the following parameters: ease of the technique, occlusal stability, interincisal opening width, signs of infection, trigeminal dysfunction, and functional stability. Five cases of fracture, mandibular angle were taken up for the study. A complete and detailed history weretaken from each patient in a standardized method. Number and location of fracture, presence of pre-operative infection were also recorded. Routine blood investigations were made. All cases were treated under local anesthesia. They were post operatively observed and followed up for 1 year by clinical examination and radiograph.

Cases Description:

Case 1:

A male patient of 29 years reported with pain and swelling over the left side of the face with difficulty in mouth opening. The patient had history of road traffic accident 4 days back. Provisionally case was diagnosed as left side mandibular angle fracture.[FIG 1](#)

Case 2:

A male patient of 40 years reported with pain in lower jaw since two days. The patient had a history of road traffic accident. Provisionally case was diagnosed as left side mandibular angle fracture.[FIG 2](#)

Case 3:

A 33 year old male patient, reported with pain and swelling in the lower jaw. Patient had fall under the influence of alcohol following which he developed pain and swelling in the jaw. Provisionally case was diagnosed as left side mandibular angle fracture.[FIG 3](#)

Case 4:

A 21 year male patient, reported with pain and swelling with difficulty in opening the mouth. Patient had a history of road traffic accident 5 days back. Provisionally case was diagnosed as left body and angle fracture of mandible.[FIG 4](#)

Case 5:

A 24 year female patient, reported with pain and swelling over both sides of mandible with difficulty in mouth opening. Patient had a history of assault by her husband 4 days ago. Provisionally case was diagnosed as left side angle and right body fracture of mandible.[FIG 5](#)

Materials:

In this study stainless steel miniplates and screws were used for osteosynthesis. The screws were of the self tapping type.

Surgical procedure:

All patients were seated in semi supine position in dental chair. Extra oral scrubbing was done with diluted cetrimidectincture; mouth preparation with diluted povidone iodine. Draping was done with sterile towels so as to expose the whole face. 2% lignocaine with 1:80000adrenaline was used for suitable nerve block and infiltration to anesthetize the surgical site.

Incision:

The fracture site was exposed using an intraoral incision. Modified Ward’s incision was used and only the amount of soft tissue stripping necessary to visualize, reduce and stabilize the fracture was performed. Mucoperiosteum was reflected and fracture site exposed. Fractured tooth or roots were removed. After the fragments were manipulated into reduced position, with teeth in occlusion the jaws are placed into maxillomandibular fixation.

A four hole, non compression, stainless steel miniplate was adopted along the medial side of the external oblique ridge and screwed to the bone using 2.0mm self threading screws.[FIG 6](#) The three most anterior screws were inserted with the patient in maxillomandibular fixation. The most posterior screw, on the medial surface of the mandibular ramus was inserted after removing maxillomandibular fixation, allowing instrumentation between the upper and lower teeth from the opposite side.

A mouth prop placed on the contra lateral molars compressed the inferior aspect of the fracture line. This procedure has excellent adaptation at the inferior border.

Extra oral percutaneous trocar instrumentation:

Now the mucoperiosteum was elevated up to the inferior border. A second miniplate was then contoured and fixed with 2*6mm mono cortical screws using percutaneous instrumentation through a trocar and cannula placed by extra oral stab incision parallel to facial nerve fibers and plate placed under local anesthesia. [FIG 7](#) The mouth prop was removed, occlusion checked and the wound was closed with 3-0 black silk and no drains were placed.[FIG 8](#) Post surgical maxillomandibular fixation was not used in any patients.

Post operative care and follow up

Immediate care:

All patients were kept under antibiotic cover for 1 week. They were advised to take liquid diet for 2 days and thereafter on a soft diet for 4 weeks. Also they were advised to use warm saline gargle frequently to keep their mouth clean. Sutures were removed on the 7th post-operative day.

Long term follow up:

Follow-up was performed, weekly during the first 6 weeks and thereafter monthly. Follow-up ranged from 2 and a half to 1 year. Postoperative complications such as wound dehiscence, infection, neurosensory disturbance, malocclusion, non-union and post operative mouth opening were recorded.

Observation and Results [TABLE 1](#)

Ease of the technique:

The technical difficulty of placing inferior border plates in the angle region is overcome by percutaneous instrumentation using an extra oral trocar and cannula. Compression at the inferior border of mandibular angle while applying the second plate is made easy with the aid of a mouth prop placed on the contra lateral molars.

Occlusal stability:

All patients showed a stable occlusion post operatively. Incidence of posterior open bite on the side of fracture is nil with our technique even in horizontal unfavorable fracture.

Interincisal opening width:

The interincisal opening increased from 15mm in the immediate postoperative period to more than 40 mm when measured 3 months after surgery.

Signs of infection:

All patients treated with this technique showed no signs of infection. They were maintained on oral antibiotics for a week.

Trigeminal dysfunction:

There was no involvement of mandibular branch of trigeminal nerve, except in one case where there was neurosensory disturbance of mental nerve. This was attributed to the manipulation of the nerve during surgery for associated body fracture. After a period of 3 months the sensations recovered.

Functional stability:

In all the cases of our study intermaxillary fixations were released immediately after the surgery thus enabling immediate restoration of function. All our cases demonstrated good functional stability in the immediate postoperative period without any inter fragmentary mobility or posterior open bite on the side of fracture. Postoperative radiographs also showed no displacement of fragments and normal healing of bone. [FIG 9](#)[FIG 10](#)[FIG 11](#)[FIG 12](#)[FIG 13](#)Two patients had tenderness over the surgical site which was treated with analgesics.

II. Discussion

In the search for a simple osteosynthesis technique that would guarantee fracture healing, without intermaxillary fixation and without compression, the monocortical plate osteosynthesis² was modified and developed into a practicable clinical method³. Taking into account the anatomical factors and forces determined the ideal osteosynthesis line was defined. At the angle of the jaw, the plate is most favorably placed on the broad surface of the external oblique line as high as possible.

When using Champy's method for the management of mandibular angle fractures, a separation of the fracture line and lateral displacement of fragments at the lower mandibular border are often observed immediately. In addition a posterior open bite on the side of fracture is frequently observed immediately after fixation of the mandibular angle fracture at the superior border.

Three dimensional in vitro experiments suggest that two miniplate fixation should be used to avoid opening of the inferior fracture line, which is thought to contribute to occurrence of complications.⁴

To achieve primary intra operative anatomic alignment and stable fixation of the fracture, a two miniplate fixation technique is used in which one plate is applied at the superior border and a second at the inferior border of the mandible.

The main idea is to reduce separation of the fracture line and lateral displacement of the lower mandibular border, which was frequently observed on the post operative radiographs. However, application of two miniplates in the region of the mandibular angle through a transoral incision poses a technical problem because of difficult access and poor visibility. It may be that complications after the placement of second miniplate in the mandibular angle regions are closely related to this problem. The actual results of clinical studies using a two miniplate fixation system have been controversial.

Even though, Ellis, et al (1994)⁵, found an unacceptably high rate of complications using two miniplates, several authors reported excellent results. It is interesting to contemplate how a two miniplate fixation system can lead to a high complication rate. One thought is that it may be related to a technical factor, in addition to the technical difficulty of placing inferior border plates in this region, it is the attempt is made via a transoral approach. Compression exerted by the plates has been shown to help stabilize and heal the fracture site in compression osteosynthesis technique. It is easy to compress the fracture at the parasymphysis using reduction forceps. However, technical difficulties prevent compression at the inferior border of the mandibular angle. With the technique used compression can be applied in this region also.

An advantage of this technique is that patients are not placed into maxillomandibular fixation post operatively. Many authors who have advocated the use of a single miniplate for mandibular angle fractures are currently using maxillomandibular fixation. Although we use maxillomandibular fixation intra-operatively for maintaining occlusion and holding the fragments, it is released on the same day post operatively. This technique does not need post-operative elastic traction or maxillomandibular fixation to correct posterior open bite, because it produces both primary intra operative anatomic alignment of the fracture and correct occlusion.

Another great advantage of this technique is the ability to compress the fracture producing excellent adaptation and good stability at the fracture site.

III. Summary and Conclusion

One of the most frequent treatments provided by oral and maxillofacial surgeon is the management of mandibular fractures. The treatment of mandibular fracture is a matter that has given rise to great controversy, with respect to the type of material used at each location, possible adjunctive use of maxillomandibular fixation and delay of normal masticatory functional rehabilitation.

There are various options available to treat a mandibular angle fracture, but the results are somewhat compromised. The two miniplate technique has a definite better outcome as follows.

The following conclusions were drawn; though the clinical sample was small, this technique produced good primary intra-operative anatomic alignment by applying compression at the inferior border, two miniplates one at superior surface of external oblique ridge and another near the inferior border provided sufficient stability for uneventful healing even in severely displaced mandibular angle fracture, incidence of postoperative open bite is nil, as maxillomandibular fixation was not used, patients had a much faster rate of recovery of mandibular mobility, external scar as in extra-oral technique is overcome by use of trocar and cannula, as the technique can be performed under local anesthesia, patients who are unfit for general anesthesia can also benefit, it is also economical and affordable, more than 40 mm mouth opening could be achieved in 3 months postoperatively, incidence of complications are very low.

A more detailed study in larger group of patients with a long term follow up may throw more light on long term complications, if any on the technique. It can be concluded that the 2 miniplate fixation technique using a trocar and cannula is an effective procedure in producing good treatment results for angle fractures of mandible

Reference

- [1]. E.Ellis III: Treatment methods for fractures of mandibular angle. *Int. J. Oral Maxillofac. Surg.* 1999; 28: 273-252
- [2]. Michelet, et al; Osteosynthesis with miniaturized screwed plates in maxillofacial surgery. *J. Maxillofacial Surg.* 1973; 1: 79
- [3]. Champy M: Mandibular osteosynthesis by miniature screwed plates via a buccal approach. *Journal of Oral and Maxillofacial Surgery.* 1978; 6: 14
- [4]. Choi B.H., et al., Stability testing of a two miniplate fixation technique for mandibular angle fractures. An in vitro study. *J Craniomaxillofac. Surg.* 1995; 23(2): 123-5
- [5]. E.Ellis., et al., Treatment of Mandibular angle fractures using two non compression miniplates. *Journal of Oral and Maxillofacial Surgery.* 1994; 52(10): 1032-6

Legends:

- Fig 1: Case 1 preoperative OPG, showing fracture in the left angle of mandible
- Fig 2: Case 2 preoperative OPG, showing fracture in the left angle of mandible
- Fig 3: Case 3 preoperative OPG, showing fracture in the left angle of mandible
- Fig 4: Case 4 preoperative OPG, showing fracture in the right angle of mandible
- Fig 5: Case 5 preoperative OPG, showing fracture in the left angle of mandible
- Fig 6: First miniplate fixed
- Fig 7: Extra oral trocar instrumentation
- Fig 8: Postoperative occlusion
- Fig 9: Case 1 postoperative OPG, showing two miniplates
- Fig 10: Case 2 postoperative OPG, showing two miniplates
- Fig 11: Case 3 postoperative OPG, showing two miniplates
- Fig 12: Case 4 postoperative OPG, showing two miniplates
- Fig 13: Case 5 postoperative OPG, showing two miniplates

S. N O	NAME	AGE /SEX	ETIOLOGY	DIAGNOSIS	TREATMENT	MOUTH OPENING		NEUROSENSORY COMPLICATION	INFECTION	OCCLUSION
						IMMEDIATE	AFTER 3 MONTHS			
1	KRISHNAN	29/M	RTA	# MANDIBLE LEFT ANGLE & RIGHT PARASYMPHYSIS	ORIF WITH 2 MINIPLATE TECHNIQUE OF LEFT ANGLE & 2 MINIPLATES FOR RIGHT PARASYMPHYSIS	18 mm	42 mm	NIL	NIL	NIL
2	MOORTHY	40/M	RTA	# MANDIBLE LEFT ANGLE	ORIF WITH TWO MINIPLATE TECHNIQUE	20 mm	40 mm	NIL	NIL	NIL

“Two Miniplate Technique for Treatment of Mandibular Angle Fracture- Original Study”

3	BASKAR	33/ M	FALL	# MANDIBLE LEFT ANGLE AND RIGHT BODY	ORIF WITH TWO MINIPLATE TECHNIQUE FOR LEFT ANGLE # & ORIF WITH SINGLE MINIPLATE FOR RIGHT BODY	15 mm	40 mm	Mental nerve paresthesia recovered after 3 months	NIL	NIL
4	SIGAMA NI	21/ M	RTA	# MANDIBLE RIGHT ANGLE AND LEFT BODY	ORIF WITH SINGLE MINIPLATE FOR LEFT BODY # AND TWO MINIPLATE TECHNIQUE FOR RIGHT ANGLE	24 mm	45 mm	NIL	NIL	NIL
5	SATHYA	24/F	ASSA ULT	# MANDIBLE LEFT ANGLE AND RIGHT BODY	ORIF WITH TWO MINIPLATE TECHNIQUE FOR LEFT ANGLE AND A MINIPLATE FOR RIGHT POST CANINE #	20 mm	51 mm	NIL	NIL	NIL

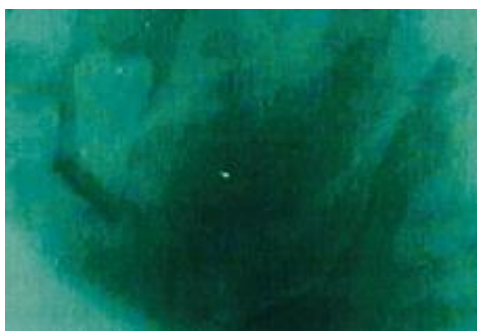

FIG-1

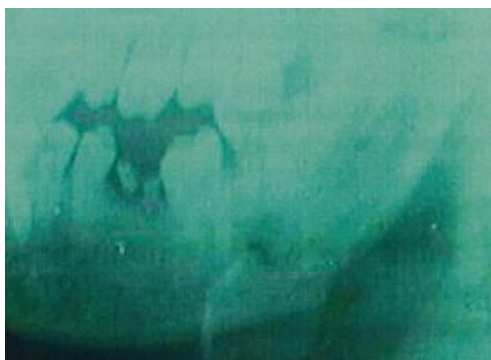


FIG-2

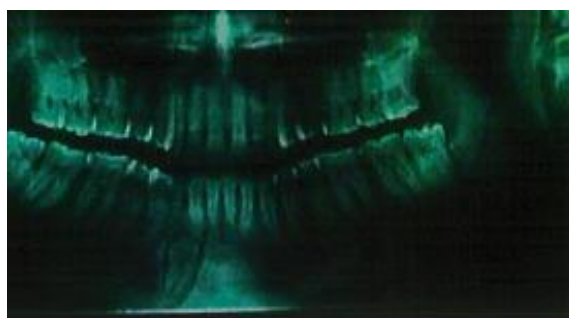

FIG-3

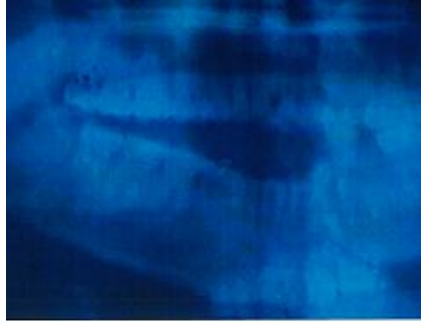


FIG-4

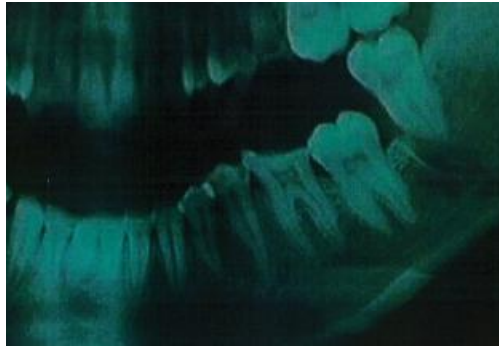


FIG-5

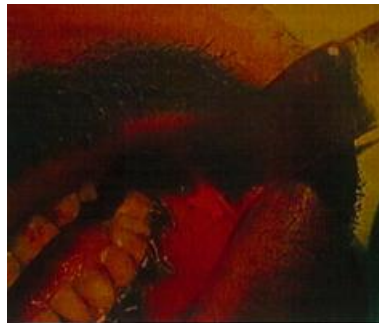

FIG-6



FIG-7

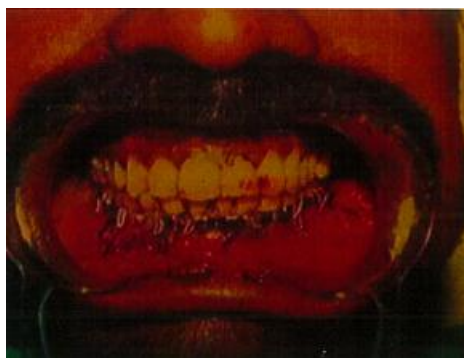

FIG-8

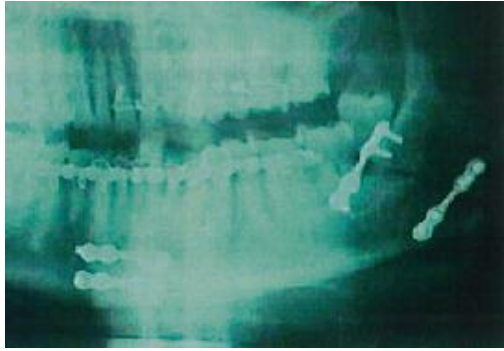

FIG-9

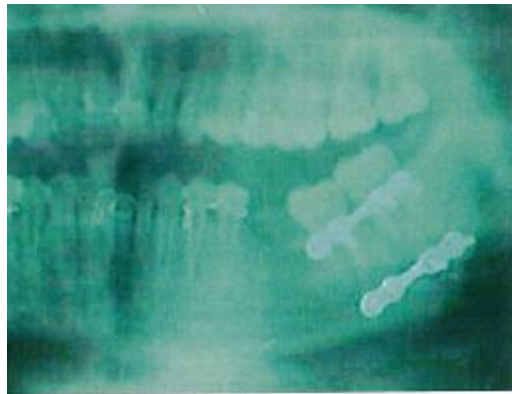


FIG-10

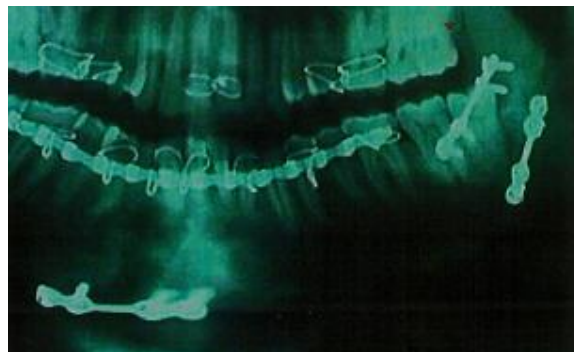


FIG-11

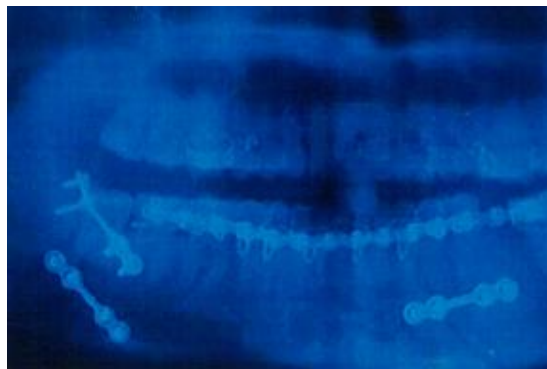


FIG-12

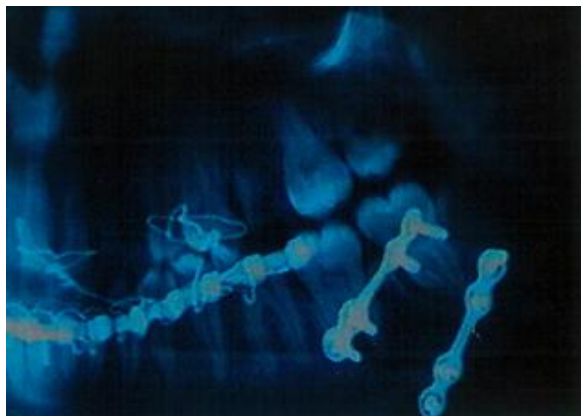


FIG-13

Dr.Maruthavanan Rajmohan MDS, “Two Miniplate Technique for Treatment of Mandibular Angle Fracture- Original Study”. IOSR Journal of Dental and Medical Sciences (IOSR-JDMS), vol. 18, no. 3, 2019, pp 66-73.