

Comprehensive Management of an Unusual Case of Multiple Complex Odontoma.

Dr. Jithin Jose¹, Dr. Kannan Vadakkepurayil², Dr. Madhu S³

(Department of Pedodontics and Preventive Dentistry, Government Dental College, Kozhikode, Kerala)

Abstract: *Complex odontoma is an agglomerate of all the dental tissues that are characterized by normal histodifferentiation and abnormal morphodifferentiation producing little or no resemblance to normal tooth form. They are usually characterized by slow growth, nonaggressive behaviour and is asymptomatic but often associated with eruption disturbances. An interesting case of unusually large multiple complex odontoma in the maxillary anterior region and its comprehensive management is discussed in detail in this paper.*

Keywords: *Complex odontoma, Compound Odontoma*

Date of Submission: 11-03-2019

Date of acceptance: 27-03-2019

I. Introduction

Odontomas are developmental anomalies resulting from the growth of completely differentiated epithelial and mesenchymal cells that give rise to functional ameloblast and odontoblast¹. Odontomas have been classified as benign odontogenic tumours and are subdivided into complex or compound odontomas morphologically². Complex odontoma is seen as an amorphous and disorderly pattern of calcified dental tissues and compound odontoma, occurs as multiple miniature or rudimentary teeth. Compound odontomas commonly occur in the incisor-canine region of the maxilla and complex odontomas are frequently seen in the premolar and molar region of both jaws³.

Both variants are made of all dental tissues such as enamel, dentin, cementum, and pulp⁴. Compound odontomas have numerous tooth-like structures; with altered size and shape known as denticles. On x-ray evaluation, compound odontomas appear as well demarcated lesions with a radiolucent halo containing radiopaque zones which represent small denticles, separated by fibrous septae, while in the complex types the radiopaque zones appear as irregular and disorderly masses with no similarity to dental structures⁵.

Both compound and complex odontomas commonly occur as solitary lesions in the jaw. Multiple odontoma is characterized by numerous odontomas involving one to four quadrants of the jaws⁶. Multiple odontoma also can occur with other malformations, such as stenosis of the esophagus⁷. The terms "odontomatosis" and "odontoma syndrome" have been suggested to describe multiple odontoma⁸. Due to its rarity, little is known about the comprehensive clinical features of multiple odontoma. Radiologic diagnosis of a single or multiple compound odontoma based on the presence of characteristic tooth like structures is not difficult. However, multiple and massive complex odontomas, exhibiting amorphous calcification, raise many possible differential diagnoses and constitute a diagnostic and therapeutic challenge. In all cases, surgical removal represents the best therapeutic option and the prognosis after treatment is very favorable, with very low incidence of recurrence.

This case report discusses a rare case of multiple complex odontoma in an eleven year old female patient and its comprehensive management.

II. Case Report

An eleven year old girl reported to the Department of Pedodontics, Government Dental College Kozhikode, Kerala with a complaint of unerupted teeth and swelling in relation to upper anterior region of the mouth since three months. The patient had no significant past medical and family history and had not reported oral trauma or infections previously. Extra-oral examination showed large thick ears, bulbous nose having a convex profile with mild maxillary excess and mandibular deficiency (Fig 1A, 1B). Intra-oral examination revealed multiple missing or unerupted teeth with diffuse swelling in relation to maxillary anterior region especially on the alveolar ridge region on left side. The swelling was non-tender and mucosa was intact. The lower primary anterior teeth were found to be retained and covered with calculus (Fig 2A, 2B, 2C). All the existing primary dentition was seen to be undergone severe attrition with amorphous crown structure.. The four permanent molars were also structureless and partially erupted; with gingival tissue covering almost half of the crown structure (Fig 3A, 3B). The child was having difficulty in speech, mastication and was shy while speaking due to poor esthetics (due to missing upper anterior teeth).

Panoramic radiograph showed a predominantly radiopaque mass similar in density to calcified dental tissues, with small radiolucencies within, in relation to 12,11,21 and 22 region. 15,25,35,45,31,32, and 41 teeth were congenitally missing; also the tooth buds of all the four permanent third molars were absent. All the existing dentition was seen to be amorphous in size and shape in the panoramic radiograph. A generalized unusual pattern of bony trabeculations with non-specific radiolucency was seen in the anterior mandibular region (Fig 4A, 4B).

A provisional diagnosis of odontoma was made based on the clinical and radiological presentations, and the child was sent to genetic clinic in the Department of Paediatrics, Government Medical College Kozhikode, Kerala to rule out any syndromic association for the condition. In accordance with the expert opinion from the paediatrician and after obtaining consent from the parent, surgical removal of the calcified mass was planned by trans-oral approach under local anaesthesia. A buccal muco-periosteal flap was raised with respect to maxillary anterior region and the tumour was located. The tumour was enucleated intact using an osteotome and a periosteal elevator, while maintaining continuity of the underlying structures; and the enucleated calcified masses were submitted for histopathological examination. The tumour cavity walls were smoothed using a bone file and thoroughly irrigated with saline to remove all bony spicules (Fig 5A, 5B, 5C). The tumour cavity walls were then packed with Ab-gel (absorbable haemostatic gelatin sponge) and the surgical wound was closed primarily with 3/0 Vicryl sutures (Fig 6A, 6B). The patient was prescribed antibiotics and analgesics along with 0.2% chlorhexidine mouth rinse twice a day. Post-operative recovery was uneventful and intraoral healing was satisfactory with no sensory nerve deficit and the patient was advised for regular follow-up.

Histopathological examination of the excised mass showed irregularly arranged dental hard tissues with areas of cell rich pulpal tissue. Clear spaces and clefts representing the mature enamel that is lost in the process of decalcification are often seen confirming the diagnosis of multiple complex odontoma. Few islands of odontogenic epithelium along with thin fibrous capsule surrounding the lesion are evident (Fig 7).

After six months of surgery the patient was reviewed and the remaining retained and mobile deciduous teeth (53,54,63,64,84,81,71,72 and 74) were removed on multiple visits under local anaesthesia. All the deciduous second molars were retained and restored to enhance retention of the prosthesis; which was intended to replace the missing teeth later. Gingivectomy procedure was done in relation to all partially erupted permanent first molars exposing the crown portion and stainless steel crown was cemented over it (Fig 8A, 8B). The stainless steel crown was used to enhance the vertical dimension at occlusion and also served to increase the retention of the prosthesis. The upper and lower impressions were made using alginate and flexible removable partial dentures (Sunflex RPD) (Fig 9A, 9B, 9C) were fabricated after proper jaw relation and trial setting (Fig 11A, 11B). To date, the patient has been followed up for a period of 15 months and there has been no clinical or radiographic evidence of recurrence (Fig 10). She will be considered for autogenous bone grafting and placement of osseointegrated dental implants and an overlying fixed prosthesis in the future.

III. Discussion

The term odontoma firstly described by Paul Broca in 1867 was originally used as a general descriptive for any tumor of odontogenic origin. However, owing to their composition and behaviour, odontomas have become known as hamartomatous lesions or malformations rather than true neoplasms; the epithelial and the ectomesenchymal tissues along with their respective cells may appear normal, but they seem to have a deficit in the structural arrangement. Odontomas are intraosseous lesions mainly located in the anterior maxilla and anterior mandible, although lesions localized in gingival soft tissues have also been reported⁹. The majority of odontomas are asymptomatic, although swelling, pain, suppuration, bony expansion, and displacement of teeth have been rarely observed. Their pathogenesis has been associated with a number of causes including trauma during primary dentition¹⁰, hereditary anomalies such as Gardner's syndrome, Hermann's syndrome, and basal cell nervous syndrome, odontoblastic hyperactivity, or alterations of the genetic components responsible for controlling dental development^{4,9}.

The exact etiology of multiple complex odontome is unknown. Several theories have been proposed, including local trauma, infection, family history, and genetic mutation. It has also been suggested that odontomas are inherited from a mutant gene or interference, possibly postnatal with the genetic control of tooth development¹¹. The development of the odontoma is commonly associated with eruption failure of permanent teeth, impaction, and delayed exfoliation of primary teeth¹². Although odontoma is a very common odontogenic tumor, multiple odontoma involving numerous sites of the jaws is not frequently encountered. Multiple odontoma can present as a congenital lesion and grow expansively and can involve one to four quadrants of the jaws. The tumors may be extensive or composed of several localized lesions. Multiple odontoma can be made up of different histologic types of odontoma, including compound, complex, or both⁸. The lesions could be cystic or may develop with increasing enamel and dentin formation within the odontogenic epithelium¹³. Stenosis of

the esophagus is reported to be associated with multiple odontoma¹⁴. Other related malformations, including stenosis of aortae, sight disorder, and bronchiectasis, have been described.

The radiologic appearances of odontoma are associated with the stages of development and mineralization⁵. With histologic differentiation into enamel and dentin, the correspondingly mixed radiopaque attenuation will appear and increase¹⁵. Completely radiolucent odontomas without calcification are rare. Partial calcification within a cystic radiolucency is frequently observed, indicating a developing lesion. In the mature stage, the calcification occupies most of the tumor, surrounded by a narrow radiolucency.

Multiple odontoma should be differentiated from bone-related lesions and odontogenic tumors with hard tissue formation. Identification of enamel attenuation is important because it is not present in bone-related lesions, such as fibrous dysplasia and ossifying fibroma. Interference with the impacted and displaced tooth at the peripheral border of the tumor also indicates an odontogenic origin. Odontogenic tumors with hard tissue formation, such as the adenomatoid odontogenic tumor, calcifying epithelial odontogenic tumor, ameloblastic fibro-odontoma, and odontoameloblastoma, may not be easily distinguishable from odontoma⁷. The adenomatoid odontogenic tumor shows a prominent association with unerupted permanent teeth, especially the canines. The radiopacities inside the adenomatoid odontogenic tumor are frequently small, less radiodense, and arranged in circular or irregular clusters. The most characteristic finding of a calcifying epithelial odontogenic tumor is the appearance of radiopacities close to the embedded tooth inside a cystlike radiolucency. Mineralized dental tissues are also formed in ameloblastic fibro-odontoma and odontoameloblastoma, which sometimes cannot be differentiated from developing complex odontoma radiologically or pathologically. In this consideration, biopsy is needed to consolidate the diagnosis and to exclude the potential malignant transformation¹⁴.

The surgical management of the odontoma should be conservative, and enucleation of the tumor is the first treatment of choice. For massive tumors, two-staged removal can also be considered to preserve mandibular function and decrease the risk of pathologic fracture¹⁶.

IV. Figures

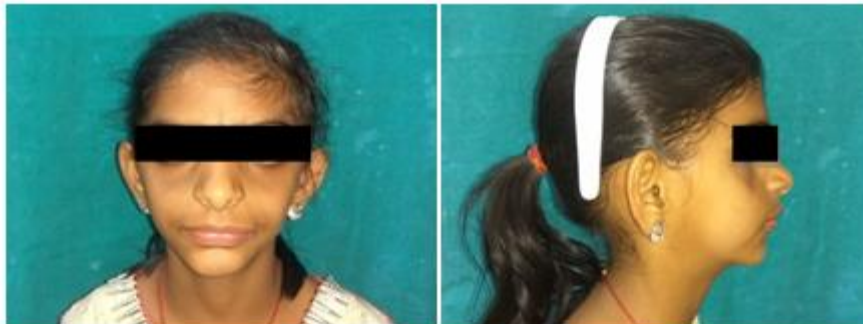

Figure 1A, 1B

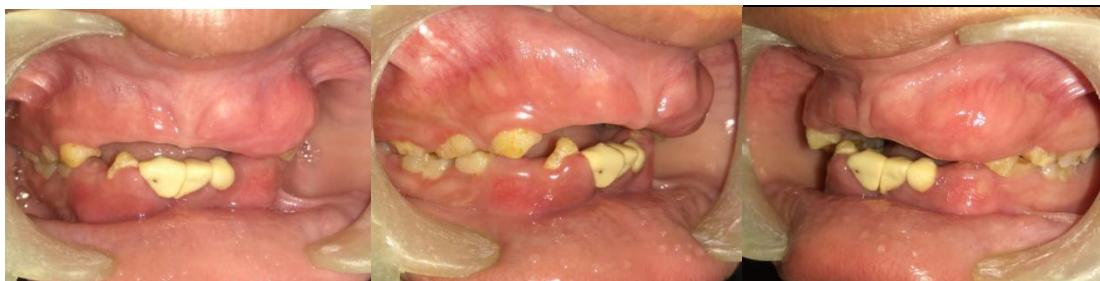

Figure 2A, 2B, 2C

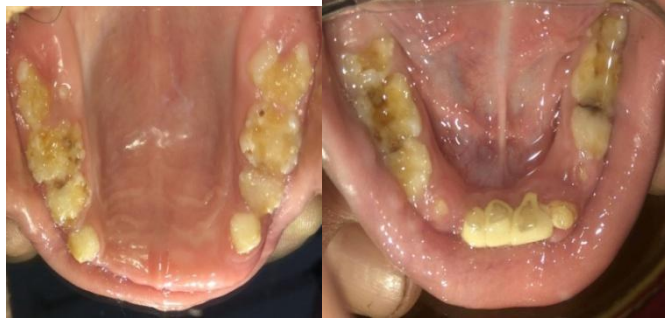

Figure 3A, 3B

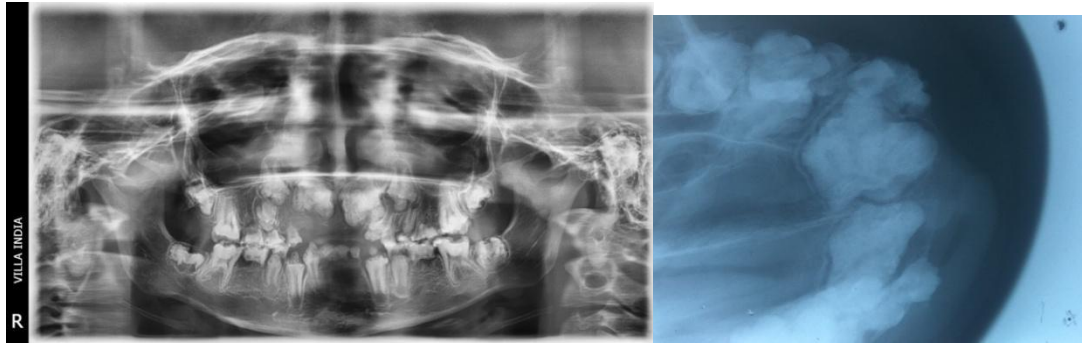

Figure 4A, 4B

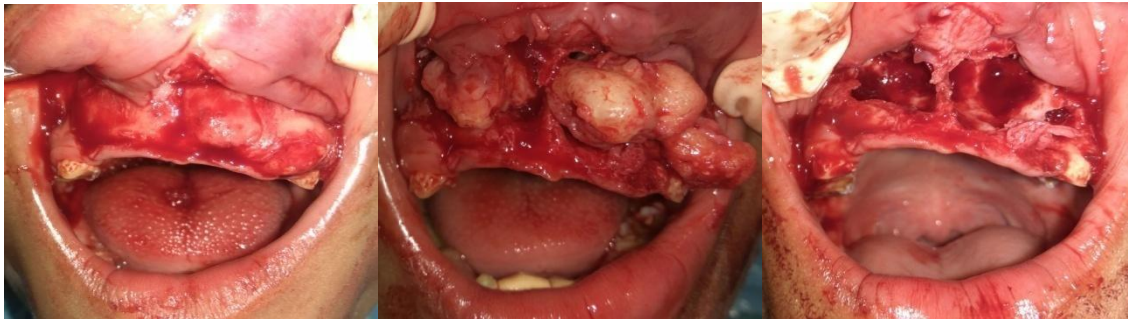

Figure 5A, 5B, 5C

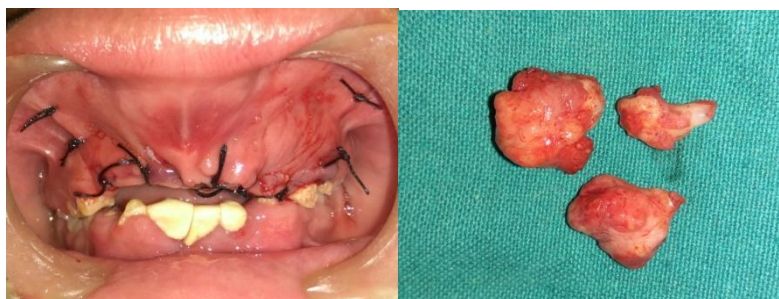


Figure 6A, 6B

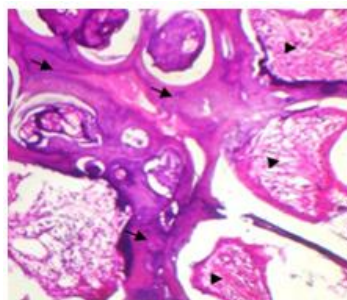


Figure 7

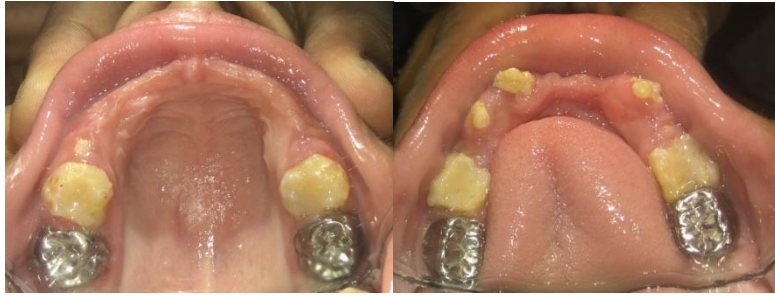

Figure 8A, 8B

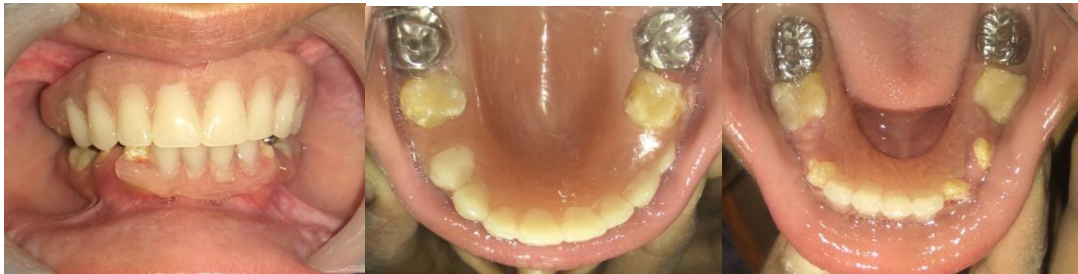

Figure 9A, 9B, 9C

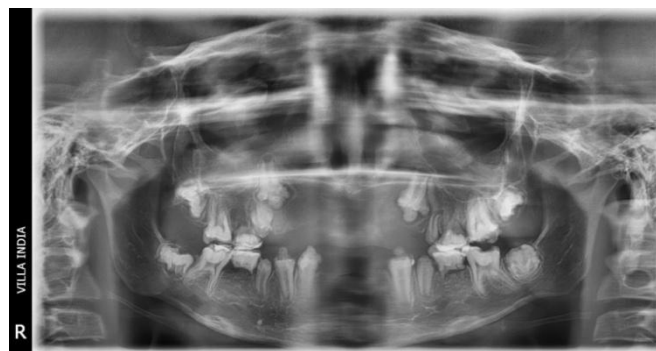

Figure 10



Figure 11A, 11B

Figure Legends

1A, 1B- Extra-oral frontal and profile view showing showing large thick ears, bulbous soft nose and convex profile.

2A, 2B, 2C- Intra-oral view showing swelling in relation to maxillary anterior region and retained lower primary anteriors.

3A, 3B- Maxillary and mandibular occlusal view showing multiple missing teeth and existing amorphous dentition.

4A, 4B- Panoramic and maxillary occlusal radiographs showing radiopaque masses in relation to maxillary anterior region and multiple missing teeth.

5A, 5B, 5C- Intra-operative view showing raised muco-periosteal flap, localized odontomes and enucleated tumour cavity walls.

6A, 6B- Post-operative view showing sutured surgical wound and enucleated odontomes.

7- Decalcified and stained section showing dentin (arrow) and pulp tissues (arrow head).

8A, 8B- Maxillary and mandibular occlusal view showing stainless steel crowns cemented on all permanent first molars following gingivectomy and restored second primary molars.

9A, 9B, 9C- Esthetic and functional rehabilitation of missing teeth using flexible removable partial denture.

10- Post-operative panoramic radiograph

11A, 11B- Frontal views of patient with and without flexible removable partial denture.

V. Conclusion

This case highlights the extensive nature and rare presentation of erupting multiple complex odontomas. They may increase in size after calcification and lead to complications. Multiple odontomas can be local or extensive, involving numerous quadrants of the jaws. A thorough knowledge and an excellent evaluation of X-ray documents are essential to resolve each clinical case adequately. The adoption of a conservative surgical approach is advisable, in order to preserve the dental tissues and obtain optimal tissue healing. A histological evaluation is necessary to confirm the correct diagnosis of odontoma.

References

- [1]. Shafer WG, Hine MK, Levy BM. A textbook of oral pathology. 4th. 1983.
- [2]. Kramer IRH, Pindborg JJ, Shear M. The WHO histological typing of odontogenic tumours. A commentary on the second edition. *Cancer*. 1992;70(12):2988-2994.
- [3]. Stajcic ZZ. Odontoma associated with a primary tooth. *J Pedod*. 1988;12(4):415.
- [4]. Yildirim-Öz G, Tosun G, Kiziloğlu D, Durmuş E, Şener Y. An unusual association of odontomas with primary teeth. *Eur J Dent*. 2007;1(1):45.
- [5]. An S-Y, An C-H, Choi K-S. Odontoma: a retrospective study of 73 cases. *Imaging Sci Dent*. 2012;42(2):77-81.
- [6]. Malik SA, Khalid M. Odontomatosis (multiple odontomas)—a case report. *Br J Oral Surg*. 1974;11(3):262-264.
- [7]. Schmitseder R. Multiple odontogenic tumors and other anomalies.
- [8]. Mani NJ. Odontoma syndrome: report of an unusual case with multiple multiform odontomas of both jaws. *J Dent*. 1974;2(4):149-152.
- [9]. Otsuka Y, Mitomi T, Tomizawa M, Noda T. A review of clinical features in 13 cases of impacted primary teeth. *Int J Paediatr Dent*. 2001;11(1):57-63.
- [10]. Noonan RG. Abbreviated case report: A compound odontoma associated with a deciduous tooth. *Oral Surgery, Oral Med Oral Pathol*. 1971;32(5):740-742.
- [11]. Reichart PA, Philipsen HP. *Odontogenic Tumors and Allied Lesions*. Quintessence Pub.; 2004.
- [12]. Sánchez OH, Isabel M, Berrocal L, M^a J, González M. Metaanalysis of the epidemiology and clinical manifestations of odontomas. 2008;13(11):730-734.
- [13]. Iwamoto O, Harada H, Kusukawa J, Kameyama T. Multiple odontomas of the mandible: a case report. *J oral Maxillofac Surg*. 1999;57(3):338-341.
- [14]. Bader G. Odontomatosis (multiple odontomas). *Oral Surgery, Oral Med Oral Pathol*. 1967;23(6):770-773.
- [15]. White SC, Pharoah MJ. *Oral Radiology: Principles and Interpretation*. Elsevier Health Sciences; 2013.
- [16]. Chrcanovic BR, Jaeger F, Freire-Maia B. Two-stage surgical removal of large complex odontoma. *Oral Maxillofac Surg*. 2010;14(4):247-252.