

Comparison of the Functional Outcomes of Distal Tibia Fractures Treated By Minimal Invasive Locking Plating Osteosynthesis or Intra Medullary Inter Locking Nailing

Dr.M.C.Chinnadurai Ms Ortho Dr.E.Siva Ms Ortho

Elangovan Hospital Pattukkottai

Date of Submission: 22-02-2019

Date of acceptance: 08-03-2019

I. Introduction

Treatment of distal tibia fractures carries a high complication rate. Current principle in their treatment is biological osteosynthesis with minimal surgical soft tissue invasion. Here Minimal Invasive Locking Plating Osteosynthesis (MILPO) and Intra Medullary Inter Locking Nailing (IMIL) are the preferred techniques. In the present study, we have analyzed the effects of minimally invasive percutaneous locking plates *versus* interlocking intramedullary nailing in treating distal tibia fractures in adults. In this prospective study, 30 closed distal tibia fractures (AO 43 A type fractures) were treated either by IMIL (Group-1n=15) or MILPO (Group-2 n=15) and were followed up for a mean period of two years. Both radiological correction of the pre-operative valgus and Functional outcome (Karlsson & Peterson scoring system) is similar between the two groups. For distal tibia metaphyseal fracture osteosynthesis, MILPO and IMIL share the same principle respecting the soft tissue. Apart from the anterior knee pain, nailing of this short distal fragment can lead to malalignment. MILPO causes skin irritation and neurovascular injury. Between them MILPO require more surgical expertise but have less complications. Even though the functional scores are comparable between MILPO and IMIL, the former has fewer complications.

Key words: Distal tibia fractures, MILPO, IMIL

II. Epidemiology

Fractures of the tibia and fibula are relatively common and have been recognized as serious and debilitating injuries for centuries. Descriptions of the treatment of tibial fractures are included in the Edwin Smith Papyrus, an ancient Egyptian medical text dating back to at least 1500 to 1600 BC¹.

High-energy tibial diaphyseal fractures are most commonly associated with vehicular trauma. The most common mechanism is the pedestrians being struck (59.2% of vehicular injuries), followed by motorcycle crashes (22.4%)². The most common causes of low-energy tibial fractures, falls from a standing height and sporting injuries. Soccer injuries accounting to as many as 80%². High rates of ski related injuries have been reported in Swiss studies³. The term distal tibial fractures encompasses a broad array of injuries involving the distal metadiaphyseal and metaphyseal region. They are estimated to comprise 3% to 10% of all tibial fractures. Compared to fractures elsewhere in the body, tibial fractures have relatively high rates of nonunion and malunion.

Distal tibial fractures are well known as a significant treatment challenge to most of the orthopaedic surgeons. Given the often diverse fracture patterns, a variety of operative strategies have evolved to treat these injuries. The goal is to maximise fracture stability without increasing soft tissue morbidity from surgical intervention. In current orthopaedic practice, minimally invasive locking plating osteosynthesis (MILPO) and interlocking nailing are the preferred techniques for distal tibia fractures.

III. Methodology

This study was conducted in rural orthopedic hospital, on patients having fracture of the distal tibia. This study included 30 patients of distal tibia fractures with age ranging from 19-60 yrs, who were treated with minimally invasive percutaneous plate osteosynthesis (MILPO) technique and intramedullary interlocking nail.

Inclusion criteria

1. Distal tibia fractures
2. Age >19 years skeletal matured
3. Extraarticular fractures

Exclusion criteria

1. Intra articular fractures
2. Compound fractures
3. Malunited / non union fractures
4. Paediatric fractures
5. Multiple injuries
6. Segmental fractures
7. Stress /pathological fractures

The total number of patients in my study are 30 they are divided into group A and group B . group A consists of 15 patients and group b consists of 15 patients. The type of fixation was selected according to the choice of the patient.

These fracture are classified according to AO classification. The functional outcome is analyzed according to 100 points scoring KARLSONS and PERTERSON scoring system. The outcome is divided into excellent , good fair and poor.

Implant of choices : Intramedullary interlocking nail nail sizes from 28 to 34 cm diameter 8 to 10mm with or without fibular plating with one third tubular plate, medial and lateral distal tibial locking plates

IV. Operative Technique For Nailing And Medial And Lateral Milpo

For intramedullary nailing

Patient positioning: Include following steps

- Place the patient supine on fracture table after appropriate anesthesia.
- Apply the tourniquet on upper thigh.
- Confirm that unhindered anteroposterior and lateral view can be obtained under c-arm.

Incision: Include following steps

- Incision is taken after limb is exsanguinated and tourniquet inflated.
- We have used patellar tendon splitting approach.
- Mark the incision from lower pole of patella to the tibial tuberosity and incise the skin and subcutaneous tissue.
- Split the patellar tendon with the help of stab knife,deep to it lies the anterior tibial surface.

Entry point: Include following steps

- Entry into medullary canal is made with curved awl.
- Obtain a true anteroposterior view of upper tibia when assessing placement of awl.
- The safe zone (McConnell et al.)⁴ of entry point placement is medial to lateral tibial spine on anteroposterior view and immediately adjacent and anterior to articular surface on lateral view.
- Place the curved awl on predetermined entry site.
- Direct the awl nearly perpendicular to the shaft when it first penetrates the cortex, but gradually bring it down to a position more parallel to shaft as it is inserted more deeply to avoid violation of posterior cortex.
- Make entry wider enough to permit placement of nail without resistance.

Nail insertion: Include following steps

- Exchange the ball tip guide wire before inserting nail.
- Attach the insertion device and proximal locking screw guide to the measured size nail.
- Direct the apex of proximal bend in the nail posteriorly and mount the drill guide to direct screws from medial to lateral.
- Insert the nail with knee in flexion to avoid impingment on patella.
- Evaluate the rotational alignment by aligning iliac crest, patella and second ray of foot.
- Moderate manual pressure with gentle back and forth twisting motion usually is sufficient for nail insertion.
- If mallet is used, the nail should advance with each blow of nail. If nail does not advance, withdraw the nail, and perform further reaming or insert smaller diameter nail.
- When the nail has passed well into the distal fragment, remove the guide wire, to avoid incarceration, and during final seating of nail, release manual traction to allow final seating of nail.
- When the nail is fully seated, the proximal end should lie approximately 0.5 to 1 cm below the cortical opening of entry portal.
- The distal tip of nail should lie approximately 0.5 to 2 cm from subchondral bone.
- Confirm the nail position in anteroposterior and lateral views.
- Insertion of locking screws.
- Insert the proximal locking screws using the jig attached to nail insertion device.
- Place the drill sleeve through a small incision down to the bone, drilling is done, screw length is measured with help of depth gauge, and screw is inserted.

- The screw should protrude 5 mm beyond the far cortex to enable the screw to be removal more easily if breakage occurs.
- Use 2 proximal locking screws in most fractures.
- Tighten all connections between the insertion device, drill guide, and nail before screw insertion.
- Perform distal locking by freehand technique after “perfect circles” are obtained by c-arm.
- In the lateral position, adjust the fluoroscopic beam until it is directed straight through the distal screw holes.
- Drill the hole, confirm position on anteroposterior and lateral views, measure the length and insert the screw
- At least 2 distal screws should be inserted.

For Minimal Invasive Locking Plate Osteosynthesis

Position: Include following steps

- Place the patient supine on operating table with tourniquet in place.
- Confirm both anteroposterior and lateral views on image intensifier.
- Place a sandbag under ipsilateral buttock to correct natural external rotation of the limb.

Incision: Include following steps

For Lateral Plating

- A longitudinal and straight incision should be centered at the ankle joint , parallel to the fourth metatarsal distally, and between the tibia and fibula proximally. Extension of the incision should three to five centimeters and above the joint.
- Tibialis anterior , Extensor hallucis with Neurovascular structures retracted anteriorly and Digitorum retracted posteriorly .
- Using plate inserter , a submuscular tunnel created and appropriate size plate inserted.
- Because the periosteum of the tibia supplies significant amount of blood to the bone it should not be removed and plate should be applied epi-periosteal position.

Fracture reduction and provisional fixation: Include following steps

- Position the plate on the bone and reduce the fracture manually.
- Confirm the coronal and sagittal alignment as well as plate position on the shaft.
- Fix the plate to the diaphysis with two diaphyseal provisional fixation pins allowing adequate spread between them.
- Place the metaphyseal provisional fixation pin through one of the distal holes above the joint.
- Once accurate position of the plate has been achieved, insert a conventional screw in one of the most distal plate holes to approximate the plate close to the bone.

Final plate fixation: Include following steps

- Proceed with the definitive fixation of fracture using locked screws. Usually, the metaphysis requires more screws than the diaphysis.
- If non-locking screws are needed for either fragment, they must be inserted prior to the insertion of locking screw in that fragment.
- Confirm the placement by obtaining anteroposterior and lateral c-arm images.
- Tourniquet deflated, hemostasis achieved and wound closure done.

Table : 1

S.N O	A/S	AO CLASSIFICA TION	PRE OP VALGUS	POST OP VALGUS	PROCEDURE	KARLSSON & PETERSON SCORE		COMPLICAT ION
1	35/M	43A3	11.96	2.13	IMIL FIBULAR PLATE	85	Excellent	ANT KNEEPAIN
2	40/M	43A1	12.67	5.46	IMIL FIBULAR PLATE	75	Good	
3	28/F	43A2	26.1	2.71	IMIL FIBULAR PLATE	90	Excellent	
4	43/M	43A3	10	5.76	IMIL FIBULAR PLATE	90	Excellent	
5	45/M	43A3	13.21	4.31	IMIL FIBULAR PLATE	90	Excellent	ANT KNEEPAIN
6	60/M	43A1	6.93	3.39	IMIL FIBULAR PLATE	75	Good	
7	55/M	43A1	11.75	1.73	IMIL FIBULAR PLATE	80	Excellent	
8	40/M	43A1	9.8	5.44	IMIL FIBULAR PLATE	70	Good	ANT KNEEPAIN
9	42/M	43A1	8.4	5.24	IMIL FIBULAR PLATE	85	Excellent	
10	46/M	43A1	0.66	6.24	IMIL FIBULAR PLATE	58	Good	
11	23/M	43A1	8.86	7.94	IMIL FIBULAR PLATE	88	Excellent	SHORTENIN G
12	43/M	43A1	11.1	7.67	IMIL FIBULAR PLATE	80	Excellant	
13	35/M	43A1	11.6	5.46	IMIL	85	Excellant	ANT KNEEPAIN
14	40/M	43A1	8.72	4.88	IMIL	68	Good	
15	50/M	43A1	13.6	4.46	IMIL	73	Good	

IMIL

PROCEDURE	
IMIL FIBULAR PLATING	12
IMIL	3

AO CLASSIFICATION	CASES
43A1	11
43A2	1
43A3	3

KARLSSON & PETERSON SCORE	
EXCELLENT	9
GOOD	6

Table: 2

S.N o	A/S	AO CLASSIFICATIO N	PRE OP VALGU S	POST OP VALGU S	PROCEDURE	KARLSSON & PETERSON SCORE		COMPLICATIO N
1	19/ M	43A1	10.7	4.18	LATERAL MILPO	68	Good	
2	38/M	43A3	5.25	3.55	MEDIAL MILPO	88	Excellant	
3	43/M	43A2	12.5	3.9	MEDIAL MILPO	93	Excellant	
4	38/M	43A3	9.5	2.8	MEDIAL MILPO	83	Excellant	
5	25/M	43A3	7.3	3.22	MEDIAL MILPO	85	Excellant	
6	60/F	43A3	12.4	8.48	LATERAL MILPO	90	Excellant	
7	44/M	43A3	9.97	6.74	LATERAL MEDIAL MILPO	90	Excellant	
8	45/M	43A3	6.7	5.71	MEDIAL MILPO	85	Excellant	
9	35/M	43A3	8.74	6.15	LATERAL MILPO	65	Good	
10	47/M	43A1	8.6	2.46	LATERAL MILPO	65	Good	
11	35/M	43A1	11.5	5.34	LATERAL MILPO	95	Excellant	
12	43/M	43A3	13.7	1.99	MEDIAL MILPO	90	Excellant	
13	42/M	43A3	6.04	4.85	MEDIAL MILPO	80	Excellant	
14	50/M	43A3	10.45	6.56	LATERAL MILPO	78	Good	PERIIMPLANT #
15	48/M	43A1	6.24	2.16	LATERAL MILPO	63	Good	SUPERFICIAL INJECTION

PROCEDURE	
MEDIAL PLATING	7
LATERAL PLATING	7
MEDIAL LATERAL PLATING	1

AO CLASSIFICATION	CASES
43A1	4
43A2	1
43A3	10

KARLSSON & PETERSON SCORE	
EXCELLENT	10
GOOD	5

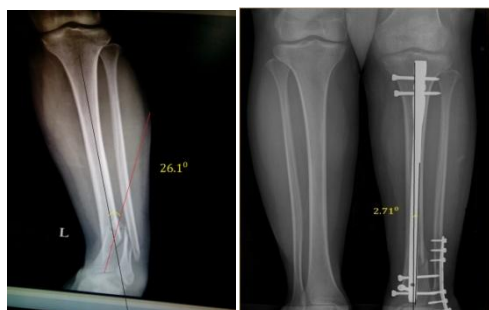

Table: 1 Case No.3

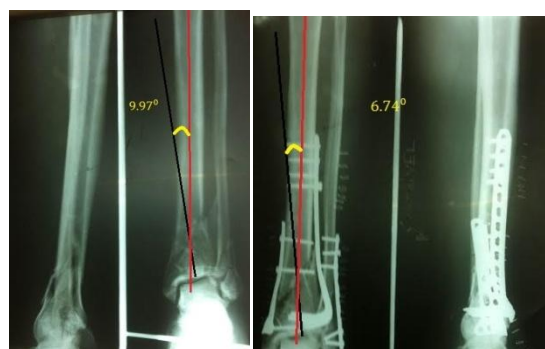

Table: 2 Case 7 Medial Lateral Plate

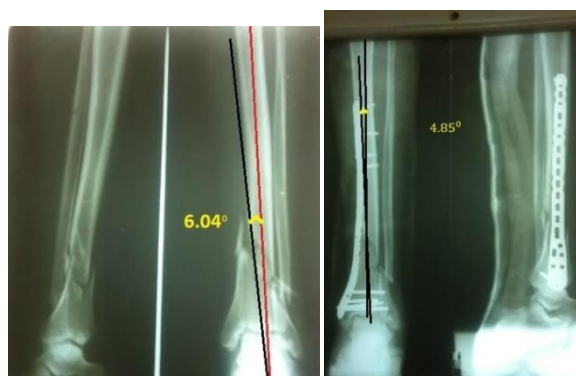


Table: 2 Case 13 Medial Plate

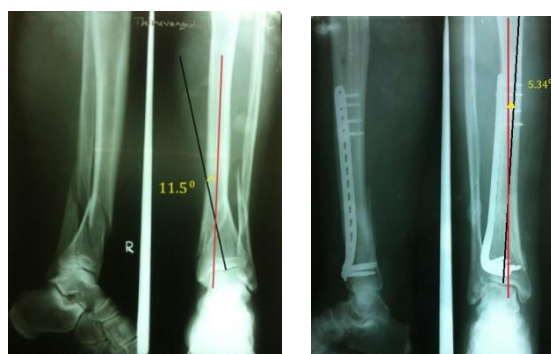

Table:2 Case 11 Lateral Plate

For Medial Plating

Position: Include following steps

- Place the patient supine on standard operating table.
- Confirm that unhindered anteroposterior and lateral views under fluoroscopy can be achieved.
- Obtain gross alignment using manual traction or skeletal distractor.

Incision: Include following steps

- Short incision of 3 to 4 cm size is taken centered over medial malleolus.
- Periosteal elevator is inserted and skin tunnel is made well above the fracture site.

Plate selection: Include following steps

- Determine the appropriate length of the plate for fixation.
- In general, a longer plate allows for better mechanical advantage over a shorter plate.

Reduction and provisional fixation: Include following steps

- It is important that fracture reduction be obtained prior to placement of locking screws.
- Temporary secure fracture fragments by using k-wires and/or reduction forceps.
- Place provisional and/or definitive fixation screws outside the plate if necessary.

Plate positioning: Include following steps

- Insert the plate using percutaneous insertion through the distal incision for a minimally invasive procedure.
- Position the plate and reduce the fracture manually.
- Confirm coronal and sagittal alignment as well as plate position on the shaft.
- Fix the plate to the diaphysis with two diaphyseal provisional fixation pins allowing adequate spread between them.
- Place the metaphyseal provisional fixation pin through one of the distal holes above the joint.

Screw insertion: Include following steps

- Proceed with the definitive fixation of fracture using appropriate screw selections.

- If non-locking screw are needed for either fragment, they must be inserted prior the insertion of locking screws in that fragment.
- Locking screws should be used through at least two of distal holes and three proximal holes.

POST-OPERATIVE MANAGEMENT AND FOLLOW-UP EVALUATION

Immediate post-operative radiograph done, limb was kept in above knee plaster slab after surgery in all patients. Patients were reviewed on 2nd and 7th post-operative days for wound inspection. Suture removal was done on 11th post-operative day. Patient was mobilized day after surgery with non-weight bearing crutch walking. Intravenous antibiotics were given for 2 days . After the swelling subsided, immediate ankle joint mobilization was encouraged in all patients as tolerated. Decisions regarding weight bearing were made on individual basis, depending on the progress of bony union, weight of the patient and fracture characteristics. Any post-operative complication had been identified and treated appropriately. After first follow-up visit at 6 weeks, patients were only allowed to bear partial weight with crutches which could then gradually be increased depending on the radiological and clinical findings. Follow ups took place at 6 weeks and 3,5,7,9 and 12 months after surgery with clinical and radiological examination.

V. Result And Analysis

We treated 15 cases by IMIL .Mean age of patients was 41.8 years . Duration of study was 24 months . there was a male predominance . According to AO classification ,11 cases had 43 A1, one case had 43 A2 and three patient had 43 A3 type of fracture. IMIL with fibular plating was done in 12 patients and 3 patients had IMIL alone . In 12 of our cases we plated fibulae to attain alignment and to reduce the pre-operative valgus. In these cases the mean pre operative valgus was 11 °. And the mean post operative valgus was 4.9°. The percentage of valgus corrected was 55.4%. The average time for union is 14.2 weeks. Four of our patients had anterior knee pain, one patient had shortening of 2 cms . There was no incidence of malunion, non union or infection. According to functional scoring of Karlsson and Perterson score nine patients had excellent results, six had good results . We treated 15 cases by MILPO of which eight cases had medial plating and six cases had lateral plating and 1 case had both medial and lateral plating. Mean age of patients was 40.8 years . By AO classifications there were four 43A1 type fractures, one 43A2 fracture, and ten 43A3 . The preoperative valgus 9.31° and the post operative valgus 4.54° and the percentage of valgus correction attained was 51.2%. One patient who had medial plating complained of skin irritation. Another psychiatric patient had a peri-implant fracture on the fifth post operative day. One patient had superficial skin infection. According to functional scoring of Karlsson and Perterson score 10 patients had excellent,5 had good results. There were no fair or poor functional result .Average score was 80 with excellent e no fair or poor functional result .Average score was 80 with excellent functional result . functional result .

VI. Discussion

Both the MILPO and IMIL share the same principle of relative stability and biological osteosynthesis. The intramedullary nailing technique for diaphyseal fractures of the tibia gained popularity for its minimally invasive approach, preservation of the extra-osseous blood supply and ability to restore axial alignment. However, as indications expanded to the distal tibial metaphysis, an increase of malalignment was seen^{5,6,7,8,9,10} . Sarmiento and Latta accepts 8° of valgus with 12mm shortening . In our cases we plated fibula to attain alignment and to reduce the pre operative valgus in 12 cases .In these cases the mean pre operative valgus was 11° and the post operative valgus was 4.9°. The percentage of valgus correction attained was 55.4%.The cause valgus angulation of the distal fragment is due to the biomechanics of fracture. Biomechanically the mass difference between distal tibia and fibula is that when the load goes through both the bones the fibula bears the stress in a less resisted manner and hence the direction of force pushes the distal fragments in to valgus and also the fracture line running proximal- lateral to distal-medial lower tibia has more chances of going for valgus rather than a fracture line running from proximal-medial to distal-lateral, this is due to the better resistance offered by the obliqueness of the larger proximal fragment .

Of 15 cases of nailing we had shortening of 2cms in one patient. Dogra et al¹¹ reported shortening in 20% of the distal tibial fractures stabilised with static intramedullary nailing; this has also been documented by others also^{12,13,14} . In this study in 4 cases we had anterior knee pain but none of the patient had difficulty in kneeling. The occurrence of anterior knee pain is frequently associated with tibial intramedullary nailing with an incidence reported to be between 32% and 57%¹⁵⁻¹⁷ .The most frequent causes of pain were 1) the longitudinal division of the patellar tendon during the trans tendinous approach, 2) the entry point of the nail and the protrusion of the nail proximally. In our cases there was no protrusion of the nail proximally. Tibial nails can migrate towards the tibial plateau and become symptomatic, even if they are locked proximally and distally, most probably because of osteoporosis¹⁸ . Anterior knee pain has also been attributed to weakness of the thigh muscles. Neuromuscular inhibition of quadriceps and gastrocnemius occurs after knee injury, lower-limb

trauma, extensor mechanism injury and reduced weight bearing. Tibial nails should be positioned in a manner which minimises trauma to the extensor mechanism of the knee¹⁹. It has been suggested that pain causes reflex inhibition of quadriceps with subsequent atrophy and/or aplasia²⁰. Injury to the infrapatellar branch of the saphenous nerve can lead to anaesthesia, formation of a neuroma and reflex sympathetic dystrophy^{21,22}. A cadaver study by Tifford et al²³ defined the anatomical distribution of the branches of the saphenous nerve. These run almost perpendicular to the patellar tendon and it is the inferior branch which is more mobile in flexion of the knee^{21,23}. Horizontal incisions decrease the likelihood of nerve transection as the blade is parallel to the nerve.

Though we have not had any non union in our cases, the non union rate in distal tibia is 13% which is attributed to poor vascular supply with minimal soft tissue envelope. In intra-medullary nailing there is disruption of endosteal blood supply This fact is of special significance after reaming for an IM nail, because the combined de-vascularization caused by both fracture and reaming produces a layer of necrotic bone through much of the diaphysis²⁴. The medullary arterial circulation regenerates in a few weeks, since some space exists around a medullary nail. This permits revascularization of the inner cortical bone, which is also supported by recruitment of periosteal collateral circulation if the surrounding soft tissues are healthy enough. However, until revascularization has occurred, the dead cortical bone is not able to participate in the healing process or resist infection.

In present study, we treated 15 cases by MILPO of which 8 cases had medial plating ,6 cases had lateral plating and one case had both medial and lateral plating . Locking compression plating (LCP) provides an angular stability for fixation. Locked screws prevent the plate from pressing the bone, preserving periosteal blood supply. This system stimulates callus formation due to flexible elastic fixation. The anatomic shape of the plate prevents malalignment of the fracture and provides a better axial and angular weight distribution²⁵. The preoperative valgus 9.31° and the postoperative valgus 4.54° and the valgus correction attained was 51.2 % .

Medial MILPO is relative simple. Good clinical outcomes have been reported because of the minimization of soft tissue injury through biological fixation, preserving blood flow and hematoma^{25,26} . In medial plating patients one patients had skin irritation because they are located directly under the skin and the subcutaneous soft tissues which are thin on the medial side of tibia. Moreover in cases with extensive soft tissue injury on the medial side, medial MILPO cannot be performed . At times skin necrosis and plate exposure can occur as complication when a medial plate is inserted^{27,28,29}

Lateral MILPO was introduced to resolve the shortcomings of medial MILPO. Sohn and Kang³⁰ concluded that lateral MILPO is a useful alternative method for achieving high functional recovery with good healing and low incidence of complications for patients with an open distal tibia fracture. The main problem of lateral MILPO is that percutaneous insertion of plates is difficult compared with medial MILPO. Moreover, neurovascular structures can be injured by application of excessive traction during plate insertion, and they can also be injured when the anterolateral approach is used. Wolinsky and Lee³⁰ reported that the superficial personal nerve can be easily identified in the anterolateral approach of the distal tibia because it has a consistent subcutaneous path. However, the risk of deep peroneal nerve and anterior tibial artery injury is high, because both course along the posterior half of the tibial shaft proximally and cross the distal third of the plate. We did not encounter this complication, in any of our cases .In a psychiatric patient, on the fifth post operative day we had a peri-implant fracture as the patient had a fall while mobilization on toe walking which was revised to a long plate. 1 patient had superficial infection on the distal incision site which subsided with antibiotics.

The functional outcome of the cases was analysed by Karlsson and Peterson 100 scoring points. IMIL cases the functional out was excellent in 9 patients, good in 6 patients. The mean score of IMIL was 80 and in MILPO the functional outcome is excellent in ten patients, good in five patients. The mean score is 81.In both techniques the functional outcome was excellent.

VII. Conclusion

Both the MILPO and IMIL share the same principle of relative stability and biological osteosynthesis in distal tibial metaphyseal fractures .The valgus correction attained was 55.4 % by intramedullary nailing with fibular plating technique and 51.2 % by MILPO.In this study in 4 cases we had anterior knee pain but none of the patient had difficulty in kneeling attributed to weakness of the thigh muscles. We had no non union. In MILPO, one patients had skin irritation , peri-implant fracture (psychiatric pt), and 1 superficial infection. Karlsson and Peterson score of IMIL was 79.5 and in MILPO it was 81 .In both techniques the functional outcome was excellent. The need for fibular plating is not there in MILPO .Even though the functional scores are comparable between MILPO and IMIL, the former has fewer complications.

Reference

- [1]. Breasted JH. *The Edwin Smith Surgical Papyrus*. Chicago, IL: Univ Chicago Press; 1980.
- [2]. Court-Brown CM, McBirnie J. The epidemiology of tibial fractures. *J Bone Joint Surg Br*. 1995;77(3):417–421.
- [3]. Grutter R, Cordey J, Buhler M, et al. The epidemiology of diaphyseal fractures of the tibia. *Injury*. 2000;31(Suppl 3):C64–C67.
- [4]. McConnell T, Tornetta P 3rd, Tilzey J, Casey D. Tibial portal placement: the radiographic correlate of the anatomic safe zone. *J Orthop Trauma* 2001;15:207-9.
- [5]. Mosheiff R, Safran O, Segal D, Liebergall M (1999) The unreamed tibial nail in the treatment of distal metaphyseal fractures. *Injury* 30:83–90
- [6]. Tyllianakis M, Megas P, Giannikas D, Lambiris E (2000) Interlocking intramedullary nailing in distal tibial fractures. *Orthopedics* 23:805–808
- [7]. Koval KJ, Clapper MF, Brumback RJ et al (1991) Complications of reamed intramedullary nailing of the tibia. *J Orthop Trauma* 5:184–189
- [8]. Cole JD, Ansel LJ, Schwartzberg R (1995) A sequential protocol for management of severe open tibial fractures. *Clin Orthop Relat Res* 315:84–103
- [9]. Freedman EL, Johnson EE (1995) Radiographic analysis of tibial fracture malalignment following intramedullary nailing. *Clin Orthop Relat Res* 315:25–33
- [10]. Dogra AS, Ruiz AL, Thompson NS, Nolan PC (2000) Diametaphyseal distal tibial fractures – treatment with a shortened intramedullary nail: a review of 15 cases. *Injury* 31:799–804
- [11]. Hamza KN, Dunkerley GE, Murray CM (1971) Fractures of the tibia. A report on fifty patients treated by intramedullary nailing. *J Bone Joint Surg Br* 53:696–700
- [12]. Sedlin ED, Zitner DT (1985) The Lottes nail in the closed treatment of tibia fractures. *Clin Orthop Relat Res* 192:185–192
- [13]. Bone LB, Johnson KD (1986) Treatment of tibial fractures by reaming and intramedullary nailing. *J Bone Joint Surg Am* 68:877–887
- [14]. Young H, Topliss C (2007) Complications associated with the use of a titanium tibial nail. *Injury* 38:223–226
- [15]. Court-Brown CM, Christie J, McQueen MM. Closed intramedullary tibial nailing. Its use in closed and type I open fractures. *J Bone Joint Surg Br*. 1990;72(4):605–611.
- [16]. Keating JF, O'Brien PI, Blachut PA, et al. Reamed interlocking intramedullary nailing of open fractures of the tibia. *Clin Orthop*. 1997;338:182–191.
- [17]. Gaebler C, Berger U, Schandelmaier P, et al. Rates and odds ratios for complications in closed and open tibial fractures treated with unreamed, small diameter tibial nails: a multicenter analysis of 467 cases. *J Object Technol*.2001;15:415–423
- [18]. Skoog A, Soderqvist A, Tornkvist H, Ponzer S. One-year outcome after tibial shaft fractures: results of a prospective fracture registry. *J Orthop Trauma* 2001;15:210-15.
- [19]. Nyland J, Bealle DP, Kaufer H, Johnson DL. Long-term quadriceps femoris functional deficits following intramedullary nailing of isolated tibial fractures. *Int Orthop* 2001;24:342-6.
- [20]. Callaghan MJ, Oldham JA. Quadriceps atrophy: to what extent does it exist in patellofemoral pain syndrome? *Br J Sports Med* 2004;38:295-9.
- [21]. Mochida H, Kikuchi S. Injury to infrapatellar branch of saphenous nerve in arthroscopic knee surgery. *Clin Orthop* 1995;320:88-94.
- [22]. Poehling GG, Pollock EE Jr, Koman LA. Reflex sympathetic dystrophy of the knee after sensory nerve injury. *Arthroscopy* 1988;4:31-5.
- [23]. Tifford CD, Spero L, Luke T, Plancher KD. The relationship of the infrapatellar branches of the saphenous nerve to the arthroscopy portals and incisions for anterior cruciate ligament surgery: an anatomic study. *Am J Sports Med* 2000;28:562-7.
- [24]. 389. Rhinelander, F.W. The vascular response of bone to internal fixation. In: Browner, B.D.; Edwards, C.C.eds. *The Science and Practice of Intramedullary Nailing*. Philadelphia, Lea & Febiger, 1987, pp. 25–29.
- [25]. I. Kempf, K.S.Leung. *Practice of intramedullary locked nails Scientific basis and standard techniques* . Volume 1 Chapter 10 pp87-101
- [26]. Bach AW, Hansen ST Jr. Plates versus external fixation in severe open tibial shaft fractures. A randomized trial. *Clin Orthop Relat Res* 1989; (241):89-94. .
- [27]. Oh CW, Kyung HS, Park IH, Kim PT, Ihn JC. Distal tibia metaphyseal fractures treated by percutaneous plate osteosynthesis. *Clin Orthop Relat Res* 2003; (408):286-91.
- [28]. Redfern DJ, Syed SU, Davies SJ. Fractures of the distal tibia: minimally invasive plate osteosynthesis. *Injury* 2004; 35:615-20
- [29]. Ronga M, Shanmugam C, Longo UG, et al. Minimally invasive osteosynthesis of distal tibial fractures using locking plates. *Orthop Clin N Am*. 2009;40:499–504,
- [30]. Wolinsky P, Lee M. The distal approach for anterolateral plate fixation of the tibia: an anatomic study. *J Orthop Trauma*. 2008;22:404–7.

Dr.M.C.Chinnadurai Ms Ortho. "Comparison of the Functional Outcomes of Distal Tibia Fractures Treated By Minimal Invasive Locking Plating Osteosynthesis or Intra Medullary Inter Locking Nailing." *IOSR Journal of Dental and Medical Sciences (IOSR-JDMS)*, vol. 18, no. 3, 2019, pp 07-14.