

A Comparative Study of Open Vs Laparoscopic Repair in Umbilical and Para Umbilical Hernias

Dr P. Venkata Buddha¹, Dr G.Padmini²

¹ Head of the department, General surgery,

² Post graduate, General surgery Rangaraya Medical College , Kakinada.

Corresponding Author: Dr P. Venkata Buddha

Abstract:

Background: The incidence of umbilical hernias has been reported to be as high as 2% in the adult population and comprises 10% of all hernia repairs performed annually.(1) Umbilical hernias in infants are congenital and are common. It is due to leukocyte adhesion molecule deficiency. They close spontaneously in most cases by the age of 2 years. Those that persist after the age of 5 years are frequently repaired surgically. Umbilical hernias in adults are largely acquired. These hernias are more common in women and in patients with conditions that result in increased intra-abdominal pressure, such as pregnancy, obesity, ascites, or chronic abdominal distension.

Materials and methods: This study was a prospective observational study, conducted on 156 patients during a period of 19 months, including all the patients of umbilical and paraumbilical hernia operated in RANGARAYA MEDICAL COLLEGE , KAKINADA within the study period.

Results: The laparoscopic umbilical / paraumbilical hernia repair is a better alternative to open hernia repair in view of less post-operative pain, surgical site complications, hospital stay and early return to normal activity, preservation of umbilicus, with better cosmetic value even though it requires longer operative time and recurrence rates are almost similar in both the procedures.

Key words: Hernia , laparoscopy, umbilical.

Date of Submission: 25-02-2019

Date of acceptance: 11-03-2019

I. Introduction

The incidence of umbilical hernias has been reported to be as high as 2% in the adult population and comprises 10% of all hernia repairs performed annually.(1)

Umbilical hernias in infants are congenital and are common. It is due to leukocyte adhesion molecule deficiency. They close spontaneously in most cases by the age of 2 years. Those that persist after the age of 5 years are frequently repaired surgically.

Umbilical hernias in adults are largely acquired. These hernias are more common in women and in patients with conditions that result in increased intra-abdominal pressure, such as pregnancy, obesity, ascites, or chronic abdominal distention.

AIMS :

To compare the outcomes of surgical procedure Laparoscopic umbilical and paraumbilical hernia repair and Open umbilical and para umbilical hernia repair.

OBJECTIVES

To assess and compare the outcomes of Laparoscopic umbilical and paraumbilical hernia repair and Open umbilical and paraumbilical hernia repair with reference to

- Duration of surgery
- Length of hospital stay
- Post-operative pain and chronic pain
- Post-operative complications
- Return to normal activity
- Recurrences

II. Methodology

This study was a prospective observational study, conducted from 1st JULY, 2016 to 30th JANUARY, 2018 including all the patients of umbilical and paraumbilical hernia operated in RANGARAYA MEDICAL COLLEGE , KAKINADA within the study period.

INCLUSION CRITERIA:

1. Age >18 years
2. Uncomplicated umbilical and paraumbilical hernia
3. Medically fit for general anesthesia

EXCLUSION CRITERIA:

1. Previous history of upper abdominal surgery
2. Incisional hernia
3. Obstructed hernia / Incarcerated hernia
4. Severe cardiopulmonary disease
5. Presence of local and systemic infection
6. Mentally ill patients / cognitive impairment (Psychiatric disorder, Alzheimer's disease etc).

Out of 156 cases were studied, 72 cases underwent laparoscopic repair and 84 cases underwent open repair.

MANAGEMENT

Because of high risk of strangulation, surgery should be advised in cases where the hernia contains bowel. Small hernia can be left alone if asymptomatic, but they may enlarge and require surgery at later date.

OPEN UMBILICAL AND PARAUMBILICAL HERNIA REPAIR

Very small defect less than 1 cm – SUTURE REPAIR

For larger defects - MESH REPAIR.

The mesh placed in one of the following anatomical plane -

- Within the peritoneal cavity
- In retro muscular space
- In the extra peritoneal space (preperitoneal)
- In the subcutaneous plane –onlay mesh

LAPAROSCOPIC UMBILICAL HERNIA REPAIR

Two types of repair

- Intra Peritoneal Onlay Mesh (IPOM)
- Trans Abdominal Preperitoneal repair (TAPP) - Here Pre peritoneal space was created by incising the peritoneum for fixation of mesh. (Fig. 3,4,5) .This method avoids complication related to mesh like adhesion, obstruction, erosion of mesh into the bowel and infection. (15)

Complications of umbilical hernia repair are:

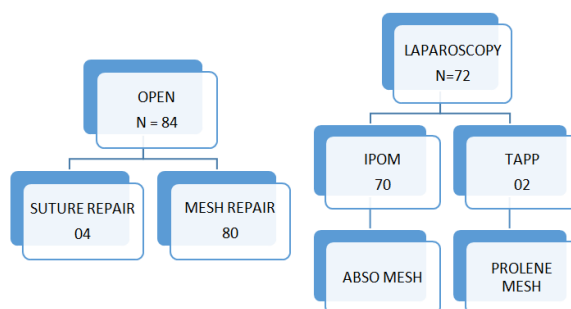
- 1) Seroma / hematoma formation.
- 2) Urinary retention.
- 3) Neuralgias.
- 4) Mesh migration.
- 5) Mesh infection and wound infection.
- 6) Recurrence.

III. Observation And Results

156 patients underwent umbilical hernia repair within the study period of 19months, out of which 72 cases underwent laparoscopic repair and 84 cases underwent open repair of umbilical hernia

Pain was assessed using visual analogue scale

SURGICAL TECHNIQUE :



COMPARISON OF DEMOGRAPHIC VARIABLES :

VARIABLES	LAPAROSCOPY GROUP N=72	OPEN GROUP N=84
GENDER M/F	46 / 26	51 / 33
AGE (MEAN)	46.40	45.70
BMI (MEAN)	29.84	31.35

COMPARISON OF OPERATIVE VARIABLES :

VARIABLES	LAPAROSCOPY GROUP N=72	OPEN GROUP N=84	P-VALUE
OPERATIVE TIME (IN MIN)	90.6	55.1	<0.001
HERNIA SIZE (cm ²)	15.35	16.23	0.998
DEFECT SIZE (cm ²)	9	9.3	0.936
POST OP PAIN SCALE (AT 24hrs)	2.01	2.83	<0.001
POST OP HOSPITAL STAY (IN DAYS)	2.36	3.75	<0.001
RETURN TO NORMAL ACTIVITY (IN WEEKS)	2.78	3.92	<0.001

POST OPERATIVE COMPLICATIONS :

COMPLICATION	LAPAROSCOPIC GROUP (N=72)	OPEN GROUP (N=84)
HEMATOMA	0	3
SEROMA	4	8
EXCISION OF UMBILICUS DONE	0	4
SSI	0	2
FB GRANULOMA	0	2
FLAP NECROSIS	0	4
TOTAL	4 (5.55%)	19 (22.6%)

RECURRENCE :

TYPES OF REPAIR	LAPAROSCOPIC GROUP N=72		OPEN REPAIR GROUP N=84	
	IPOM N=70	TAPP N=2	SUTURE REPAIR N=4	MESH REPAIR N=80
RECURRENCES	0	0	0	0

During the study period no recurrence was seen ,however longer surveillance period is needed.

IV. Discussion

Laparoscopic repair gained wide acceptance and has become the prime modality of choice in recent times especially for surgeons well trained in laparoscopic techniques. Laparoscopic repair of umbilical and paraumbilical hernia is not being practiced regularly, probably because of requirement of superior skills for laparoscopic repair, the higher cost incurred for laparoscopic repair and moreover a small incision required for umbilical open herniorrhaphy is one more reason for its restricted usage.

Laparoscopic onlay patch hernioplasty is a safe and efficacious technique for the repair of umbilical hernia. Compared to Mayo repair the laparoscopic approach confers the advantages of reduced postoperative pain, shorter hospital stay, and a diminished morbidity rate. (3)

Umbilical hernia repair can be carried out safely and securely under local anaesthesia with a tension-free mesh technique (cone or a sublay patch) with a low morbidity, negligible recurrence rate, and a high degree of patient satisfaction. (4)

The preperitoneal laparoscopic technique for umbilical hernia repair combines the advantages of a minimally invasive approach, avoiding the potential complications related to intra abdominal mesh position (5).

A primary suture repair for ventral or incisional hernias has recurrence rates of 25% and 52% for fascial defects smaller and larger than 4 cm, respectively (6,7)

The use of a variety of mesh materials for the repair of these hernias had resulted in a decreased recurrence rate when compare with that in primary suture closure (8) (9).

A prospective randomized trial has recently reported similar results for umbilical hernia repairs, with 11% versus 1% recurrence rates after primary suture and repair with mesh, respectively (10).

The laparoscopic approach has been shown to significantly reduce post operative pain and the risk of bleeding and has been associated with a shorter recovery time (11) (12). Some studies have also proposed a decrease in wound infection rates in laparoscopic approach (13) (14).

The combination of heavily contaminated areas (umbilicus) and with skin folds in obese patients may lead to infection and recurrence (15).

In laparoscopic approach decreased exposure to contaminated umbilicus lessens the chance of wound infection (16). In obese patients, the laparoscopic approach was associated with a significantly lower rate of postoperative infection

LIMITATIONS :

Lack of equipments and lack of expertise are most important causes for its limited use, especially in remote places.

V. Conclusion

The laparoscopic umbilical / paraumbilical hernia repair is a better alternative to open hernia repair in view of less post-operative pain, surgical site complications, hospital stay and early return to normal activity, preservation of umbilicus, with better cosmetic value even though it requires longer operative time and recurrence rates are almost similar in both the procedures.

PHOTOGRAPHS DEPICTING OPERATIVE PROCEDURES :

INTRAPERITONEAL ONLAY MESH REPAIR (IPOM) :

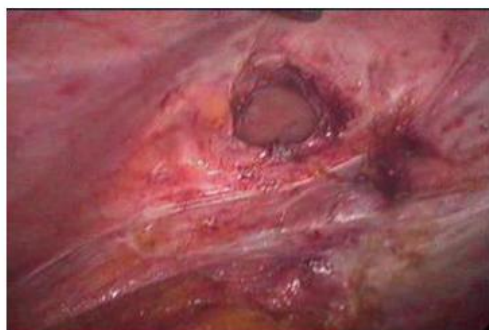

Fig1. Laparoscopic view of para umbilical hernia defect after release of adhesions and reduction of contents

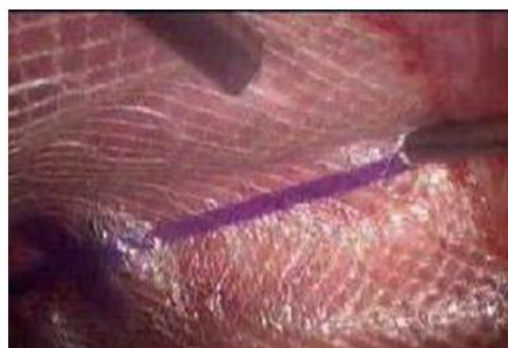

Fig2: ABSOMesh placement and fixation done using tackers

2) Trans Abdominal Pre Peritoneal mesh repair (TAPP) :

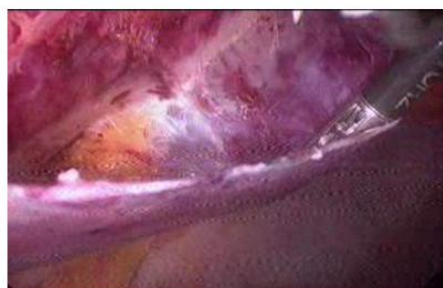


Fig 3: preperitoneal space created laparoscopically

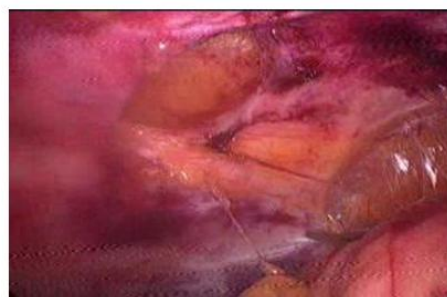


Fig 4: clear defect seen after reducing Contents in pre peritoneal repair

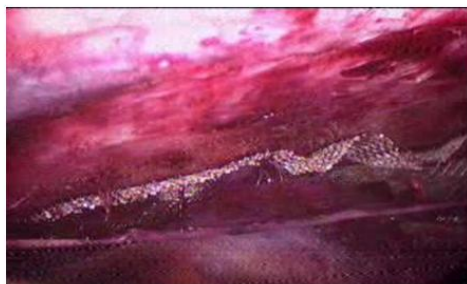

Fig 5: prolene mesh fixed pre peritoneally

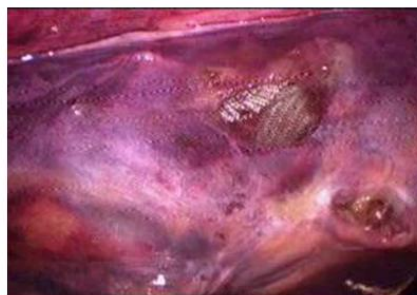


Fig 6: reperitonealisation done using tackers all around

References

- [1]. MJ. Colon, R. Kitamura, D.A. Telem, S. Nguyen, C.M. Divino, "Laparoscopic umbilical hernia repair is the preferred approach in obese patients", *The American Journal of Surgery* (2013) 205, 231-236.
- [2]. Ashu EE, Leroy GM, Aristide BG, et al. Double half-cone flap umbilicoplasty for proboscoid umbilical hernia in a 2 years old child with satisfactory results 2 years later. *Pan Afr Med J.* 2015;22:44. Published 2015 Sep 17. doi:10.11604/pamj.2015.22.44.7818
- [3]. Lau H, Patil NG. Umbilical hernia in adults. *Surg Endosc.* 2003 Dec;17(12):2016–20.
- [4]. Kurzer M, Belsham PA, Kark AE. Tension-free mesh repair of umbilical hernia as a day case using local anaesthesia. *Hernia.* 2004 May;8(2):104–7.
- [5]. Hilling DE, Koppert LB, Keijzer R, Stassen LP, Oei IH. Laparoscopic correction of umbilical hernias using a transabdominal preperitoneal approach: results of a pilot study. *Surg Endosc.* 2009 Aug;23(8):1740–4.
- [6]. Hesselink VJ, Luijendijk RW, de Wilt JH, Heide R, Jeekel J. An evaluation of risk factors in incisional hernia recurrence. *Surg Gynecol Obstet.* 1993 Mar;176(3):228–34.
- [7]. Stoppa RE. The treatment of complicated groin and incisional hernias. *World J Surg.* 1989 Sep-Oct;13(5):545–54.
- [8]. Luijendijk R, Hop W, van der Tol M. A comparison of suture repair with mesh repair for incisional hernia. *N Engl J Med.* 2000;(343): p. 392–398.
- [9]. Morris-Stiff GJ, Hughes LE. The outcomes of nonabsorbable mesh placed within the abdominal cavity: literature review and clinical experience. *J Am Coll Surg.* 1998 Mar;186(3):352–67.
- [10]. Arroyo A, García P, Pérez F, Andreu J, Candela F, Calpeña. Randomized clinical trial comparing suture and mesh repair of umbilical hernia in adults. 2001;(88): p. 1321–1323.
- [11]. McGreevy JM, Goodney PP, Birkmeyer CM, Finlayson SR, Laycock WS, Birkmeyer JD. A prospective study comparing the complication rates between laparoscopic and open ventral hernia repairs. *Surg Endosc.* 2003 Nov;17(11):1778–80.
- [12]. Park A, Birch DW, Lovrics P. Laparoscopic and open incisional hernia repair: a comparison study. *Surgery.* 1998 Oct;124(4):816–21.
- [13]. Brill A, Ghosh K, Gunnarsson C et al. The effects of laparoscopic cholecystectomy, hysterectomy, and appendectomy on nosocomial infection risks. *Surg Endosc.* 2008;(22): p. 1112–8.
- [14]. Hwang C, Alfrey E, Wichterman K. Laparoscopic ventral hernia repair is safer than open repair: analysis of the NSQIP data. *J Surg Res.* 2009;(156): p. :213–6.
- [15]. Breuing K, Butler CE, Ferzoco S, Franz M, Hultman CS, Kilbridge JF et al.; Ventral Hernia Working Group. Incisional ventral hernias: review of the literature and recommendations regarding the grading and technique of repair. *Surgery.* 2010 Sep;148(3):544–58.
- [16]. Modesto J, Colon MD, Riley Kitamura BS, Dana A. M.D T. Laparoscopic umbilical hernia repair is the preferred approach in obese patients. *Am J Surg.* 2013;(205):231–6.

Dr P. Venkata Buddha. "A Comparative Study of Open Vs Laparoscopic Repair in Umbilical and Para Umbilical Hernias." *OSR Journal of Dental and Medical Sciences (IOSR-JDMS)*, vol. 18, no. 3, 2019, pp 32-36.