

Temporary Anchorage Devices- An Update

Dr. Shabdika Baghel¹, Dr. Ashish Garg², Dr. Samprita Sahu³, Dr. Neha Verma⁴,
Dr. Amit Singh Choudhary⁵, Dr. Swadhin Raghuwanshi⁶

¹Department of Orthodontics & Dentofacial Orthopedics, Sri Aurobindo College of Dentistry, Indore, India.

²Department of Orthodontics & Dentofacial Orthopedics, Sri Aurobindo College of Dentistry, Indore, India.

³Department of Orthodontics & Dentofacial Orthopedics, Sri Aurobindo College of Dentistry, Indore, India.

⁴Department of Orthodontics & Dentofacial Orthopedics, Sri Aurobindo College of Dentistry, Indore, India.

⁵Department of Orthodontics & Dentofacial Orthopedics, Sri Aurobindo College of Dentistry, Indore, India.

⁶Department of Endodontics & Conservative Dentistry, Sri Aurobindo College of Dentistry, Indore, India.

Corresponding Author: Dr. Shabdika Baghel

Date of Submission: 25-02-2019

Date of acceptance: 11-03-2019

I. Introduction

A temporary anchorage device (TAD) is a device that is provisionally secured to the bone with the motive of increasing the anchorage in orthodontic treatment either by supporting the teeth of the reactive unit or by eliminating the need for the reactive unit entirely, and can be easily detached after use. The location of implant can be endosteally, transosteally, or subperiosteally and can be secured to bone either biochemically i.e. osseointegrated or mechanically i.e. cortically stabilized.

II. History

In 1969 *Branemark et al*¹ observed a firm anchorage of titanium to bone with no adverse tissue response. The use of TADs was first reported in 1983 when *Creekmore and Eklund*² used a Vitallium® bone screw for treatment of deep overbite in a patient. *Costa and colleagues*³ in 1999, developed a 6 mm long and 1.2 mm diameter titanium implant with a head that resembles a bracket, for early loading called the "Aarhus Anchorage system®". *Sugawara and Umemori*⁴, introduced the Skeletal Anchorage System (SAS) in 1999 for anchorage in orthodontic treatment by employing titanium miniplates and monocortical screws which are temporarily secured in the maxilla/mandible for absolute anchorage.

In 2001 *Lee, Park and Kyung*⁵ first treated a case in which micro screw was used for lingual orthodontic treatment. In 2006, *Poggio and colleagues*⁶ concluded that miniscrews with a diameter of 1.5 mm or less are safe for inter-radicular insertion if the inter-radicular space is at least 3.5mm. In 2013, *Patrey*⁷ concluded that increased insertion depth increases retention. Placement at 90° to the cortical plate is the indicated insertion angle. He also told that insertion at an oblique angle from the line of force reduces retention.

III. Description Of Miniscrew

Screw has three principal components: a core, a helix (called the thread), and a head (Fig 1)^{8,9}. The head of TAD screw basically has two functions: to provide a means for applying twisting torque to the core and thread and to serve as an application point for force. The core, which is the support of the screw, is attached to the head and is wrapped in the helical thread. The incidence of screw failure during insertion of the screw can be lowered by using screw of greater core diameter. The *shank* is the part of the screw that extends from the head to the beginning of the threads.

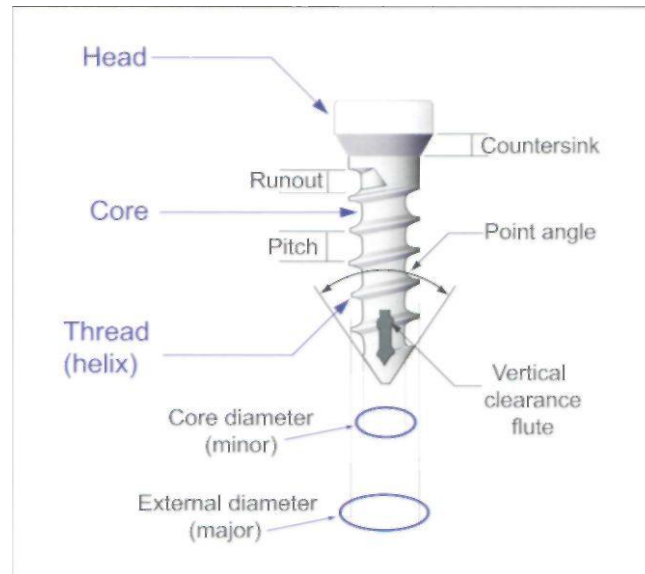


Fig. 1 Basic component of screw

CLASSIFICATION OF TEMPORARY ANCHORAGE DEVICES

A) Based on clinical applications and design²:

- I. Subperiosteal Palatal Onplants
- II. Temporary Palatal Endosseous implants.
- III. Bone plates.
- IV. Bone screws.

B) Based on the head type:

- I. Head with a hole in the neck.
- II. Head with button like design.
- III. Head with bracket like design.
- IV. Head with a hook.

C) Dr. J. B. Cope proposed classifying orthodontic TADs into two groups:

- I. Biocompatible TADs
- II. Biological TADs

D) According to Configuration:

- I. Root Form Implants.
- II. Press Fit.
- III. Self-drilling.
- IV. Pre-tapping.
- V. Blade / Plate Form Implants.
- VI. Pre-Fabricated.

E) According to composition:

- I. Stainless Steel.
- II. Cobalt- Chromium-Molybdenum
- III. Titanium
- IV. Ceramic Implants
- V. Miscellaneous such as Vitreous Carbon and Composites

F) According to surface structure:

- I. Threaded or Non-threaded
- II. Porous or Non-Porous

APPLICATION

In orthodontic treatment, anchorage control is essential for success. Dental implants, due to the stability in bone, can serve as firm static anchorage. TADs are indicated in the following clinical situations:-

- Patients with insufficient teeth for application of conventional anchorage (Fig 2)

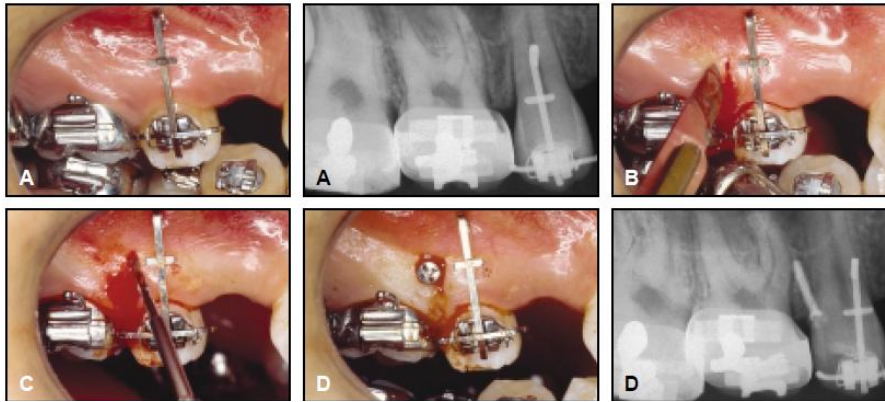
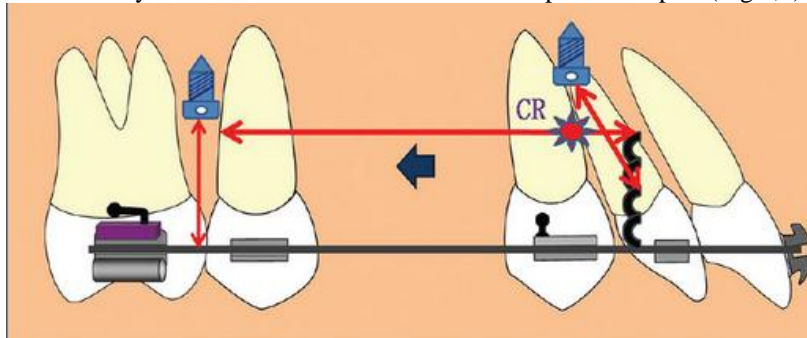


Fig. 2 Micro screw implant placement for conventional anchorage¹⁰

- Patient in whom forces to the reactive unit would generate adverse effects
- Patients with a need for asymmetric tooth movement in all three planes of space (Fig 3,4)



□ □ **Fig. 3 No moments or intrusive, extrusive components of force are generated by the retraction force. So for full arch intrusion, active intrusion force needs to be applied both from the anterior labial and posterior buccal micro-implants.¹¹**

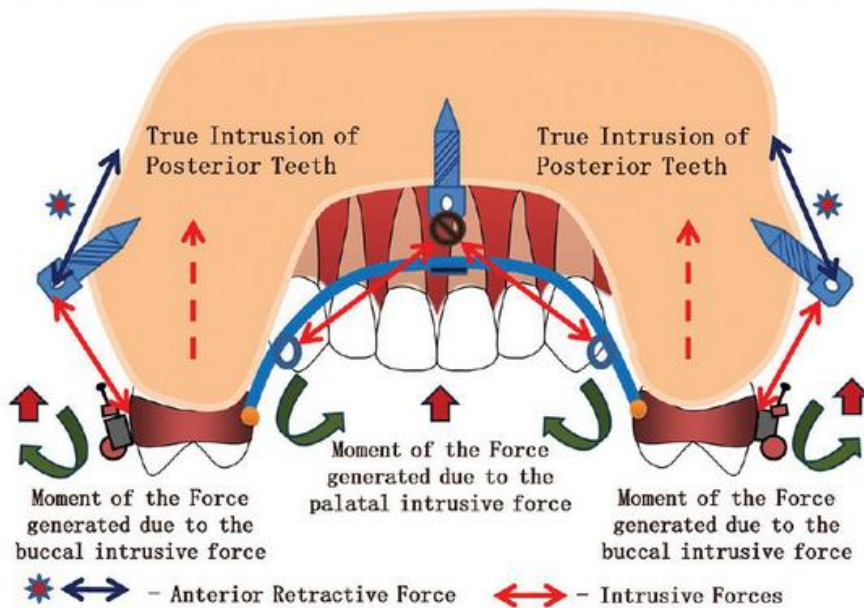


Fig. 4 Movements of teeth in vertical, sagittal, transverse direction¹¹

- In selected patients, as an alternative to Orthognathic surgery (Fig 5,6,7)

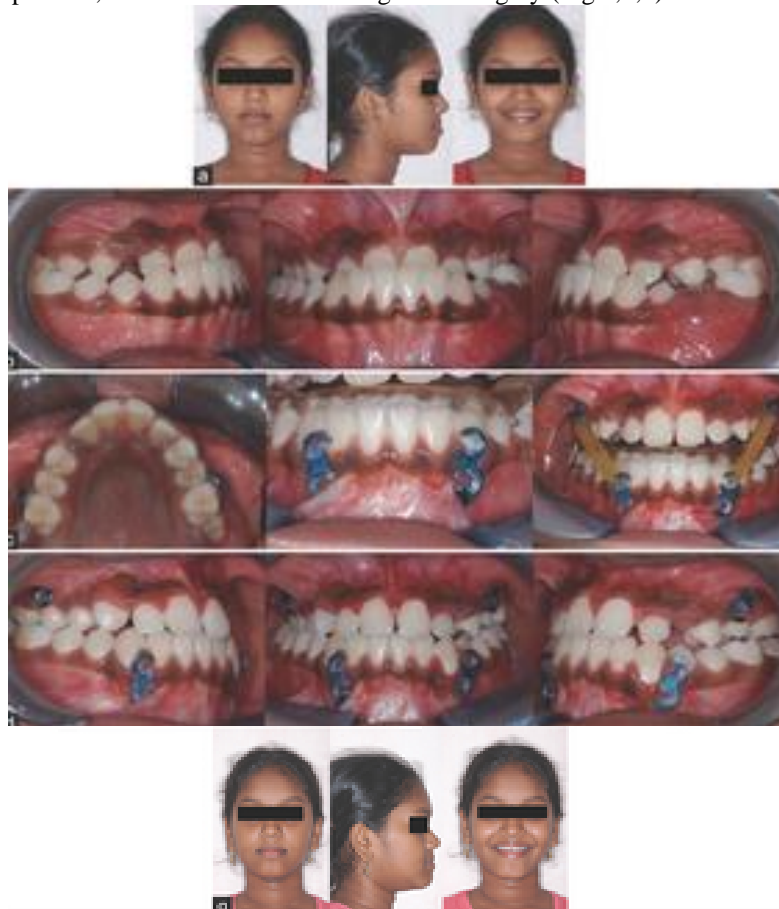

Fig. 5A 19 year old female patient, presented with skeletal and dental class III malocclusion indicated for BSSO treated with application of TAD.¹²

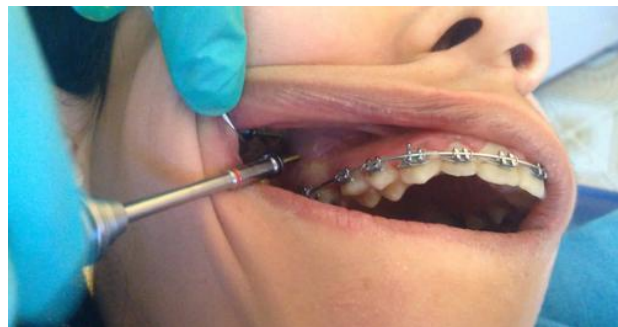

Fig. 6 Placement of Infrazygomatic crest screw at infrazygomatic area for the purpose of maxillary arch retraction or intrusion

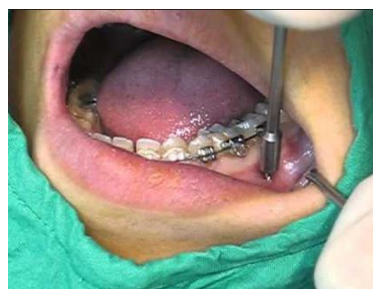

Fig. 7 Placement of buccal shelf screw implant which is an extra-alveolar site for implant placement in mandible, indicated for mesialization or intrusion of mandibular arch.

- Treatment of anterior open bite with molar intrusion (with or without extractions) (Fig 8)

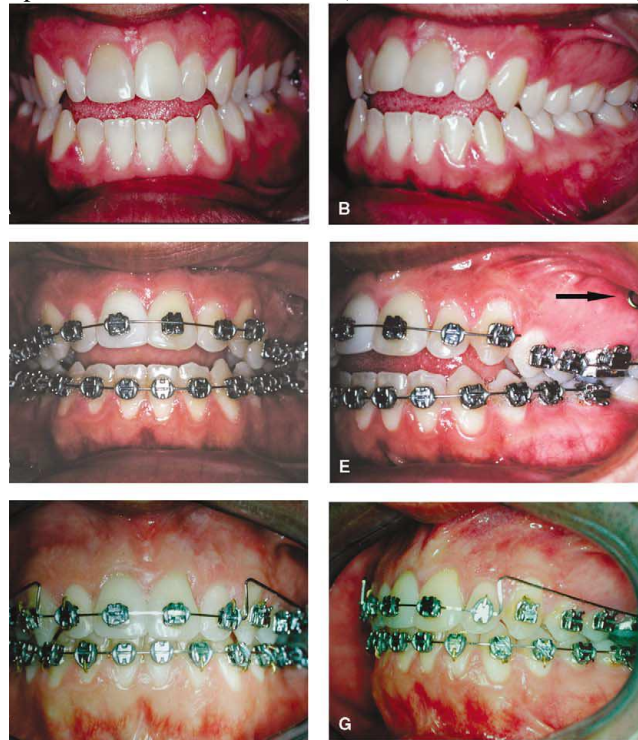


Fig. 8 Placement of mini implant for molar intrusion¹³

- Treatment of anterior deep bite with incisal intrusion (with or without extractions) (Fig 9)

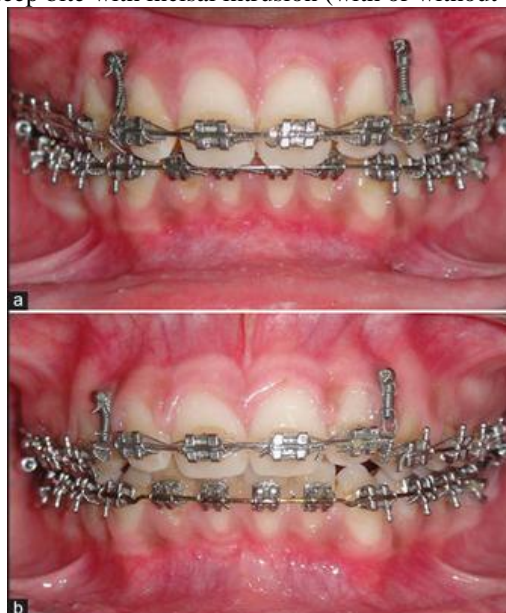


Fig. 9 Placement of microimplant for incisal intrusion

- Molar up righting by distalization of crown or by mesialization of roots (Fig 10)

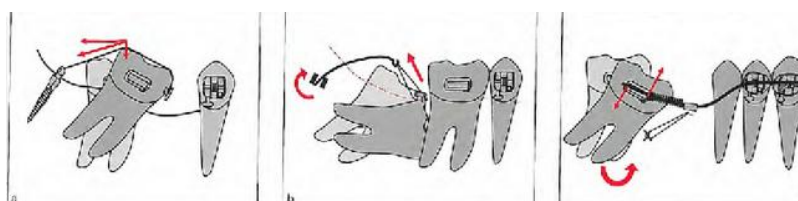


Fig. 10 Application of microimplant for molar up righting by (a) crown distalisation of mesioangular

molar (b) crown distalisation of horizontal molar (c) root mesialization¹⁵

- Leveling of canting of plane of occlusion (Fig 11)

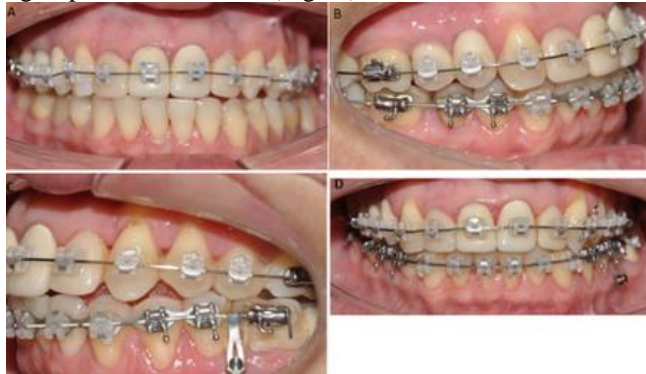

Fig. 11 Correcting the canting of occlusal plane with the help of implant in lower arch¹⁶

- Closure of Spaces (Extraction / Non extraction) (Fig 12)

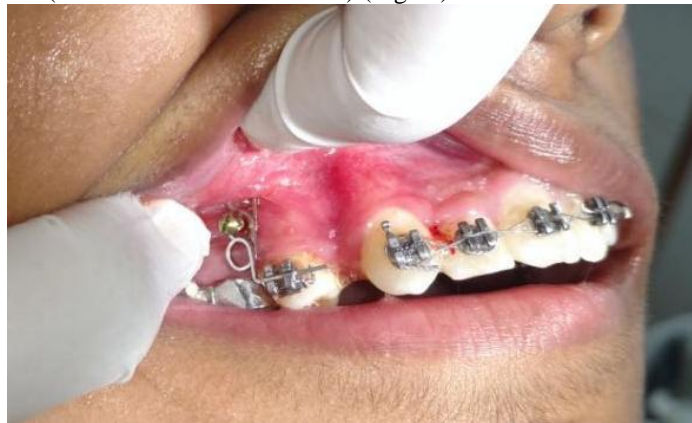

Fig. 12 Premolar extraction space closure by implant placed between second premolar and molar

- Molar Distalization (Fig 13)

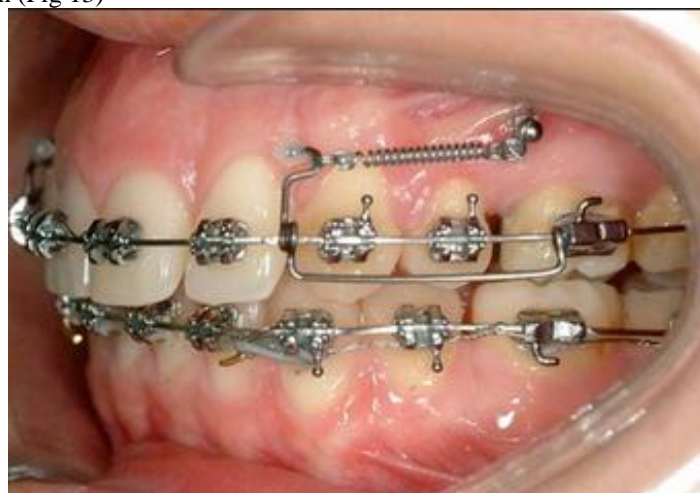

Fig. 13 Upper first molar distalisation with the help of implant placed between premolar and molar

- Midline correction
- Enforced eruption of intruded teeth (Fig 14)

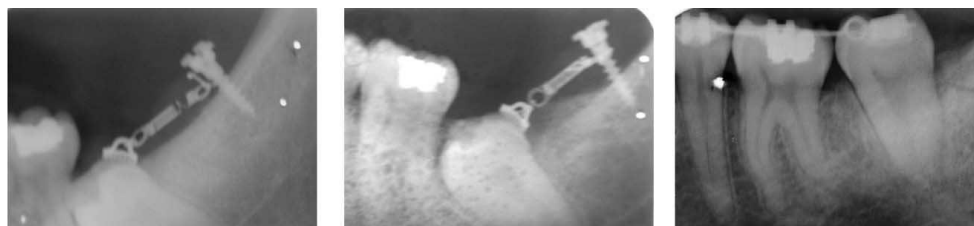

Fig. 14 Enforced eruption of mandibular second molar with the help of implant at retromolar area

IMPLANT SITE

Maxillary implant sites: (Fig 15, 16)

- Paramedian or mid-sagittal region of the hard palate
- Zygomatic buttress of the maxilla
- Area below the anterior nasal spine
- Maxillary tuberosity
- Edentulous alveolar ridges
- Interradicular spaces, both buccal and lingual

Mandibular implant sites: (Fig 15, 16)

- Retromolar area
- Symphysis or parasymphysis area
- Buccal cortical (shelf) area
- Edentulous alveolar ridges
- Interradicular spaces, both buccal and lingual.

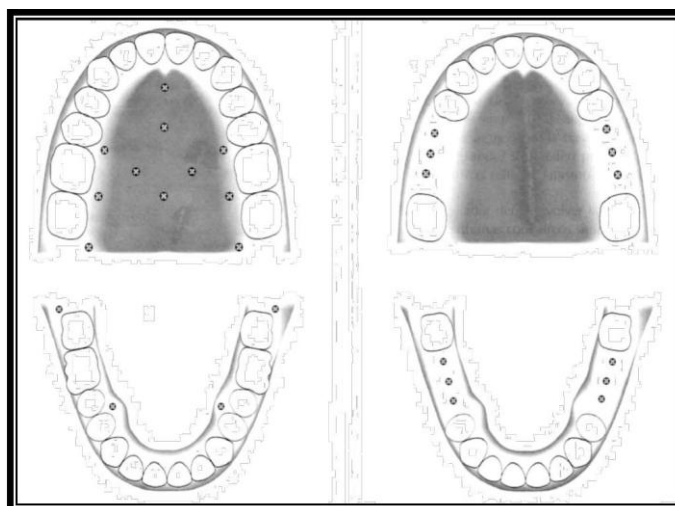


Fig. 15 Miniscrew implantation sites in Upper palatal & alveolar and Lower lingual & alveolar region

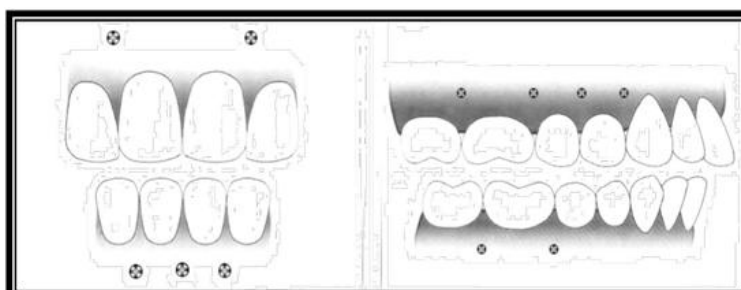


Fig. 16 Miniscrew implantation sites in maxillary and mandibular labial and buccal zones

SAFETY DISTANCE

Huang and Shotwell^{19,20} gave theory of a safety distance which provides a rule for minimum distance between the roots where implant placement is planned.

Safety Distance = Diameter of the implant
 + PDL space (normal range: 0.25 mm + 50%)
 + (minimum distance between implant and tooth, i.e 1.5 mm) x 2
 OR
 $1.2 + .375 + (1.5) \times 2 = 4.575 \text{ mm}$

Later **Gautam and Valiathan**²¹ proposed that the PDL space should be multiplied by a factor of 2 to consider PDL space of 2 teeth, i.e. the teeth on either side of the implant. Hence:

Safety Distance = Diameter of the implant
 + 2 x PDL space (normal range: 0.25 mm + 50%)
 + (minimum distance between implant and tooth, i.e 1.5 mm) x 2.

PLACEMENT PROTOCOL

Length of the mini screw implant:

Table 1 : Insertion Sites and most commonly used mini screw implant dimensions

Size (Diameter x Length, mm)	Indication
1.6 X 6	<ul style="list-style-type: none"> • Labial and buccal inter- radicular space where the mucosa is not thick. • Mid- palatal area
1.6 X 8	<ul style="list-style-type: none"> • Most palatal interradicular space
1.6 X 10	<ul style="list-style-type: none"> • Interradicular space on palatal side where the thickness of mucosa is more.

Diameter of the microimplant:

1.2mm/1.3mm diameter MI can endure up to 450g of force when patient has good quality of cortical bone. However maximum of the orthodontic forces ever needed intraorally is often less than 300g. When using forces greater than 300g, clinicians should select 1.4 mm/1.5 mm/1.6mm diameter.

Placement Procedure for self-tapping Micro-screw:

- Dentist should take all the measures to carry out infection control. The implant location should be washed with 0.2% Chlorhexidine.
- Drill a pilot hole with a 1.0mm, 1.5mm or 2.0mm spiral drill; provisional to the screw diameter.
- Keep the drill speed to 500-800 rpm under thorough irrigation with normal saline to avoid over-heating and bone necrosis.
- Drill the pilot hole inside the cortical bone to guide the initial path of insertion of implant. Drill length should be equal to the implant length for good mechanical retention.
- Insert the ‘non-drilling mini-implant’ using short or long screwdriver.
- Leave the head and platform of the bone screw outside the attached gingival or alveolar mucosa.
- For sites in the alveolar mucosa, irrigate the wound thoroughly with normal saline before suturing.
- Prescribe antibiotics for a week to prevent post-operative inflammation and of 2% Chlorhexidine to conserve good oral hygiene.
- If the implant location is in the alveolar mucosa, allow a remedial duration of two weeks before orthodontic loading to avoid any post-operative infection.
- If the implant location is in the attached gingiva, forces can be loaded immediately.

Placement procedure for Self – Drilling Mini-screw

- Dentist should take all the measures to keep the operating area free of infection. The implant location should be washed with 0.2% Chlorhexidine.
- The correct size of screw is selected and inserted, meanwhile the assistant keeps the lips apart and the mucosa tight.
- If the screw is inserted with a low-speed drill, due to lack of tactual sensation a root may not be detected.
- When cortex is thicker than 2 mm, pilot drilling may be required when using self-drilling screws, as dense bone can twist the fine screw tip.

REMOVAL PROTOCOL

After orthodontic therapy, because complete osseointegration does not occur between the micro implant used for orthodontic anchorage and the bone, implant removal post-treatment is simple. Without local anesthesia, screw can be removed easily by engaging the screw head with the driver and turning into the direction opposite to that of insertion.

DISADVANTAGES

1. Abnormal bone conditions adversely affect the firmness of implants.
2. In case of fracture, additional surgical procedures may be needed, or the broken tip may be left in the mouth; this decision is determined by specific conditions.
3. Rarely roots of the adjacent teeth can be injured during engagement of orthodontic implants.
4. Although rarely, nerve injury is possible, theoretically.
5. Due to poor oral hygiene around the implant inflammation, infection, and gingival overgrowth may occur.
6. Oral ulceration can result from the stress of surgery or mechanical irritation.

CONTRAINDICATIONS

- ✓ Recent myocardial infarction.
- ✓ Valvular prosthesis.
- ✓ Severe renal disorder.
- ✓ Treatment - resistant diabetics
- ✓ Generalized secondary osteoporosis.
- ✓ Chronic or severe alcoholism.
- ✓ Treatment-resistant osteomalacia.
- ✓ Radiotherapy in progress.
- ✓ Severe hormone deficiency.
- ✓ Drug addiction.
- ✓ Heavy smoking i.e. more than 20 cigarettes per day.

LOCAL CONTRAINDICATIONS

- ✓ Defect in bony tissue at local site
- ✓ Mixed dentition period where placement of the miniscrews may damage developing and erupting permanent teeth
- ✓ Mid-palatal region of growing patient
- ✓ Soft tissue lesions such as lichen planus, leucoplakia, etc.
- ✓ Presence of pathology like tumors or cysts
- ✓ Presence of active oral infections
- ✓ Deficient space for insertion of microimplant
- ✓ Thin cortical bone and insufficient retention
- ✓ Poor quality of the bone
- ✓ Rampant Periodontal disease

LIMITATIONS

- The implant itself can provide ideal orthodontic anchorage but cannot provide the ideal force system for tooth movement. Rigid anchorage is not the only factor in successful treatment; teeth should be controlled three dimensionally with the assistance of rigid anchorage¹³.
- The positioning of the orthodontic mini-implant is relatively unrestricted compared to that of other bone-supported anchorage systems. E.g. Interdental implants may obstruct with the mesiodistal movement of adjacent teeth¹³.
- An intrusive force vector from implants may cause side effects that would not occurred with conventional mechanics, and unwanted intrusion is a possibility¹³.
- Mini-implants are capable of applying orthopaedic treatment in two ways. The first is direct application of orthopaedic force to implants; the second is splinting of teeth by indirect application to minimize tooth movement, a side effect of orthopaedic treatment. However, studies for long-term stability are also required¹⁴.

IV. Conclusion

Miniscrew implants offer an option for high anchorage orthodontic treatment that is relatively inexpensive, easily implemented, and predictable enough to be used easily in practice. Because of the low level of invasiveness and the small likelihood of side effects, the risk-benefit ratio is generally in favor of using miniscrews, not only for more complicated malocclusions, but in most patients,. However, the simplicity of the insertion and the low risk of the procedure might be a temptation for overuse of these little screws.

References

- [1]. Branemark PI, Breine U, Adell R, et al: Intra-osseous anchorage of dental prostheses: I. Experimental studies. *Scand J PlastReconstrSurg*.1969;3:81-100.
- [2]. Creekmore TD, Eklund MK. The possibility of skeletal anchorage. *J Clin Orthod* 1983; 17:266-9.
- [3]. Costa A.; Raffling M.; Millstone B.: Miniscrews as orthodontic anchorage: A preliminary report. *Int J Adult Orthod Orthog Surg* 1998; 13: 201-209
- [4]. Sugawara J: JCO interviews DrJunji Sugawara on the skeletal anchorage system. *Clin Orthod* 33:689-696, 2000.
- [5]. Lee JS, Park HS and Kyung HM. Microimplant anchorage for lingual treatment of skeletal class-II malocclusion. *J Clin Orthod* 2001;35:643-647.
- [6]. Poggio PM, Incorvati C, Velo S, Carano A. “Safe Zones”: A Guide for Miniscrew Positioning in the Maxillary and Mandibular Arch. *Angle Orthod* 2006;76:191–197.
- [7]. Petrey JS; Marnie M. Saunders G. Klumper T. Temporary anchorage device insertion variables: effects on retention. *Angle Orthod* 2013;80:634–641.
- [8]. Maïke Holma; Paul-Georg Jost-Brinkmann; James Mahc; Axel Bumann Bone thickness of the anterior palate for orthodontic miniscrews *Angle Orthod*. 2016;86:826–831.
- [9]. Raed H. Alrbataa; Moath Q. Momanib; Ahmad M. Al-Tarawnehc; Ayman Ihyasat Optimal force magnitude loaded to orthodontic microimplants: A finite element analysis *Angle Orthod*. 2016;86:221–226.
- [10]. Seong-Min Bae, Hyo-Sang Park, Hee-Moon Kyung, Oh-Won Kwon, Jae-Hyun Sung;Clinical Application of Micro-Implant Anchorage: *Journal of Clinical Orthodontics* May 2002; Vol XXXVI no. 5:298-302.
- [11]. Ghosh A. TAD – transpalatal arch-MOD combination system: An effective tool in the nonsurgical management of individual with vertical facial patterns and gummy smiles. *J Indian Orthod Soc* 2017;51:110-8.
- [12]. Krishnaswamy NR. Contemporary solutions for managing Class III malocclusion. *J Indian Orthod Soc* 2015;49, Suppl S1:19-26.
- [13]. Keith H. Sherwood, James G. Burch, and William J. Thompson; Closing anterior open bites by intruding molars with titanium miniplate anchorage; *Am J Orthod Dentofacial Orthop* December 2002; Vol112, 6; 593-600.
- [14]. Gupta N, Tripathi T, Rai P, Kanase A, Neha. A comparative evaluation of bite opening by temporary anchorage devices and Connecticut intrusion arch: An *in vivo* study. *Int J Orthod Rehabil* 2017;8:129-35
- [15]. *Biomechanics in Orthodontics*.
- [16]. Diego Lopez, Joaquin Benjumea (2017). Alveolar Growth Stimulated by Periodontally Accelerated Osteogenic Orthodontics.
- [17]. Miniscrews and biomechanics in orthodontics; Chapter 2.
- [18]. Wu JC, Huang, J.N. et al. Radiographic and surgical template for placement of orthodontic microimplants in interradicular areas: a technical note. *Int J Oral Maxillofac Implants*. 2006;21:629–634.
- [19]. Huang LH, Shotwell JL, Wang HL. Dental Implants for Orthodontic Anchorage. *Am J Orthod Dentofacial Orthop* 2005; 127:713-22)
- [20]. Gautam P, Valiathan A. Implants for anchorage. *Am J Orthod Dentofacial Orthop* 2006;129(2):174.
- [21]. Itsuki Y, Imamura E, Sugawara J; Temporary anchorage device with interchangeable superstructure for mandibular tooth movement.*Journal World Federation of Orthodontists* 2013;2(1):19-29.

Dr. Shabdika Baghel. “Temporary Anchorage Devices- An Update.” *OSR Journal of Dental and Medical Sciences (IOSR-JDMS)*, vol. 18, no. 3, 2019, pp 37-46.