

Somatic and Biological aspects in Turner Syndrome - Case Report

Smaranda Adelina Preda¹, Melania Cojocaru², Mihaela Popescu³,
Dana Maria Albulescu⁴, Ioana Adina Cotoi⁵, Anca Mihaela Predescu⁶,
Mihaela Jana Tuculina⁷

¹(PhD student, University of Medicine and Pharmacy, Faculty of Dentistry, Craiova, Romania)

²(Lecturer, Department of Odontolog, Faculty of Dentistry, University of Medicine and Pharmacy, Craiova, Romania)

³(Lecturer, Department of Endocrinology, University of Medicine and Pharmacy, Craiova, Romania)

⁴(Associate Professor, Department of Anatomy, University of Medicine and Pharmacy of Craiova, Romania)

⁵(PhD student, University of Medicine and Pharmacy, Faculty of Medicine, Craiova, Romania)

⁶(Lecturer, Research Center for Microscopic Morphology and Immunology, University of Medicine and Pharmacy of Craiova, Romania)

⁷(Professor, Department of Odontology, Faculty of Dentistry, University of Medicine and Pharmacy, Craiova, Romania)

Corresponding Author: Adina Ioana Cotoi

Abstract: The alteration of the gonadogenesis process or morphological dysgeusia has multiple repercussions: the distortion of the hormonal biosynthesis process, the disruption of the reactivity structures of the gonadal hormones and the clinical aspect is highlighted by the disorder of the sexualization process. Turner syndrome (TS) is a rare disorder that affects female subjects. I studied a case of the Turner syndrome, followed over a 24-month period and found a significant improvement in waist as a result of establishing growth hormone therapy. Craniofacial aspects are the major interest for orthodontist.

Key words: cephalometry, cephalometric measurements, oro-dental changes, Turner syndrome

Date of Submission: 27-02-2019

Date of acceptance: 14-03-2019

I. Introduction

Sex development starts in intrauterine life caring on adolescence and finalizing at young adults through sexual maturity or reproductive capacity. Sex development can be divided into three main stages: chromosomal sex, gonadal sex (sex determination) and phenotypic (gender differentiation). The alteration of the gonadogenesis process or morphological dysgeusia has multiple repercussions: the distortion of the hormonal biosynthesis process, the disruption of the reactivity structures of the gonadal hormones and the clinical aspect is highlighted by the disorder of the sexualization process. Turner syndrome (TS) is a rare disorder that affects female subjects with incidence from 1/2500 to 1/3000 female newborns. It was described in 1938 by Turner. The initial description by Henry Turner in 1938 included short stature, sexual infantilism, cubitus valgus and pterygium coli¹.

It is the consequence of numerical gonosomal distortion

- the loss of the entire chromosome X (karyotype 45, XO) 57% of the cases;
- abnormal structure of chromosome X-46, X, (Xq), 46, XX, del (Xq), 46, XX, del (Xp), 46, X, r (X) 14% cases;
- mosaicism in 29% of cases².
- The male phenotype, regardless karyotype, is excluded from this diagnosis

In X monosomy (45 × 0), chromosome X has maternal origin in 68% from 80% of females and paternal origin in 20% from 32%².

Women with monosomy X have the most severe phenotype while associated forms with X have autoimmune disorders manifested through isochromosom. The Turner phenotype is variable according to the responsible change³.

One can discuss a correlation between phenotype and genotype in Turner's syndrome^{4,5,6}.

A cause of reduced stature is the haploinsufficiency of the SHOX gene system from X chromosome level⁷.

The loss of short arm Xp is responsible for the TS phenotype characterized by reduced stature and typical skeletal alterations. The loss of the long arm Xq may cause stomach hypotrophy and ovarian failure. Deletions

of 22.3 Xp may be associated with deficits and cognitive loss, and deletions of 11.4 Xp have been suggested to be responsible for lymphedema ^{8,9}.

Female patients with Turner syndrome have stature hypotrophy, delayed puberty / ovarian failure, cardiac and renal abnormalities, hearing impairment, ophthalmic, thyroid disorders, metabolic syndrome, gastrointestinal and cognitive disorders ¹⁰.

Somatic abnormalities include: face and neck - palpebral ptosis, antimongoloid snout, the corners of the mouth are downwards ("fish mouth"), deep, ogival palate, micrognatism, lower implanted ears, short palmar neck, pterigium coli; thorax -with the "shield" aspect, hypoplastic and distant nipples; extremities - shortening IV, V metacarpal bones and metatarsal bones IV, V, cubitus valgus, knee abnormalities, nail hypoplasia. Visceral abnormalities include: cortex - aortic coarctation as well as various left heart malformations, kidney as horseshoe. Internal and external genital organs are hypoplastic, amenorrhea is primary, and prepubertary growth does not occur. In 5% to 20% of cases with Turner syndrome - some mosaicism - spontaneous puberty is followed by normal, irregular or secondary amenorrhea ¹¹.

Bone age is generally delayed compared to chronologically age, the progression is slow as a result of inappropriate sexual hormone production. Most ST patients require induction of puberty as well as estrogen / progesterone replacement therapy. Preliminary analysis of gonadotrophins is required to exclude spontaneous but late puberty. Estrogenic deficiency can induce accelerated and irreversible decrease in bone mass, especially trabecular, endothelial dysfunction, decrease insulin synthesis, central adiposity development ¹².

Initiation of estrogen therapy has positive effects on liver enzymatic abnormalities and also improves the cognitive deficits (reaction time, short-term memory non-verbal disability) ¹³.

Turner syndrome is associated with an increased incidence of autoimmune disorders - especially thyroid and metabolic disorders ^{14,15,16,17}.

Craniofacial development is delayed with 2-3 years while dental development is early (6 months - 3.5 years). Typical modifications in facial skeleton are: reduced development of the cranial base, hypertelorism, maxillary hypoplasia, micrognathia, high palate, bilateral crossing with or without palatoschisis, open bite, class II of malocclusion. The best practice management in ST is developed by the guide written by the Association of Patients with Turner Syndrome. These more recent guidelines specifically addresses to screening diagnostic and comorbidity management in Turner syndrome ¹⁸.

II. Case Presentation

We present the case of a 11 years and 7 month old patient diagnosed with Turner syndrome. During September 2016, the karyotype was performed - using the Leica CW4000 Karyo program, 15 GTG bandages were studied and 5 metaphases were karyotyped. In all studied metaphases, chromosomal aneuploidy was observed by the absence of one of the X chromosomes. No modifications in the structure of the detectable chromosomes by the G-banding technique. The conclusion was Turner syndrome - karyotype 45, XO.

Growth hormone replacement therapy has been initiated demonstrating a good therapeutic tolerance as well as a good recovery of stature deficiency (table no 1).

Table no1 Evaluation of anthropometric indices and dynamic development - under permanent therapy with hormone substitution

Year	Cronological age	Waist	Weight	Standard deviations	Average genetic weight
2016	9years,3months	120,6cm	27,6 Kg	-2,68 DS	162 cm
2017	10years,6 months	128,4 cm	30 kg	-2,1 DS	-
2018	11years,6 months	134 cm	39,5 kg	-1,95 DS	-

From a biological point of view, the same evolution of the monitored parameters it is noted on the 24-month period (table no 2, table no 3)

Table no 2 Biological profile - positive evolution under thyroid and growth hormone substitution therapy

Year	TSH	FT4	IGF1	25-OH D Vitamin
2016	6,26microUI/mL	17,4pmol/l	193,3ng/ml	20,1ng/ml
10.2017	3,651microUI/mL	15,96pmol/l	202,9ng/ml	23,5ng/ml
10.2018	5,25 microUI/mL	14,40pmol/l	361,8ng/ml	40,7ng/ml
Normal values	0,5-4,5 microUI/mL	9-19pmol/l	76-549ng/ml	30-100ng/ml

Table no 3 Chemical profile - positive evolution under thyroid and growth hormone substitution therapy

Year	Triglycerides	Cholesterol	Total Ca serum	Magnesium	Phosphorus	Alkaline Phosphatase
2016	58mg/dL	175mg/dL	8,2mg/dL	1,91mg/dL	4,99mg/dL	229U/L
2017	60mg/dL	165mg/dL	8,3mg/dL	1,8mg/dL	5,03mg/dL	232U/L
2018	55mg/dL	160mg/dL	8,8mg/dL	1,9mg/dL	4,89mg/dL	149U/L
Normal values	50-200mg/dL	0-170mg/dL	8,4-10,3mg/dL	1,6-2,23mg/dL	3,56- 5mg/dL	0-300U/L

Exo and endooral examination was performed and the cephalic extremity was inclined to the left, facial asymmetry, mandibular and maxillary retrograde. It performed RX-OPT without showing signs of resorption of the teeth roots, class II of malocclusion, mandible median line deviated 4 mm to the left (figure no1, figure no 2). There are no studies to support the correlation between dental arch morphology, malocclusion and karyotype^{2,3}.

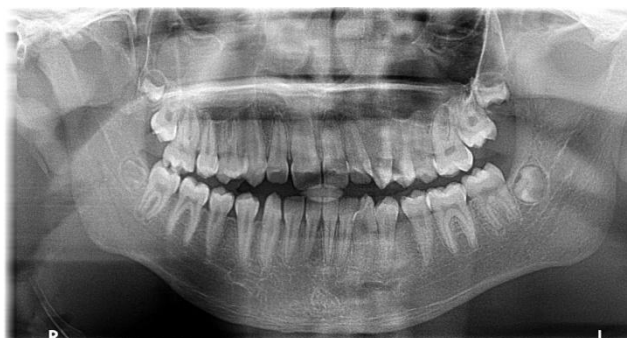

Figure no1 Radiographic aspects: class II of malocclusion, medial mandible line deviated 4 mm to the left
Endo-oral examination revealed:

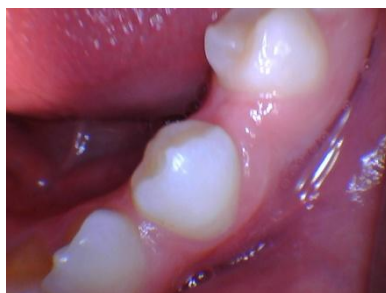

Figure no 2- Endo-oral examination: dental space - in lateral area

At the occlusion exam, there was found a lateral inverse occlusion (figure no 3) and a frontal occlusion (figure no 4), the medial mandibular line being diverted 4 mm to the left.

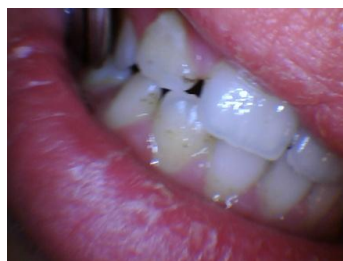

Figure no 3- Endo-oral examination: frontal inverse occlusion

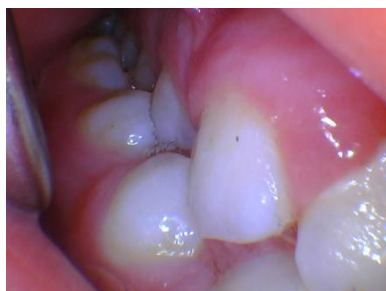

Figure no 4- Endo-oral examination: lateral inverse occlusion and rotated teeth

At dental level there are structural, shape changes, and also a reduction of the orolingual and mesiodistal dimensions. The dental elements have small dimensions due to the low enamel thickness. The final thickness of the enamel layer is marked by the secretory state of the amelogenesis. Haploinsufficiency of the AMELX gene suggests the damage of amelogenesis^{19,20}.

Lateral cephalometry (figure no 5) was performed under standardized conditions, with teeth in centric occlusion.

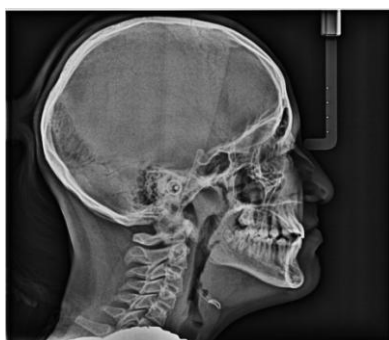

Figure no 5 Lateral cephalometry

The cephalometric variables were studied : the anterior skull base (n-s), the posterior skull base (s-ba), the skull base (n-ba), the maxillary prognathism angle (SNA), the mandible prognathism angle(SNB), mandible length (gn-tgo), angle ML-NL, anterior face height in the lower segment – (sp-gn) (figure no 6, figure no 7).

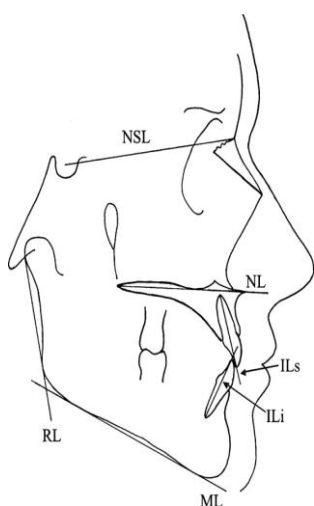


Figure no 6- Reference points (Midtbo et al. ²¹)

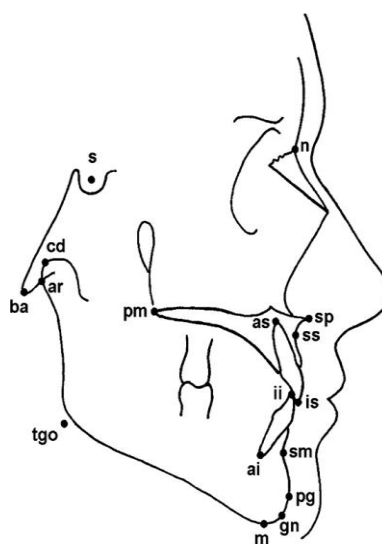


Figure no 7- Reference points (Midtbo et al. ²¹)

The values in mm of these measurements are shown in the following table (table no 4).

Table no 4 Cephalometric variable

The cephalometric variable	Values
n-s (mm)	63.6
s-ba (mm)	39,2
n-ba (mm)	86,7
SNA(°)	78
SNB(°)	78,2
Gn-tgo (mm)	68
Sp-gn (mm)	53,4
ML-NL (°)	23,6

Measurements were performed manually by a single investigator. We have the consent of the legal representative of the patient to use all the data.

III. Discussions

The growth hormone treatment initiated at the age of nine and three months resulted with an increase in the waist of 14 cm over 2 years and 3 months. Thus, the effectiveness of the growth hormone is demonstrated on linear growth in order to reach the average genetic waist. Aspects of maxillo-facial and oral morphology of Turner syndrome patients are relatively limited in terms of teeth eruption and development ²².

The results of growth hormone therapy on craniofacial morphology in Turner syndrome have not been studied extensively. But there are authors who report the influence of therapy on the development of the

mandible in comparison to the development of the base of the jaw or of the cranial base^{23, 24, 25}. In view of the long-term administration of GH therapy, numerous studies suggest monitoring effects and craniofacial development^{23, 24}.

The cephalometric measurements show a reduction in the anterior skull base value compared to the normal values²⁶, but also a reduction in the post cranial base^{27,28}.

These changes in the skull base are found in other studies, which also mention a reduction of the post base of the skull^{29, 30}.

The shortening of the posterior of the skull base has an influence on the maxillo-mandibular skeletal relationships that are affected in this pathology^{31,32}.

The prognathism angle of the maxilla and mandible (SNA-SNB) shows lower values in our case, demonstrating mandible and maxillary retrognathism (normal values - SNA 82° +/- 2 SNB 82° +/- 2 after STEINER analysis) The retrognathism of the maxilla and mandible is specific for ST patients but is found in other pathologies based on the reduction of growth hormone^{26, 33,34}.

The height of the front face in the lower segment is slightly reduced compared to normal³⁵.

The mandible length has a lower value compared to normal but slightly higher than the reported average of 60.7mm³⁵. Also, the ML-NL angle was measured having a value of 23.6° higher than the average of 21.32°³⁵ and indicating the retrognathism of the maxilla associated with the mandibular posterior rotation³⁵. All these craniofacial changes resulting from the anthropometric measurements on radiographic cephalometry are specific to TS typology, changes that inevitably lead to malocclusion. Knowledge of these anthropometric variables is absolutely necessary in orthodontic treatment to be initiated at these patients. Even if growth hormone treatment is initiated there is no correlation between the increase of the waist and the craniofacial development^{34,35}.

IV. Conclusions

The radiological and cephalometric examinations are suggestive for supporting oro-dental changes typically for Turner syndrome diagnosis. I studied a case of the Turner syndrome, followed over a 24-month period and found a significant improvement in waist as a result of establishing growth hormone therapy.

We also assessed craniofacial development by cephalometry and we can conclude that craniofacial changes fall within the typology described as characteristic of this pathology. Craniofacial aspects are the major interest for orthodontist, in order to establish appropriate treatment, given that there is no correlation between axial skeletal growth and craniofacial growth under growth hormone therapy.

The patient's growth hormone treatment has led to positive results, while proving the interdisciplinary collaboration: endocrine, orthodontics, cariology, endodontics, imaging specialist.

Authors' contribution

Preda Smaranda Adelina and Dana Maria Albulescu equally contributed to this article.

Conflicts of Interests: None

References

- [1]. Turner HH. A syndrome of infantilism, congenital webbed neck, and cubitus valgus. *Endocrinology* 1938; 23: 566–574.
- [2]. Cazzolla AP, Lo Muzio L, Di Fede O, et al. Orthopedic- orthodontic treatment of the patient with Turner's syndrome: Review of the literature and case report. *Spec Care Dentist*. 2018;1–10.
- [3]. Seung Yang. Diagnostic and therapeutic considerations in Turner syndrome. *Ann Pediatr Endocrinol Metab* 2017;22:226-230.
- [4]. Mohamed S, Roche EF, Hoey HM. Mode of initial presentation and chromosomal abnormalities in Irish patients with Turner syndrome: a single-centre experience. *J Pediatr Endocrinol Metab* 2015;28:1215-8.
- [5]. Wonkam A, Veigne SW, Abass A, Ngo Um S, Noubiap JJ, Mbanya JC, et al. Features of Turner syndrome among a group of Cameroonian patients. *Int J Gynaecol Obstet* 2015;129:264-6.
- [6]. Miguel-Neto J, Carvalho AB, Marques-de-Faria AP, Guerra- Júnior G, Maciel-Guerra AT. New approach to phenotypic variability and karyotype-phenotype correlation in Turner syndrome. *J Pediatr Endocrinol Metab* 2016;29:475-9.
- [7]. Rao E, Weiss B, Fukami M, et al. Pseudoautosomal deletions encompassing a novel homeobox gene cause growth failure in idiopathic short stature and Turner syndrome. *Nat Genet* 1997; 16: 54–63.
- [8]. Tossion H, Rose SR, Gartner LA. Description of children with 45,X/46,XY karyotype. *Eur J Pediatr*. 2012;171:521–529.
- [9]. Donaldson MD, Gault EJ, Tan KW, Dunger DB. Optimising management in Turner syndrome: from infancy to adult transfer. *Arch Dis Child*. 2006;91:513–520.
- [10]. Roopa Kanakatti Shankar and Philippe F. Backeljauw Current best practice in the management of Turner syndrome. *Ther Adv Endocrinol Metab* 2018, Vol. 9(1) 33–40.
- [11]. Zbranca Eusebie *Endocrinologie – Ghid de diagnostic si tratament* Editura Polirom 2007 .
- [12]. Gravholt CH, Andersen NH, Conway GS, et al. Clinical practice guidelines for the care of girls and women with Turner syndrome: proceedings from the 2016 Cincinnati International Turner Syndrome Meeting. *Eur J Endocrinol* 2017; 177: G1–G70.
- [13]. Davenport ML. Approach to the Patient with Turner syndrome. *J Clin Endocrinol Metab*, April 2010, 95(4):1487–1495.
- [14]. Ewelina Witkowska-Se, dek, Ada Borowiec, Anna Kucharska, Karolina Chacewicz, Małgorzata Rumin´ ska, Urszula Demkow, and Beata Pyrz´ak -Thyroid Autoimmunity in Girls with Turner Syndrome -*Adv Exp. Medicine, Biology - Neuroscience and Respiration Springer International Publishing Switzerland* 2017
- [15]. Lleo A, Moroni L, Caliani L, Invernizzi P. Autoimmunity and Turner syndrome. *Autoimmun Rev* 2012;11:A538.

- [16]. Invernizzi P, Pasini S, Selmi C, Gershwin ME, Podda M Female predominance and X chromosome defects in autoimmune diseases. *J Autoimmun* 2009;33:12–16–A543.
- [17]. Aversa T, Messina MF, Mazzanti L, Salerno M, Mussa A, Faienza MF, Scarano E, De Luca F, Wasniewska M -The association with Turner syndrome significantly affects the course of Hashimoto's thyroiditis in children, irrespective of karyotype. *Endocrine* 2015;50:777–782.
- [18]. Gravholt CH, Andersen NH, Conway GS, *et al.* Clinical practice guidelines for the care of girls and women with Turner syndrome: proceedings from the 2016 Cincinnati International Turner Syndrome Meeting. *Eur J Endocrinol* 2017; 177: G1–G70.
- [19]. Villa A, Albonico A, Villa F. Hypodontia and microdontia: clinical features of a rare syndrome. *J Can Dent Assoc.* 2011;77:b115.
- [20]. Rizell S, Barrenäs ML, Andlin-Sobocki A, Stecksén-Blicks C, Kjellberg H. Turner syndrome isochromosome karyotype correlates with decreased dental crown width. *Eur J Orthod.* 2012;34:213–218.
- [21]. Midtbo M, Wisth PJ, Halse A. Craniofacial morphology in young patients with Turner syndrome. *Eur J Orthod* 1996;18:215–25.
- [22]. Nozomi Ahiko, Yoshiyuki Baba Michiko Tsuji, Reiko Horikawa, and Keiji Moriyama. *Investigation of Maxillofacial Morphology and Oral Characteristics with Turner Syndrome and Early Mixed Dentition- Congenital Anomalies* 2018
- [23]. Rongen-Westerlaken, C., vd Born, E., Prah Andersen, B., von Teunenbroek, A., Manesse, P., Otten, B. J., et al. Effect of growth hormone treatment on craniofacial growth in Turner's syndrome. *Acta Paediatrica*, 1993; 82(4), 364–368.
- [24]. Simmons, K. E. Growth hormone and craniofacial changes: preliminary data from studies in Turner's syndrome. *Pediatrics*, 1999;104(4 Pt 2), 1021–1024.
- [25]. Juloski, J., Scepan, I., Stefanovic, N., Pajevic, T., Markovic, E., & Glisic, B. Craniofacial morphology in Turner syndrome patients treated with growth hormone. *South European Journal of Orthodontics and Dentofacial Research*, 2015;2(1), 21–26.
- [26]. Minayo Funatsu; Koshi Satob; Hideo Mitanic .Effects of Growth Hormone on Craniofacial Growth .*Angle Orthodontist*, 2006 ;Vol 76, No 6, 970-976.
- [27]. Poole AE, Greene IM, Buschang PH. The effect of growth hormone therapy on longitudinal growth of the oral facial structures in children. *Prog Clin Biol Res.* 1982;101:499–516.
- [28]. Konfino R, Pertzalan A, Laron Z. Cephalometric measurements of familial dwarfism and high plasma immunoreactive growth hormone. *Am J Orthod.* 1975;68(2):196–201.
- [29]. Gron M, Pietila K, Alvesalo L. The craniofacial complex in 45,X/46,XX females. *Arch Oral Biol* 1999;44:1077–84.
- [30]. Perkiomaki MR, Kyrkanides S, Niinimaa A, Alvesalo L. The relationship of distinct craniofacial features between Turner syndrome females and their parents. *Eur J Orthod* 2005;27:48–52.
- [31]. Klocke A, Nanda RS, Kahl-Nieke B. Role of cranial base flexure in developing sagittal jaw discrepancies. *Am J Orthod Dentofacial Orthop* 2002;122:386–91.
- [32]. Kerr WJ, Adams CP. Cranial base and jaw relationship. *Am J Phys Anthropol* 1988;77:213–20.
- [33]. Luiz Alves Oliveira-Netoa; Maria de Fa'tima B. Melob; Alexandre A. Francoc; Alai'de H.A. Oliveirab;Anita H.O. Souzad; Euge'nia H.O. Valenc;ae; Isabela M.P.A. Brittoa; Roberto Salvatorif;Manuel H. Aguiar-Oliveirag Cephalometric features in isolated growth hormone deficiency. *Angle Orthod.* 2011;81:578–583.
- [34]. Sotiria Davidopoulou and Athina Chatzigianni, Craniofacial morphology and dental maturity in children with reduced somatic growth of different aetiology and the effect of growth hormone treatment .*Progress in Orthodontics* 2017;18:10.
- [35]. J. Dumancic Z. Kaic,M. Lapter Varga, T. Lauc,M. Dumic, S. Anic Milosevic, H. Brkic Characteristics of the craniofacial complex in Turner syndrome .*Archives of oral biology* 2010,55; 81 – 88.
- [36]. Maheshwari HG, Silverman BL, Dupuis J, Baumann G. Phenotype and genetic analysis of a syndrome caused by an inactivating mutation in the growth hormone-releasing hormone receptor: dwarfism of Sindh. *J Clin Endocrinol Metab.* 1998;83(11):4065–74.

Adina Ioana Cotoi. "Somatic and Biological aspects in Turner Syndrome - Case Report."
IOSR Journal of Dental and Medical Sciences (IOSR-JDMS), vol. 18, no. 3, 2019, pp 40-45.