

## Mineral Trioxide Aggregate as periapical obturation: A case report and review of literature.

Dr. Priyanka Dubey<sup>1</sup>, Dr. Manish Agarwal<sup>2</sup>, Dr. Santosh Singh<sup>3</sup>,  
Dr. Rinkal Luhana<sup>4</sup>, Dr. Swati Gurjar<sup>5</sup>, Dr. Kafeel Ahmad<sup>6</sup>.

<sup>1</sup>Post-graduate student, Department of Conservative dentistry and endodontics, People's College of dental sciences and research centre, Bhopal.

<sup>2</sup>Professor and Head of the department, Department of conservative dentistry and endodontics, People's College of dental sciences and research centre, Bhopal.

<sup>3</sup>Reader, Department of conservative dentistry and endodontics, People's College of dental sciences and research centre, Bhopal.

<sup>4</sup>Post-graduate student, department of conservative dentistry and endodontics, People's College of dental sciences and research centre, Bhopal.

<sup>5</sup>Post-graduate student, department of conservative dentistry and endodontics, People's College of dental sciences and research centre, Bhopal.

<sup>6</sup>Junior Resident, Department of Oral and Maxillofacial surgery, People's Dental Academy, Bhopal.  
Corresponding Author: Dr. Priyanka Dubey

---

**Abstract:** Disease of maxillary anterior teeth resulting from any injury is a relatively common event. These teeth should be properly managed to improve long term success rate and better prognosis. Recently in many literature Mineral trioxide aggregate (MTA) has emerged as a biocompatible material that stimulates periapical tissue repair at the root end region. In this article, we present a case report of management of a big cystic lesion in relation to the apex of the maxillary anterior teeth. Root canal treatment was followed by resection of the root end of the tooth at the apex level and sealed with Mineral trioxide aggregate (MTA). Ten month follow up, both clinically and radiograph shows excellent prognosis.

**Keyword:** root canal therapy, apicoectomy, periapical cyst, periapical obturation, Mineral trioxide aggregate (MTA)

---

Date of Submission: 28-03-2019

Date of acceptance: 13-04-2019

---

### I. Introduction

The aim to have a successful Root Canal Treatment is to have a perfectly sealed root canal space which is obturated by a wide variety of materials which are bacteriostatic and prevent further ingress of microorganisms.<sup>1</sup> It has been published in literature that, coronal micro leakage is one of the major causes of failure of endodontic treatment.

A long standing non-vital tooth may sometime be associated with a big periapical granuloma or cyst. For such case, usually endodontic surgical procedures are preferred. As per the literature. The three reasons including endodontic surgery are as follows<sup>2</sup>-

1. If the prognosis is poor in case where only endodontic therapy alone has a strong possibility of failure.
2. In case of failed endodontic therapy and outcome of further retreatment by endodontic therapy alone has a possibility of failure again.
3. If periapical cyst where enucleation is indicated.

While doing endodontic surgery, the apical seal is a must for a favourable outcome. The ideal requirement of root end filling material should be that it should be non-allergic, compatible with neighbouring osseous or non-osseous tissues and should provide excellent sealing property.<sup>3</sup> **Torabinejad et al in 1993**, introduced Mineral trioxide aggregate (MTA) as a root end filling material. It has been reported in many studies that MTA has excellent sealing ability, enhanced osteoblastic and antimicrobial activity.<sup>3</sup>

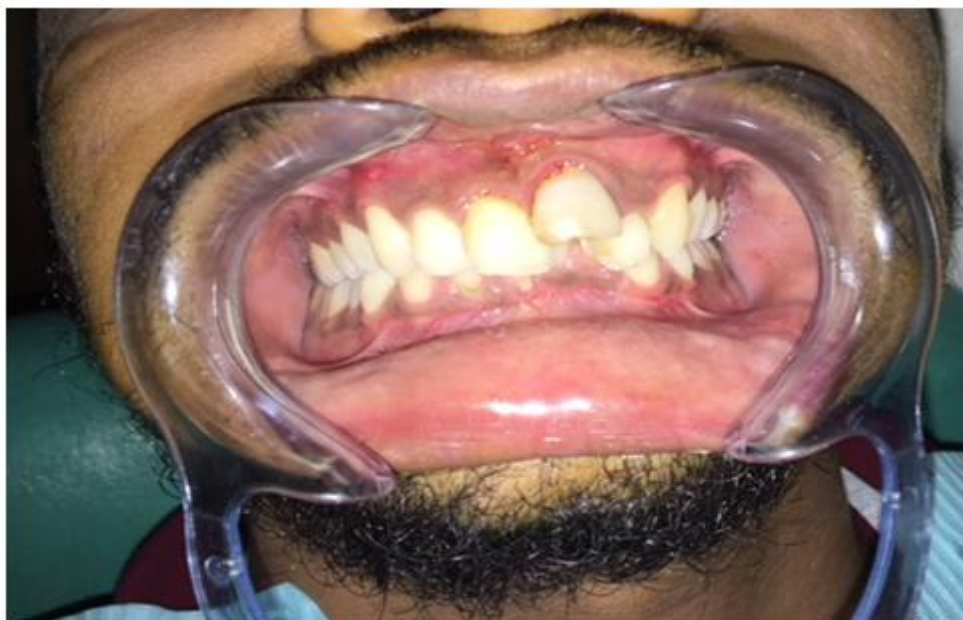For a successful apical seal, the recipient area must be carefully managed. As per the principle of PASS, for a successful outcome of periapical surgical regeneration, good primary closure, stable suture wound, and source of undifferentiated mesenchymal cells are all very important factors.<sup>4</sup>

The present case report focuses on the importance of surgical endodontic intervention, planning and proper execution for successful restoration of an infected tooth to its normal function and form.

## II. CASE REPORT

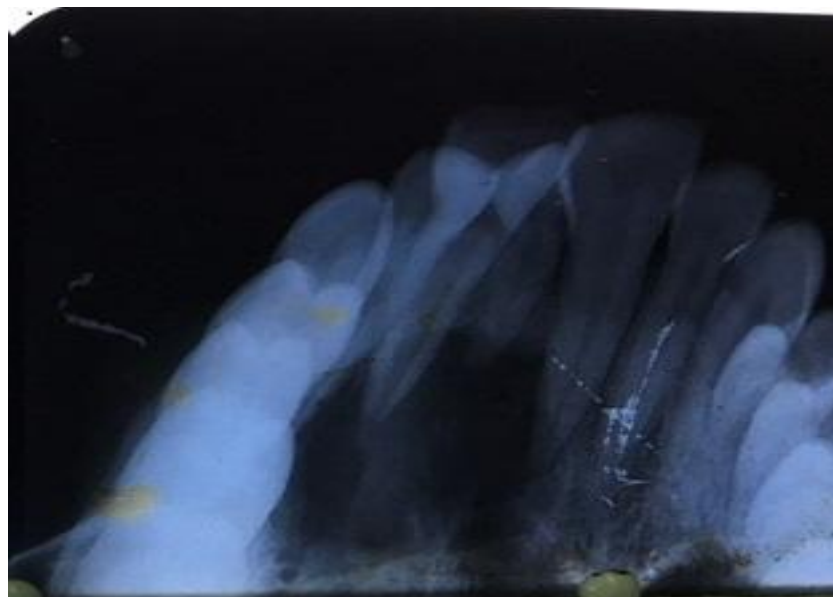
A 20 year old male patient reported in the department of Conservative Dentistry and Endodontics with a chief complaint of injury to upper front tooth region. Brief history of injury was taken, and it revealed that trauma had occurred 10 years back due to fall from staircase of his school. Past dental history revealed that patient did not visited to any dentist earlier. Past medical history revealed no relevant history.

Clinical evaluation revealed that a greyish black discoloration was present in 21 tooth, which was labially erupted and an accessory mesiodens was present between 11 and 21 region.[figure 1]



**Figure 1:** pre operative view

Tenderness on percussion was negative but vestibular tenderness was present when palpated buccally. Extra-orally no abnormality detected. Further investigations involved IOPA, OCCLUSAL RADIOGRAPH, vitality tests were performed. Vitality tests showed negative response w.r.t. 21,22,23. Occlusal radiograph [Figure 2] and IOPA [ figure 5] showed a big radiolucency suggestive of peri-apical cystic lesion involving 11,21,22,23.

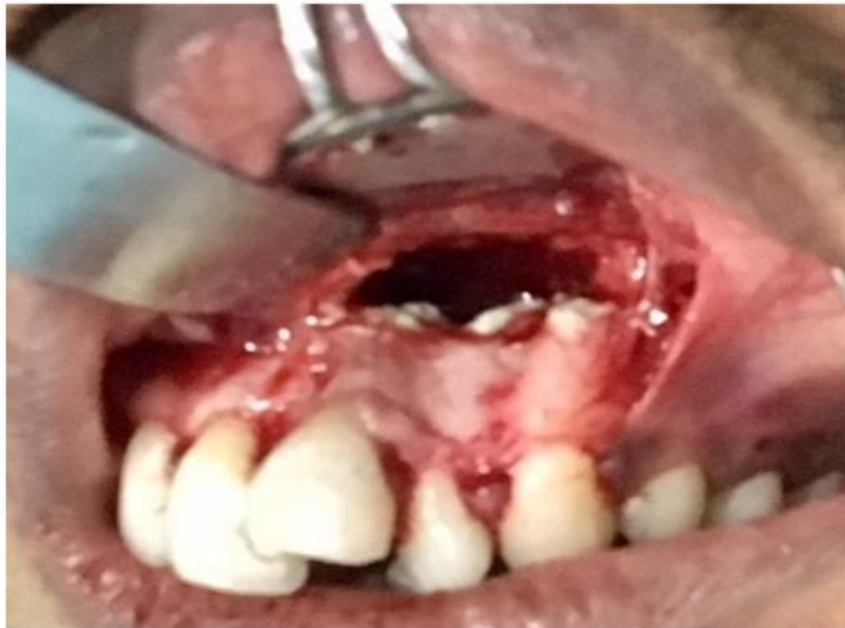

**Figure 2:** Occlusal radiograph [Figure 2] showed a big radiolucency suggestive of peri-apical cystic lesion. Root canal treatment was started as a preliminary treatment w.r.t. 11,21,22,23. On the day one, while access opening, pus discharge was seen w.r.t. 21, hence open dressing was given w.r.t. 21 and Ca(OH)<sub>2</sub> closed dressing

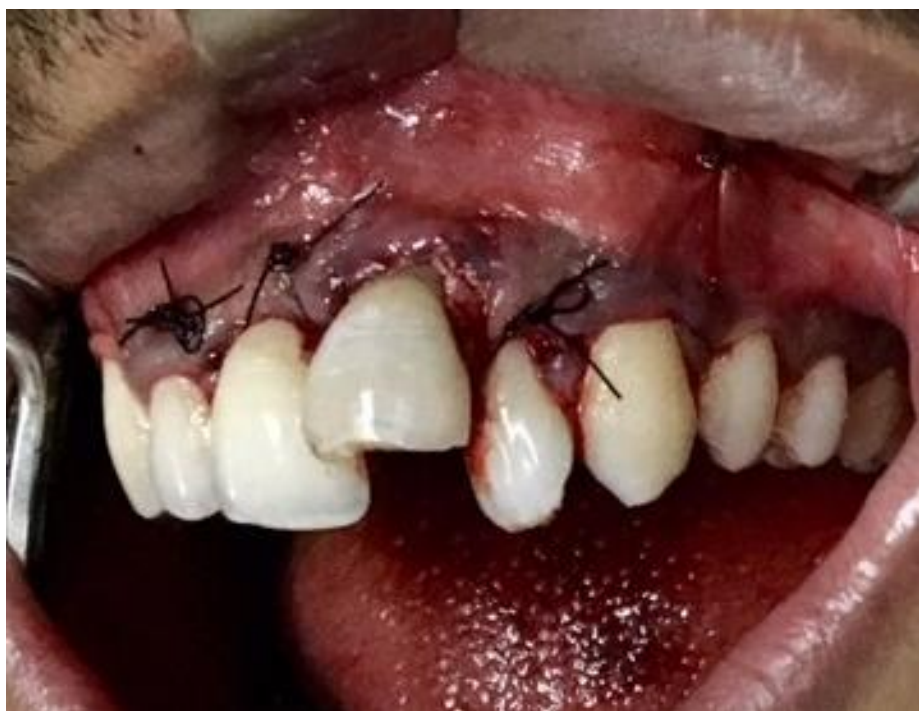was given in rest of the teeth. Later on, patient was recalled, and no discharge was noticed then canal was dried with paper points and  $\text{Ca(OH)}_2$  closed dressing was given. Dressings of intracanal medicament [ $\text{Ca(OH)}_2$ ] was changed twice in the intermediary appointments. While obturation, vestibular tenderness was present and to excise the peri-apical cyst, surgery was planned on the next day of obturation.

Envelope incision placed and mucoperiosteal flap was raised, bone cutting was done at the apex of 11, 21, 22, 23 to expose the apical thirds of the roots and the cystic cavity. Granulomatous tissue and cystic lining was enucleated from the cystic cavity, preserving the chances of palate to get perforated. The excised tissue was sent for histopathological examination. After enucleation, 3 mm of apical roots were resected, retrograde cavity was prepared by an inverted cone bur of micromotor. [Figure 3]

Retrograde filling was done with Mineral trioxide aggregate (MTA). Flap closure was done by 30 silk suturing. [Figure :4]

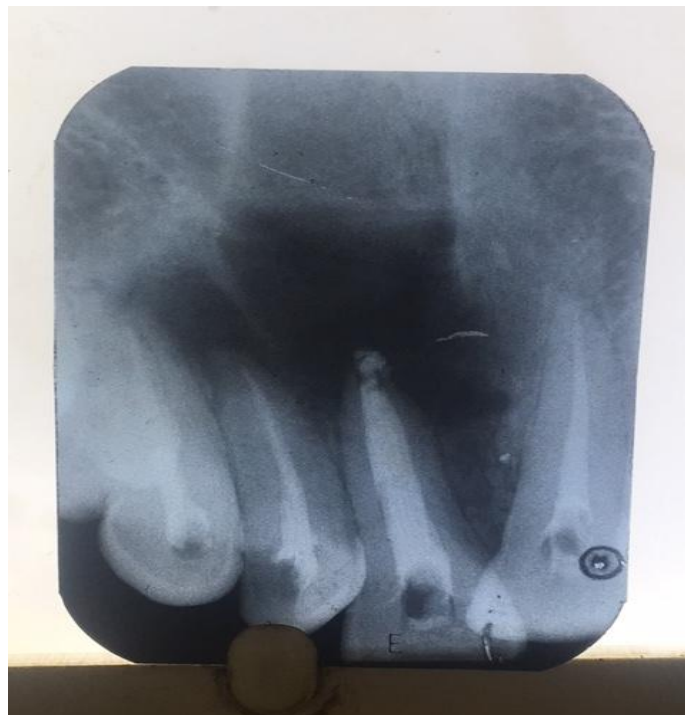

**Figure : 3,**Retrograde filling was done with Mineral trioxide aggregate

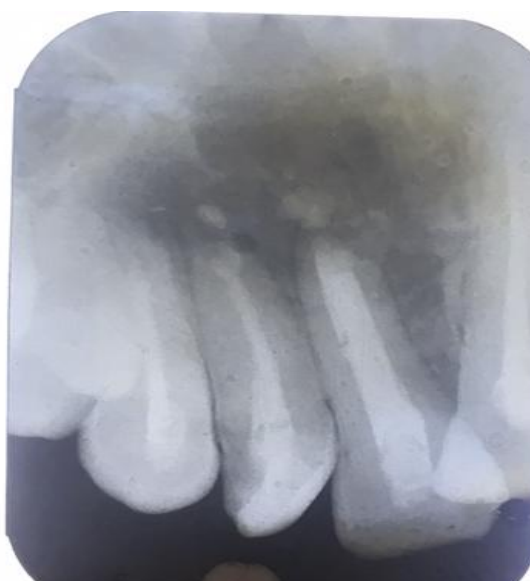

**Figure 4:** Flap closure

Patient was kept under proper follow up and healing was evident in radiograph taken ten months after the surgery. figure : 6.



**Figure 5:** Immediate post operative IOPA



**Figure 5:** post operative IOPA after 10 months showing good healing

### **III. Discussion**

For a successful prognosis of root canal treatment a perfect apical seal and perfect seal of canal space is must which prevents further migration of microorganism into the apical region from the oral cavity and also prevent their survival by obstructing the nutrient supply to these micro-organism<sup>1</sup>.

MTA is a biocompatible silicate cement which is non-irritant to the periapical tissue and also help in regeneration of periodontal ligament fibers and cementum<sup>1,7</sup>. MTA stimulate immune cell to release lymphokines which is require in the body for regeneration and repair of cementum. It also stimulates certain factor which helps in biomineralisation and healing of periapical osseous defect<sup>1</sup>.

When ever due to any type of injury or dental caries which results in periapical infection and loss of vitality of tooth, a clinician must weighed the endodontic treatment over tooth extraction and replacement<sup>2</sup>,if a

favourable outcome is expected then a conservative endodontic therapy with or without surgical intervention is justified and should always be attempted by the clinician<sup>2</sup>. In the present case there was a large periapical radiolucency which was indicative of periapical cyst, as seen the age of the patient and good oral hygiene he had decided to do root canal treatment followed by cyst enucleation and retrograde filling by MTA.

Clinicians usually agree that for the outcome of apicectomy to be successful, a root and filling material has to be placed periapical for having a good periapical seal. The importance of performing root canal filling with periapical root end resection followed by periapical root and seal usually shows better outcome<sup>6</sup>.

As per the literature search, we had found that there is a significant difference in the post-operative treatment outcome where only root end was resected followed by smoothing of gutta-percha cone to that of retrograde root end seal with the help of root end sealant like MTA<sup>6</sup>.

As per the literature over 24 million endodontic procedures are performed annually, out of which approximately 5.5% of the cases require perforation repair, apexification and periapical surgery<sup>8</sup>.

When we plan to do periapical surgery with periapical seal the ideal endodontic material which is used to repair and seal the periapical tissue should have the following characteristics. It should be radiopaque, non-resorbable, dimensionally stable, should adhere to tooth structure, should have adequate periapical seal and should be insoluble to tissue fluid. It should be sterile and must be biocompatible<sup>8</sup>. Mineral trioxide aggregate satisfies majority of all the above characteristics hence we decided to place Mineral trioxide aggregate as periapical sealing material.

In the study published by R. Christiansen et al (9), and by Thomas von Arx et al (10) has reported that 96% success in cases where he used MTA as periapical sealing material. They also reported that any fenestration or improper handling of the surrounding tissue can negatively affect the periapical bone healing.

**Conclusion-** Those cases where a large periapical cyst is diagnosed, due to irreversible pulpitis, the osteoinductive and chemogenic material like Mineral trioxide aggregate sound promising results as reported in the literature the teeth obturated with MTA not only increase the resistance to fracture but also act as bacteriocidal sealant material.

### Reference

- [1]. George Bogen, Sergio Kuttler. Mineral Trioxide Aggregate Obturation: A Review and Case Series. JOE-2009, Vol. 35, No. 6.
- [2]. Aditya Shetty, C. Ravi Chandra, Mithra N. Hedge, Uday S. Mahale, Ganesh Bhat. Mineral Tri-oxide Aggregate (MTA) For The Repair Of Periapical Tissues In A Patient With Self Inflicted Injuries: Case Report. NUJHS 2013, Vol. 3, No 1; 86-89.
- [3]. Seung-Ho Baek, Woo Cheol Lee, Frank C. Setzer, Syngcuk Kim. Periapical Bone Regeneration after Endodontic Microsurgery with Three Different Root-end Filling Materials: Amalgam, SuperEBA, and Mineral Trioxide Aggregate. JOE-2010, volume 36, Number 8; 1323-1325.
- [4]. Dr Mohammed Sadique, Dr Nithu Marina Terence, Dr B Bhavya, Dr Benny Varghese. Surgical Management of A Large Periapical Lesion with Prf And Xenograft- A Case Report. IOSR-JDMS, 2016, Volume 15, Issue 5 Ver. VI; 1-3.
- [5]. Casper Kruse, Rubens Spin-Neto, Rene´ Christiansen, Ann Wenzel, Lise-Lotte Kirkevang. Periapical Bone Healing after Apicectomy with and without Retrograde Root Filling with Mineral Trioxide Aggregate: A 6-year Follow-up of a Randomized Controlled Trial. J Endod 2016; 1-5.
- [6]. Wallvaara DA, Abrahamsson P, Fogelin M. Periapical Surgery with IRM and MTA as Retrograde Root-end Fillings-A Prospective Randomized Clinical Study of 186 Consecutive Teeth. Dentistry 2016, 6:9; 1-6.
- [7]. N. Economides, O. Pantelidou, A. Kokkas, D. Tziafas. Short-term periradicular tissue response to mineral trioxide aggregate (MTA) as root-end filling material. International Endodontic Journal 2003, 36, 44-48.
- [8]. Howarts W. Roberts, Jeffrey M. Toth, David W. Berzins, David G. Charlton. Mineral trioxide aggregate material use in endodontic treatment: A review of the literature. Dental Materials 2008, 24; 149-164.
- [9]. R. Christiansen, L.-L. Kirkevang, P. Horsted-Bindslev, A. Wenzel. Randomized clinical trial of root-end resection followed by root-end filling with mineral trioxide aggregate or smoothing of the orthograde gutta-percha root filling-1 year follow up. International Endodontic Journal 2009, 42, 105-114.
- [10]. Thomas von Arx, Stefan Hanni, Simon Storgard Jensen. Clinical Results with Two Different Methods of Root-end Preparation and Filling in Apical Surgery: Mineral Trioxide Aggregate and Adhesive Resin Composite. JOE 2010, volume 36, Number 7; 1122-1129.

Dr. Priyanka Dubey. "Mineral Trioxide Aggregate as periapical obturation: A case report and review of literature." IOSR Journal of Dental and Medical Sciences (IOSR-JDMS), vol. 18, no. 4, 2019, pp 01-05.