

The Three Facets Of Gall Bladder Perforation Dictate the Course Of Management.

Dr.Ratna Chopra¹, Dr.Ramkumar P², Dr.Abhideep kumar³,
Dr.Yoganand sagar⁴

¹HOD, Department of General Surgery, HinduRao Hospital & NDMC medical college, Delhi.

²Post Graduate Student, Department of General Surgery, Hindu Rao Hospital & NDMC medical college, Delhi.

³Senior Resident, Department of General Surgery, Hindu Rao Hospital & NDMC medical college, Delhi.

⁴Post Graduate Student, Department of General Surgery, Hindu Rao Hospital & NDMC medical college, Delhi.
Corresponding Author:Dr.Ramkumar P

Abstract: Gall bladder perforation is a rare and may be life threatening. It may be a complication of acute calculus or acalculouscholecystitis.Generalised Peritonitis, localized peritonitis, residual sequelae of silent perforation identified during elective surgery are the three clinical presentations of this condition. Generalised peritonitis warrants exploration, clinical course in localised peritonitis determines an operative or conservative management or local intervention.Peroperative findings dictate management in during elective surgery in cases of silent perforation. Optimal outcomes for structured protocol in managing consecutive cases in each of the three sets in a tertiary care hospital have been studied.

Key words: Gall bladder, Perforation, Cholecystitis.

Date of Submission: 04-04-2019

Date of acceptance: 19-04-2019

I. Introduction

Gallbladder perforation is usually due to calculus or acalculouscholecystitis. The incidence of gallbladder perforation in acute cholecystitis is reported in the range of 2 to 18%.^[1,2]Between calculous and acalculouscholecystitis, the overall incidence of gallbladder perforation due to acalculouscholecystitis is higher, approximately 10 to 20%.^[3]

In 1934, Neimeier^[4]had classified gall bladder perforation into three categories.

Type 1 (acute): perforation with generalized peritonitis.

Type 2 (sub-acute): pericholecystic abscess / localized peritonitis.

Type 3 (chronic): cholecystoenteric fistula of the gall bladder with or without cholelithiasis.

The main objective of this study is to study the importance of clinical evaluation supported by basic diagnostic imaging in establishing a preoperative diagnosis of gall bladder perforation and to evaluate the outcomes of management among these patients.

The secondary objective of this study was to predict the risk factors for gall bladder perforation among patients presenting with signs and symptoms in each of the three sets.^[3]

The timely intervention is very important in the gall bladder perforation because of high mortality and morbidity.^[6]

Three such different presentations with three different management strategies for gall bladder perforation are described below.

CasePresentation

First case: Generalized Biliary peritonitis managed by Laparotomy.

A 61 years old gentleman not a previously diagnosed cholelithiasis, Presented to emergency with diffuse abdominal pain for 1 day which was sudden in onset associated with non biliousvomiting. No history of previous jaundice/ trauma/not taking any medication for co-morbidities(Diabetes/Hypertension/tuberculosis).No H/O loss of weight/Appetite.Patient was febrile (103 degree F), Pulse rate 116 beats/min, B.P – 102/74 mm Hg. On examination abdomen was distended, generalised tenderness all over abdomen, guarding and rigidity present. Bowel sounds was absent. Liver, spleen was not enlarged.His Hb was 10.8 g/dl, TLC – 16,000 cells/cu.mm, RBS – 176 mg/dl. Bilirubin Total – 1.6 and Bilirubin Direct – 0.4 mg/100 ml.

X Ray showed multiple air fluid levels with features suggestive of ileus. USG abdomen and pelvis showed free fluid in the peritoneal cavity. After taking consent, exploratory laparotomy was done. 1.5 liters of

bile stained fluid was drained. Gangrenous gall bladder was seen with perforation at the neck of the gall bladder with frozen calots. Sub total cholecystectomy was done.

He was newly diagnosed as diabetes and he was started on injectable insulin. HPE report showed chronic cholecystitis with ischemic necrosis of gall bladder wall. Post op operatively patient developed biliary fistula which was managed conservatively.

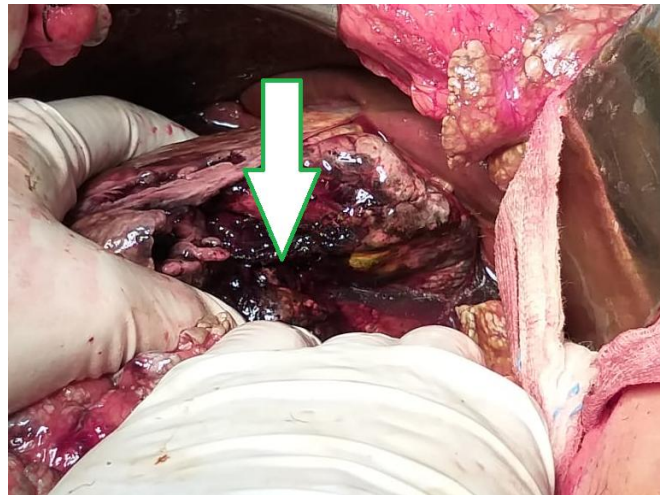


Figure 1: Intraoperative picture.

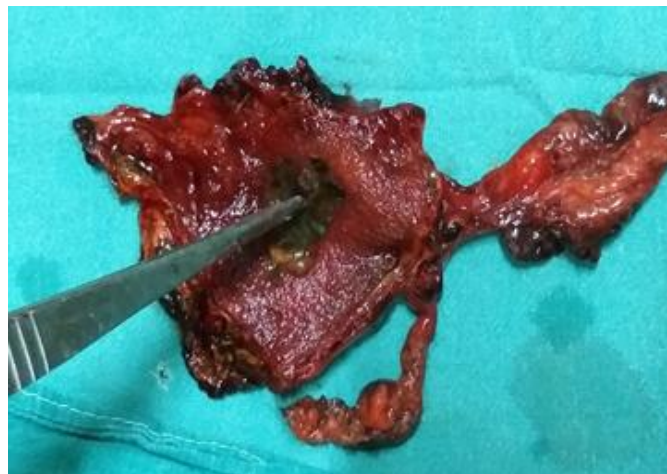


Figure 2: Picture showing Gangrenous gall bladder with perforation.

Second Case:Management of Localised peritonitis.

A 38 years old lady, known case of cholelithiasis, presented to emergency with shock with complaints of right upper abdominal pain for 7 days. Pain was sudden in onset, colicky type to begin with, and became continuous for last 1 day, associated with non bilious vomiting. No history of jaundice/ trauma/any medication for concomitant co-morbidities. No loss of weight/Appetite. Patient was febrile (100 degree F), Pulse rate 122beats /min, B.P – 82/60mm Hg.

Patient was vigorously resuscitated with iv fluids, inotropes, higher antibiotics and analgesics.

On examination of abdomen,tenderness present over the right hypochondrium with ill defined lump with guarding. Rest abdomen was normal. Her Hb was 8.7 g/dl, TLC – 22,000 cells/cu.mm, RBS – 102 mg/dl. Rest blood investigations were normal.

X ray abdomen – Normal.

Ultrasound abdomen – Gall bladder distended with 4-5 mm multiple calculi in GB neck and wall thickness normal. GB lumen is filled with internal echoes and septations.

CECT whole abdomen – Encysted collection in right paracolic gutter and subhepatic region with fatty streakiness in subhepatic region. Localised collection adjacent to gall bladder fossa.Possibilityof sealed perforation.

Strict monitoring of vitals and abdominal symptoms was done throughout her hospital stay.

When the patient became hemodynamically stable, she was planned for MRI with MRCP.

MRI with MRCP Suggestive of mucocele of Gall bladder with cholelithiasis and acute calculus cholecystitis. Mural thickening at fundal region with diverticula formation and associated associated findings, as described, may suggest adenomyosis of gall bladder with possibility of underlying rupture, leading to localized biliary peritonitis.

Serum amylase levels raised. Serum lipase levels were normal.

Patient discharged and asked her to follow up with advice of planning for elective cholecystectomy.

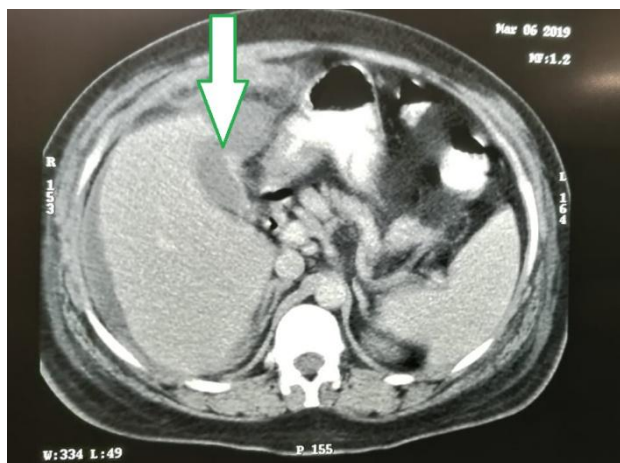


Figure 3 showing discontinuity in Gall Bladder wall in fundus region.

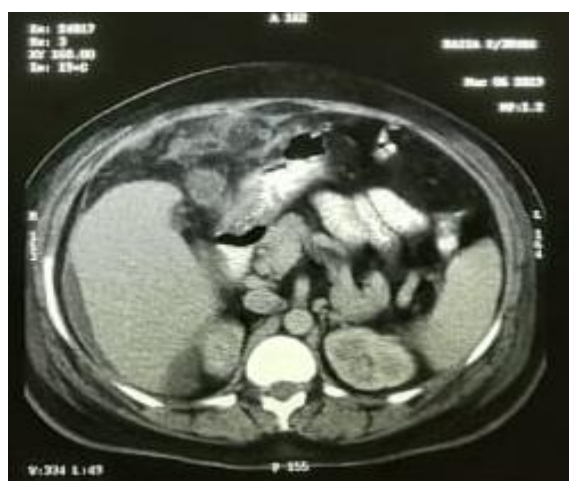

Figure 4 showing Sealed Gall bladder Perforation.

Third case: Residual Sequelae Of Silent Perforation Identified during Elective Surgery .

A 30 yr old lady , Known cholelithiasis for 2 years with no comorbidities, planned for elective cholecystectomy. She had severe acute attack of Pain before 18 months. For which she was hospitalized and managed conservatively.

Her USG showed multiple calculi of 2-3 mm with normal thickness of gall bladder wall. CBD was normal.

Intraoperatively, there was a surprise of sealed gall bladder perforation noted with calculi lying outside the wall wrapped in the omentum surrounding fundus of the gall bladder.

Only fundus of the gall bladder seen.No bile was noted. Rest was frozen.

Cholecystostomy was done after placing drainage tube through the fundus.

HPE shows features of cholecystitis. On 10 th day, cholecystostogram was done. It was normal.

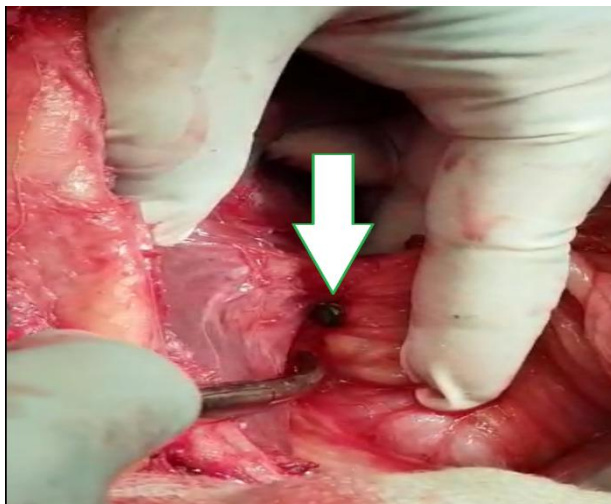


Figure 5 Intraoperative Picture

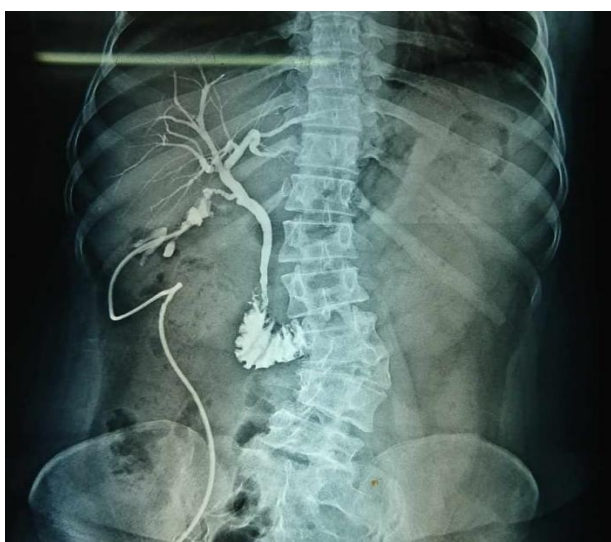

Figure 6 Cholecystogram

II. Discussion

The most plausible mechanisms for gallbladder perforation complicating acute cholecystitis are: 1) bile stasis due to cystic duct obstruction, fasting, dehydration, total parenteral nutrition, which leads to a change in the bile content and concentration; 2) vascular impairment of the gallbladder due to distension of the viscus, underlying systemic illness such as sepsis, shock, atherosclerosis; and 3) ischemic necrosis and perforation of the gallbladder wall. Gallbladder perforation occurs most commonly at the fundus, which has the least blood supply.^[5] This fact denotes the importance of the ischemic mechanism of gallbladder perforation. Since the difficulties in diagnosis cause delay in treatment, higher morbidity and mortality rates are often encountered.^[6,7]

In first scenario, the age of the patient and the underlying newly diagnosed diabetes are the main factors. The difference between type I and type II is that type I perforation is a clinical diagnosis (e.g. in the form of peritonitis) assisted by radiology, and its treatment is relatively straightforward in the form of urgent laparotomy and cholecystectomy, or cholecystostomy.^[8]

In contrast, the decision to treat type II perforations is more complex due to the chronic nature of the perforation. It is more likely to occur in older patients with greater co-morbidities and their questionable fitness for surgery often limits treatment options and poses challenges to the overall process of care. The treatment depends upon the hemodynamic status of the patients. The percutaneous drainage may be another option depending upon the situation.^[9] In case 2, the patient presented with shock and we managed the patient conservatively. The patient had pain for 7 days but she failed to present immediately. So the time of presentation and diagnosis will dictate the management. If there is any deterioration of general condition or progression of local signs in the patient, immediate surgical intervention should be done.

Cholecystectomy may be difficult in type 3 gallbladder perforations. If a cholecystectomy is performed, additional surgical procedures such as repair of the fistula may be required.^[10] In third case, silent perforation sequelae, only fundus could be exposed after dissection in view of dense adhesions, so cholecystostomy was done, thus stressing upon the importance of safe intraoperative access to gall bladder.

Glenn and Moore have reported that the mortality rate of gallbladder perforation patients is 42%^[11], while other studies reported that the mortality rates are decreased to 12%-16% owing to the developments in anesthesiology and intensive care conditions.^[12] In this study, three patients survived with some morbidity as mentioned above.

III. Result

In old age patients, generalized peritonitis may be due to ischemic necrosis of gall bladder wall, that warrants immediate surgical intervention. Serial monitoring of localized peritonitis is guided by both clinical and also radiological parameters. In patients of elective cholecystectomy, past history of prolonged hospitalization for pain may act as an indicator for suspicion of gall bladder perforation. Gall bladder perforation poses significant challenges during cholecystectomy that can impact the postoperative morbidity and mortality.

IV. Conclusion

High index of suspicion with early diagnosis supported with imaging and close clinical monitoring streamlines management for obtaining optimal outcomes. Clinical course of the patient acts as a direct guide to structured protocol of management for optimal outcomes.

References

- [1]. F. Lennon, W.E. Green. Perforation of the gall bladder. A review of 32 cases. *J R Coll Surg Edinb*, 28 (3) (1983), pp. 169-173
- [2]. F. Glen, S.W. Moore. Gangrene and perforation of the wall of the gallbladder. A sequelae of acute cholecystitis. *Arch Surg*, 44 (1942), pp. 677-686
- [3]. H. Derici, C. Kara, A.D. Bozdogan, O. Nazli, T. Tansug, E. Akca. Diagnosis and treatment of gallbladder perforation. *World J Gastroenterol*, 12 (48) (2006), pp. 7832-7836
- [4]. Niemeier OW. Acute Free Perforation of the Gall-Bladder. *Ann Surg*. 1934;99:922-924.
- [5]. Roslyn JJ, Thompson JE, Darvin H, DenBesten L. Risk factors for gallbladder perforation. *Am J Gastroenterol*. 1987;82:636-640.
- [6]. Menakuru SR, Kaman L, Behera A, Singh R, Katariya RN. Current management of gall bladder perforations. *ANZ J Surg*. 2004;74:843-846.
- [7]. Ong CL, Wong TH, Rauff A. Acute gall bladder perforation--a dilemma in early diagnosis. *Gut*. 1991;32:956-958.
- [8]. Estevo-Costa J, Soares-Oliveira M, Lopes JM, Carvalho JL. Idiopathic perforation of the gallbladder: a novel differential diagnosis of acute abdomen. *J Pediatr Gastroenterol Nutr*. 2002;35:88-89.
- [9]. C.C. Huang, H.C. Lo, Y.M. Tzeng, H.H. Huang et al. Percutaneous transhepatic gall bladder drainage: a better initial therapeutic choice for patients with gall bladder perforation in the emergency department. *Emerg Med J*, 24 (12) (2007), pp. 836-840
- [10]. Anderson BB, Nazem A: Perforations of the gallbladder and cholecystobiliary fistulae: a review of management and a new classification. *J Natl Med Assoc* 1987, 79:393-399.
- [11]. Glenn F, Moore SW. Gangrene and perforation of the wall of the gallbladder. A sequelae of acute cholecystitis. *Arch Surg*. 1942;44:677-686.
- [12]. Lennon F, Green WE. Perforation of the gallbladder. A review of 32 cases. *J R Coll Surg Edinb*. 1983;28:169-173.

Dr. Ratna Chopra. "The Three Facets Of Gall Bladder Perforation Dictate the Course Of Management."
IOSR Journal of Dental and Medical Sciences (IOSR-JDMS), vol. 18, no. 04, 2019, pp15-19.