

## Anatomical Study of Pulmonary Fissures and lobes in Human Cadavers

Dr. G. Sailaja<sup>1</sup>, Dr. M. Sudhakara Rao\*, Dr. P. Satish Kumar

<sup>1</sup>, Assistant Professor of Anatomy, Rangaraya Medical College, Kakinada,  
Andhra Pradesh.

Correspondence Address: \*Dr.M.Sudhakara Rao, Assistant Professor of Anatomy, Konaseema institute of  
medical sciences, Amalapuram, Andhra Pradesh. India.

---

**Abstract:** The fissures in lung allows uniform expansion. Awareness of Anatomical variations in lung fissures is essential during segmental resection of lungs Anatomical variations of lungs including number, fissures and lobes are important for clinicians. The aim of the present study is to observe the variations of lung fissures in Costal Andhra Pradesh region. 30 Pairs (Right 30, Left 30) of lungs were used for this study. segmentation of pulmonary lobes is challenging because of anatomical variations and incomplete fissures. With the development of radiological and endoscopic techniques and the advancement of pulmonary surgery, the knowledge of morphological variations of lung fissures is of utmost importance to clinicians to correctly locate the bronchopulmonary segment during pulmonary lobectomy, and for radiologists to correctly interpret X-rays and CT scans.

**Keywords:** Lobes; Lung; Oblique fissure; Tranverse Fissure;

---

Date of Submission: 24-03-2019

Date of acceptance: 08-04-2019

---

### I. Introduction

The lungs are the essential organs for respiration. The human lungs are sub divided in to lobes, that are separated by pulmonary fissures. There are three lobes in right lung and two lobes in left lung. The right lung has both oblique and horizontal fissures dividing into upper, Middle and Lower lobes. The left lung has only oblique fissure divides the lung in to upper and lower lobes. The oblique fissure separates the lower lobe from the remaining two lobes. It runs obliquely and crosses the inferior border of the lung about 7.5 cm behind its anterior end. The horizontal fissure separates the upper and middle lobe. It begins from the oblique fissure, runs horizontally and cuts the anterior border at inner end of fourth costal cartilage [1]. The oblique fissure of left lung which extends from costal to medial surfaces of the lung both above and below the hilum. It begins on the medial surface posterosuperior to the hilum, runs obliquely upwards and backward to cut the posterior border of the lung about 6 cm below the apex and then passes downward and forward across the costal surface. The more vertical left oblique fissure is approximately indicated by vertebral border of scapula in fully abducted arm [2].

When the embryo is approximately 4 weeks old, the respiratory diverticulum(lung bud) appears as an outgrowth from the ventral wall of the foregut [3]. Two endodermal bronchial buds grow from the caudal end of this bulb-shaped diverticulum, and are surrounded by splanchnic mesoderm. The bronchial smooth muscle and connective tissue and the pulmonary connective tissue and capillaries are derived from the mesoderm [4]. [5]Rosse and Gaddum-Rosse. During the development, as the lung grows, the spaces or fissures that separate individual bronchopulmonary buds/segments become obliterated except along two planes, evident in the fully developed lungs as oblique or horizontal fissures. The fissures may be complete, when the lobes remain held together only at the hilum by the bronchi and pulmonary vessels, or they may be incomplete when there are areas of parenchymal fusion between the lobes, or, they may be absent altogether Meenakshi [6] et al.. Absence or incomplete oblique or horizontal fissures could be due to obliteration of these fissures either completely or partially. Knowledge of their position is necessary for the appreciation of lobar anatomy and thus for locating the bronchopulmonary segments which is significant both anatomically and clinically. Craig and Walker [7] have proposed a manner of classification of fissure for describing operative technique and also for comparing different surgical series. The criteria used to classify the lung fissures were degree of completeness of fissure and the location of the pulmonary artery at the base of the oblique fissure. Four grades have been described: Grade I- complete fissure with entirely separate lobes; Grade II- complete visceral cleft but parenchymal fusion at the base of the fissure; Grade III- visceral cleft evident for a part of the fissure; and Grade IV- complete fusion of lobes With no evident fissure line. Understating of the normal Anatomy is very essential for the surgical knowledge Variant anatomy may lead to misinterpretation of a radiograph or computed

tomography (CT) scan [8]. Certain radiological findings can mislead the diagnosis as in the cases of extra lobes, as it may misinterpret as lung lesions. In the presence of extra lobes, the CT scan shows a significant increase in the size of mediastinum around the trachea[8]. Normally pneumonia will be restricted to the lobes affected by it, but in patients with incomplete fissures, it may spread to adjacent lobes through the parenchymal continuation [9, 10].

## II. Materials And Methods

30 pairs of lungs obtained from formalin fixed Adult cadavers removed during routine dissection at Rangaraya Medical College Kakinada. Of the 60 lung specimens 30 were of the right side and 30 were of the left side no gender difference of the lungs was made in this study only those lungs which were covered by pleura except at the hilum was used in the study. The lungs were examined for the pattern of Lobes, Fissures and its variations.

## III. Results

### Right Lungs:

Out of 30 right lungs 16 (53.3%) complete horizontal fissure, 13 (43.3%) showed incomplete horizontal fissure and 1 (3.3%) (Fig-1) showed complete absent horizontal fissure. Oblique fissure was complete in 22 (73.3%) and incomplete in 8 (26.6%) Table-1. Accessory fissure were noted in 2 right sided lungs having 1 superior accessory fissure (Fig-3) and 1 inferior accessory fissure (Fig-4).

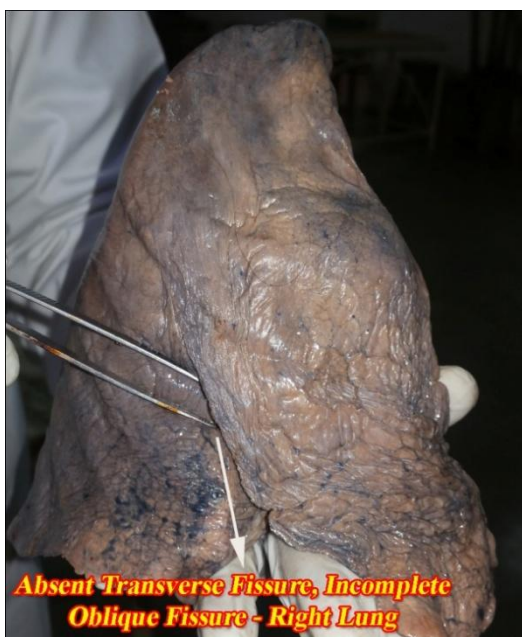### LeftLungs:

Among 30 left sided lungs 21 (70%) showed complete oblique fissure, 7 (23.3%) lungs showed incomplete oblique fissure and complete absent of oblique fissure was noted in 2 (6.6%) lungs (Fig-6). We have noticed 1 (3.3%) lungs with incomplete transverse fissure and complete absent of oblique fissure (Fig-7).

**Table-1**

|                   |                           | <b>Complete</b> | <b>Incomplete</b> | <b>Absent</b> |
|-------------------|---------------------------|-----------------|-------------------|---------------|
| <b>Right Lung</b> | <b>Horizontal Fissure</b> | 16 (53.3 %)     | 13 (43.3 %)       | 1 (3.3 %)     |
|                   | <b>Oblique Fissure</b>    | 22 (73.3 %)     | 8 (26.6 %)        | ----          |
| <b>Left Lung</b>  | <b>Oblique Fissure</b>    | 21 (70 %)       | 7 (23.3 %)        | 2 (6.6 %)     |

## IV. Figures



**Figure-1**



**Figure-2**

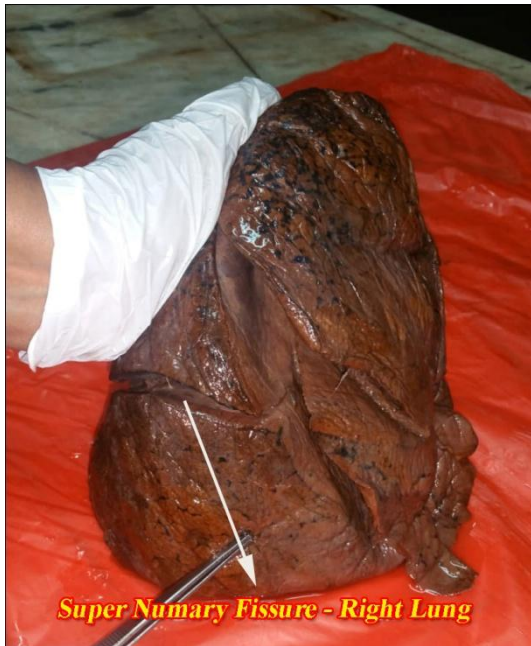

Figure-3

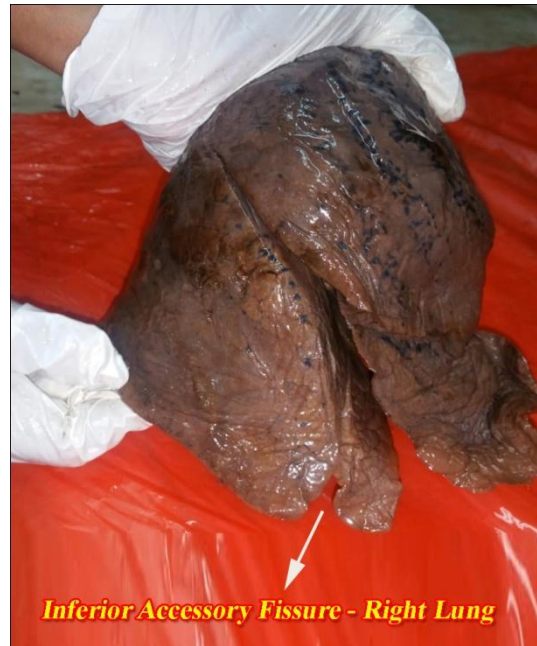

Figure-4



Figure-5

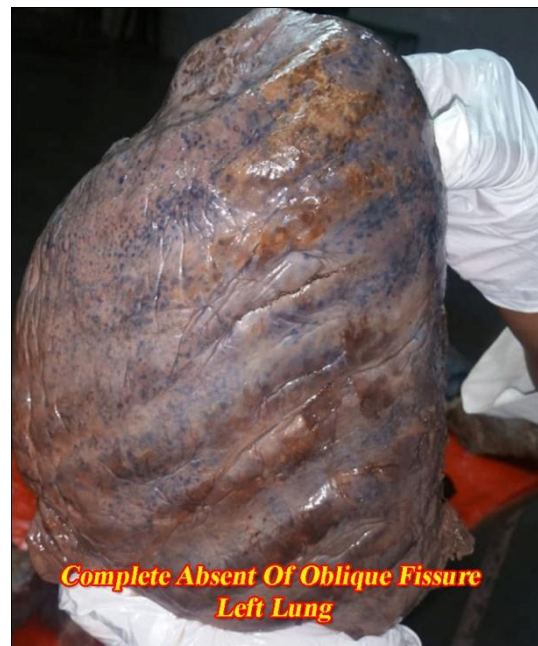
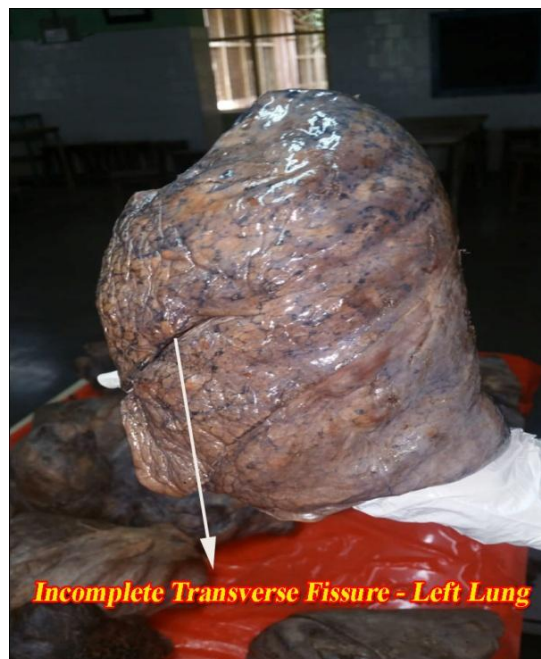

Figure-6





**Figure-7**

## **V. Discussion**

The fissures facilitate the movement of the lobes in relation to one another, which accommodates the greater distention and movement of the lower lobes during respiration. Thus, they help in a more uniform expansion of the whole lung (Rosse & Gaddum-Rosse[5], 1997). During development of lung numerous broncho pulmonary buds are formed and later they fuse completely except at the sites of fissure formation. This results in the formation of lobes and fissures. Incomplete fissure formation could be due to partial obliteration of this fissures [11]. Findings from live subjects (through CT scans) and specimens dissected from cadavers have frequently shown varying percentage of incomplete fissures, both oblique and horizontal, and also the presence of accessory fissures.

The findings of present study are being compared with previous research works by different authors. Prevalence of incomplete oblique fissure of right lung is (26.6% ), shows similarity with study done by Medlar (Table-II ), prevalence of incomplete transverse fissure of right lung is (43.3%) which shows similarity with the previous studies when compared (Table-II). In our study we have observed only 1 (3.3%) with complete absent of horizontal fissure, which is differing with the previous studies. In left lung the prevalence of incomplete oblique fissure is seen in 7 (23.3%) lungs which is differing with the previous studies. We have noticed 2 (6.6%) of left lungs without oblique fissure which was comparable with previous studies. Medlar, in his examination of 1200 pairs of lungs found incomplete oblique fissure in 10.6% in left lung, oblique fissures were absent in 7.3% of the left-sided In another study of 100 fixed and inflated lung specimens (50 of each side), Incomplete oblique fissure was present in 21% of left-sided lungs.

On the basis of CT scans, Otsuji[12] et al. (1993) made an analysis of both lungs in 154 patients, including seven cadavers, and came to the conclusion that the frequency of the incomplete inter-lobar fissure was high in right sided lungs(83.1%), when compared to the left lungs (50%). In the present study we have observed accessory fissures in 2 right sided lungs one is superior accessory fissure (Fig-3) and one is inferior accessory fissure (Fig-4). Accessory fissure can be mistakenly confused with areas of linear atelectasis, pleural scars or walls of bullae [13]. Accessory fissures could be the result of non-obliteration or persistence of the prenatel fissures any variation of the morphological pattern of the fissures indicates variations from normal pattern of development of lung

**Table II: Comparison of our study with other researchers**

| Authors       | Right Lung – Oblique Fissure |        | Right Lung – Horizontal Fissure |        | Left Lung – Oblique Fissure |        |
|---------------|------------------------------|--------|---------------------------------|--------|-----------------------------|--------|
|               | Incomplete                   | Absent | Incomplete                      | Absent | Incomplete                  | Absent |
| Medlar EM10   | 25.6%                        | 4.8%   | 62.3%                           | -      | 10.6%                       | 7.3%   |
| Lukose R etal | -                            | -      | 21%                             | 10.5%  | 21%                         | -      |
| Prakash etal  | 39.3%                        | 7.1%   | 50%                             | 7.1%   | 35.7%                       | 10.7%  |
| Nene AR etal  | 6%                           | 2%     | 8%                              | 14%    | 12%                         | 0%     |
| Present Study | 26.6%                        | -      | 43.3%                           | 3.3%   | 23.3%                       | 6.6%   |

## VI. Conclusion

clinicians and, surgeons should keep in mind regarding Variations in fissure while treating and assessing the prognosis of lung diseases. Anatomical variations in lung fissures and lobes are not uncommon. Prior knowledge of variations of fissures and lobes improves understanding of pneumonia, pleural effusion and collateral air drift. Knowing variations is important for planning of lobar resection because there is a higher prevalence of air leak in lobar fusion Hayashi [14] et al. Incomplete fissure may alter the usual patterns of collapse seen in patients with endobronchial lesions and may also give rise to atypical type of pleural effusion. Lobar pneumonias usually confined to particular lobe may spread to entire lung in case of absent fissure. The knowledge of anatomy of fissures of lung may help to clarify confusing radiographic findings like extension of fluid into an incomplete major fissure or spread of various diseases through different pathways Dandy WE Jr [15] accessory fissures can be mistakenly confused with areas of linear atelectasis and pleural scars the present study has differences with previous studies indicates, variety of genetic and environmental factors might effect development of these fissures.

## References

- [1]. Nene,R.,Gajendra,S.and Sarma,R.(2011).Lung lobes and fissures; a morphological study. International journal of experimental and clinical Anatomy,5; 30-38
- [2]. Ghosh,E., Basu,R.,Dhur,A.,Roy,A.,Roy,H. and Biswas,A. (2013).Variations of Fissures and Lobes In Human Lungs-A Multicentric Cadaveric Study from West Bengal, India. International Journal of natomy, Radiology and Surgery; 2(1): 5-8
- [3]. Sadler TW. Langman’s medical embryology. 11th ed. Baltimore: Lippincott Williams and Wilkins; 2010.
- [4]. Moore KL, Persaud TVN. The developing human:clinically oriented embryology. 8th ed. Philadelphia: Elsevier; 2008.
- [5]. Rosse, C. and P. Gaddum-Rosse, 1997. Hollinsheds Textbook of Anatomy. Lippincott-Raven, Philadelphia, pp: 441-61. ed.Philadelphia, Lippincott-Raven, 1997.
- [6]. Meenakshi, S., K.Y. Manjunath and V. Balasubramanyam, 2004. Morphological variations of the lung fissures and lobes. Indian J.Chest Dis. Allied Sci., 46: 179-182.
- [7]. CRAIG SR, WALKER WS (1997) A proposed anatomical classification of the pulmonary fissures. J R CollSurg Edin, 42: 233-234.
- [8]. Speckman JM, Gamsu G, Webb WR. Alterations in CT medi-astinal anatomy produced by an azygos lobe. AJR Am J Roentgenol 1981;137:47-50.
- [9]. Aldur MM, Denk CC, Celik HH, Tascioglu AB. An accessory fissure in the lower lobe of the right lung. Morphologie 1997; 81:5-7.
- [10]. Tarver RD. How common are incomplete pulmonary fissures, and what is their clinical significance? AJR Am J Roentgenol 1995;164:761.
- [11]. Medlar, E. M. Variations in interlobar fissures. Am. J. Roentgenol. Radium. Ther., 57(6):723-5,1947
- [12]. Otsuji, H.; Uchida, H.; Maeda, M.; Iwasaki, S.; Yoshiya, K.; Hatakeyama, M.; et al. Incomplete interlobar fissures: bronchovascular analysis with CT. Radiology, 187(2):541-6, 1993.
- [13]. Butler P, Mitchell AWM, Ellis H.Applied Radiological Anatomy. Cambridge(UK): Cambridge University Press; 1999:136-8.
- [14]. Hayashi, K.; Aziz, A.; Ashizawa, K.; Hayashi, H.; Nagaoki, K. & Otsuji, H. Radiographic and CT appearances of the major fissures. Radiographics, 21(4):861-74, 2001.
- [15]. Dandy WE Jr. Incomplete Pulmonary interlobar fissure sign. Radiology. 1978; 128:21-25.

Dr. M. Sudhakara Rao. “Anatomical Study of Pulmonary Fissures and lobes in Human Cadavers.” IOSR Journal of Dental and Medical Sciences (IOSR-JDMS), vol. 18, no. 04, 2019, pp 45-49.