

Anterior Interosseous Artery Perforator Flap for Distal Forearm and Hand Defects

Dr.G.Raveendra Reddy¹, Dr.A.R.Ch.Mohan², Dr.Jyostna Poldas³,
Dr.Lucky Reddy⁴.

¹Associate Professor, Department of Plastic Surgery, Government general hospital, Siddhartha medical college, Vijayawada, Andhra Pradesh.

²Professor and HOD, Department of Plastic Surgery, Government general hospital, Siddhartha medical college, Vijayawada, Andhra Pradesh.

³Assistant Professor, Department of Plastic Surgery, Government general hospital, Siddhartha medical college, Vijayawada, Andhra Pradesh.

⁴resident.

Corresponding Author: Dr.Jyostna Poldas

Abstract: Anterior inter osseous artery perforator flap is a versatile and reliable flap in covering volar aspect of distal forearm, dorsal surface of hand that are classical defects following electrocution and snake bite cellulitis sequel. Our experience with 5 cases done between 2017 to 2018 as transposition flap and island flap for defects following electrocution, infection and following trauma, was shared. No prior Doppler study was done to locate the perforator in any case. Perforator was present in all the cases. The planning, ease of dissection, surgical technique, reach of the flap and reliability has been discussed. All the flaps survived well.

Key Words: Anterior inter osseous artery perforator flap, post electrical burn defects of the hand and forearm, dorsal defects of hand, distal island flap of hand

Date of Submission: 25-03-2019

Date of acceptance: 09-04-2019

I. Introduction

For defects over this volar aspect of distal forearm and dorsum of hand, which are most commonly resulting due to post electrical burns and also as a sequel following snake bite cellulitis respectively, groin flap is the 'first choice' to be considered with all its merits and demerits like accessibility, ease of dissection, reliable blood supply, hidden scar and area of available tissue(1). However, being a two stage procedure with hand relatively immobilized at least for two weeks, being a bulky flap, need for thinning in later stages became a rule rather than exception, made the reconstructive surgeon to look for other alternatives.

Microsurgery has fulfilled the needs and requirements, however highly demanding technical skills, expertise, and long surgical duration pushed this to second position, when there is local or regional adequate tissue available. Radial artery and Ulnar artery flaps compromises axial vessels of the limb. Even though posterior interosseous artery flap has replaced groin flap to a certain extent, due to tissue availability, technical difficulty in harvesting the flap and anatomical inconsistency has restricted its use to web space defects mostly. (2),(3).

Hence, Anterior interosseous artery perforator flap was selected as a first option to our cases, due to its versatility, ease of dissection, consistent perforator, reach to the defect with added advantage of single stage procedure, with similar skin color, texture, thickness and hair that of forearm(4)(5).

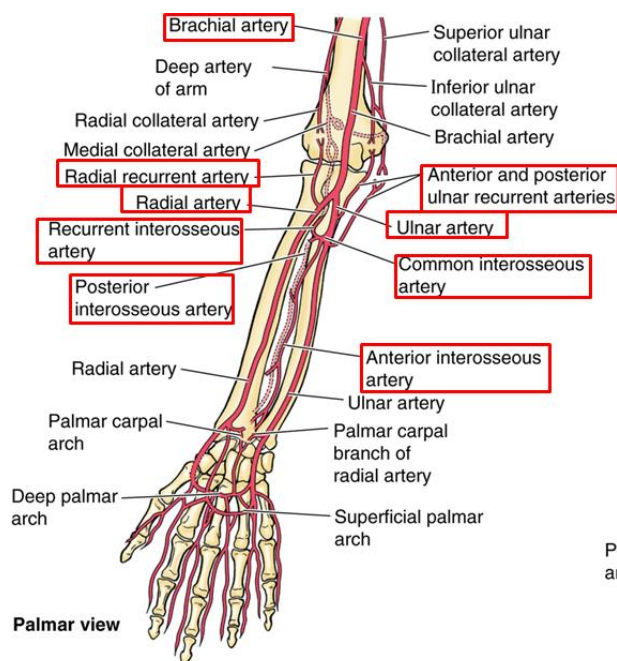
II. Methods

Since 2017 to 2018, in Department of Plastic Surgery, Government General Hospital, Siddhartha Medical College, Vijayawada, we have covered the wounds over volar aspect of distal forearm and dorsal surface of hand by using anterior interosseous artery perforator flap in 5 cases. Among these, three cases were due to electrocution, one was sequel of cellulitis following snake bite, and one was following trauma. The age group ranged from 18 years to 58 years. All were males, free from systemic diseases like Diabetes mellitus, Hypertension. The average size of the defect was 8 X 7 cms.

Anatomy:

Anterior interosseous artery is a branch of common interosseous artery, which in turn, is a branch of ulnar artery travels in volar aspect of forearm(6). Proximal to pronator quadratus, it gives a perforator that

pierces the interosseous membrane to enter into the dorsal surface in the fifth compartment between the extensor carpi ulnaris and extensor digiti minimi, divides into ascending and descending branches. Ascending branch supply the dorsal distal skin of fore arm and descending branch anastomoses with vascular network in and around wrist.



SURGICAL TECHNIQUE

Cases were done under General or Regional anesthesia, with tourniquet on, without emptying the limb. Patient in supine position, elbow flexed, a line is drawn from distal radio-ulnar joint to lateral epicondyle, the common axis both for posterior interosseous artery and anterior interosseous artery perforator. No Doppler was used to detect the perforator before surgery in any case. A trial 'exploratory incision' was made on the ulnar side 4-5 cms proximal to the distal radio-ulnar joint, which was deepened subfascially and overlying tissue lifted up to identify the perforator between the extensor digiti minimi and extensor digitorum tendons. After confirming the presence and position of the perforator, 'planning in reverse' was done from the defect, keeping 2cms proximal to the position of the perforator as 'pivot point'. Flap was harvested in subfascial plane till pivot point and transposed 180 degrees to the defect from radial side and sutured. In case of island flap, 'sperm shaped' flap was planned to include dog ear of the donor site and also the tail part to cover the intervening area between the donor site and recipient defect to avoid tension over the subcutaneous pedicle. Before transposition, tourniquet released, perfect haemostasis was achieved, and simultaneously, flap was perfused for a while to ensure its vascularity. Donor site reduced and left over raw area was covered with split thickness skin graft harvested from thigh. Position of the limb was kept in slightly in wrist extension with plaster cast and padding. Post operatively limb was kept elevated for one week to 10 days, flap was monitored by its color, warmth and bleeding on needle prick.

III. Results

All the flaps healed well. In one case there was a hematoma, which is drained by removing few stitches proximally. Edema was noted in island flap post operatively for one week, which was managed conservatively by limb elevation. Dog ear was small, when compared with any standard transposition flap of 180 degree rotation. The skin texture, color and hair match is similar on par with volar skin of contra lateral side. Donor morbidity is quiet noticeable, however, patient acceptance is better when compared with the given option of groin flap and its demerits.

CASE1

A 45 years male patient was referred from orthopedic ward, had a defect with exposed vital structures on the volar aspect of distal forearm of left upper limb following high voltage electrocution. The defect was measuring about 10X 8 cms after wound debridement. This defect was resurfaced with anterior interosseous artery perforator flap. Wound healed well.

CASE 4

A 58 years male patient had a raw area extending from distal arm to wrist joint of right upper limb, with exposed vital structures at the distal forearm, due to sequel of cellulitis following snake bite. Anterior interosseous artery perforator flap was used to cover the exposed vital structures at the distal forearm, and rest of the raw area including donor site was resurfaced with split thickness skin graft. Wound healed uneventfully.

CASE 5

An 18 years young boy had post traumatic injury with loss of skin over dorsum of left hand, with associated fracture 3rd meta carpal bone, severed extensor digitorum tendon. Fracture was fixed with plate and screws, tendon repair was done, following, an anterior interosseous artery perforator island flap was used to cover the defect. Final results of the well healed flap.

IV. Discussion

Reconstructive options available to resurface the classical defects of distal forearm and dorsal surface of hand are few. Among them, 'groin flap' is the gold standard before the era of microsurgery. Microsurgery demands technical expertise, skills, infrastructure, and often has long learning curve. Keeping the microsurgery aside where, it could not be considered, the groin flap has advantages like well hidden scar, thin skin, and consistent blood supply and tissue availability. However, as a direct distant pedicle flap, it is a two stage procedure. Hand should be restricted at least for two weeks, made this flap as second option, if you have given a choice to the patient. The other flaps from same limb are, axial vessel based flaps on radial artery, ulnar artery, posterior interosseous artery and or on their perforators with its distal pedicles can reach the defects of hand and distal forearm. Since both the main axial vessels are on volar aspect of forearm, hence their perforators-flaps based on them are not to be useful for the defects over distal forearm and wrist. Posterior interosseous artery is very reliable choice because as a distal flap, it reaches up to MP joints on the dorsal side, even to the thenar and hypothenar eminences on the volar side including the 1st web space. However, the position of the perforator is inconsistent, the tissue available is less, anatomical variability and dissection is tedious, its usage has been restricted to 1st web space at the most.

The anterior interosseous artery perforator flap is a flap based on the perforator originating from the anterior inter osseous artery, which pierces the interosseous membrane, enters into dorsal side approximately 4cms proximal to distal radio-ulnar joint. This perforator supplies to the dorsal forearm skin-hence it is very useful for the distal volar defects of forearm, which is the common site of tissue loss in high voltage electrocution injuries and similarly dorsum of hand which again another common site of tissue loss following snake bite cellulites sequel. These two are critical areas exposing vital structures like tendons, bones and joints with overlying skin loss and often throws challenge to reconstructive surgeon. In this scenario, anterior interosseous artery perforator flap is 'the choice' to be considered, if one would like to harvest flap from ipsilateral limb and to complete procedure in a single stage. The major advantage of the flap is the two axial vessels of the limb are spared. Anterior interosseous artery perforator is very consistent perforator and can be easily identified with exploratory incision. This was found in all of our cases. No Doppler was used to identify the perforator in any cases. However, prior use of Doppler to locate the perforator position is an added advantage, before planning and execution of this flap and its significance cannot be denied. Once the perforator has been identified, then flap harvestation is technically easy, by sub fascial plane dissection thus reducing operative time. The transposition movement of the flap from 90 to 180 degree, often results in large dog ear. However, due to natural advantage of narrowing of forearm has minimized the dog ear formation. The pedicle length of the flap is adequate enough to reach the distal forearm and hand and can also extended by dissecting the perforator up to interosseous membrane as mentioned by Martin,Hu,Shibata etal (7,8,9). Even though suprafascial flaps have been described by Nikhil Panse (6)etal based on this perforator, in our series we have not made any attempt to harvest the flap suprafascially. The dimension of the flap appears to be from lateral radial border to ulnar borders side to side, proximally 4-5 cms distal to elbow joint, distally 4 cms proximal to distal radio-ulnar joint. With these dimension, flap can cover wide variable defects of distal forearm, wrist, and proximal hand and also on the dorsum of hand, MP joints successfully. The procedure can be completed in a single stage. As an island flap on subcutaneous pedicle, the flap can be rotated 180 degrees with ease and can reach p to MP joints, 1st web space and even palmar surface of hand comfortably. These island flaps are useful when the defect demands multi tasks like, bone fixation, tendon repair, nerve repair together with skin resurfacing 'all in one go' as single stage procedure. In our series the complications are minimal as no flap necrosis was observed. Even though there is a concern about donor site morbidity on the dorsal surface of forearm, however, when we have explained merits and demerits of flaps of other options like groin flap, patients opted for anterior interosseous artery perforator flap as first choice, ignoring limb aesthetics. Literature is sparse about this flap and appears to be neglected. To our knowledge and experience, with all its merits, this anterior

interosseous artery perforator flap should be considered as ‘first choice’ for these typical common defects of forearm and hand described.

V. Conclusion

Our experience in five cases, anterior interosseous artery perforator flap is one of the excellent choices to be considered in the distal volar defects of forearm and hand dorsal side where other options like, distal ulnar artery perforator flaps, distal radial artery perforator flaps, posterior interosseous artery perforator flaps are futile. Even though groin flap is the option, due its two stage procedure and temporary immobility of the limb, this can be pushed to the second choice with rest of its demerits. No compulsion to do Doppler study to locate the perforator position. The location and presence of the perforator can be easily identified with a trial exploratory incision made on the ulnar side of the intermuscular septum axis, dissected subfascially in between extensor tendons. As a transposition flap it will reach to mid forearm, distal forearm, and wrist and as an island flap on subcutaneous pedicle, it will reach dorsum of hand up to MP joints, 1st web space, and proximal hand comfortably. The procedure can be completed in a single stage ‘all in one go’, with skin of similar color, texture, thickness and hair that of distal forearm. Complications like necrosis can be minimized or eliminated with gentle care while harvesting the flap and restricting the dissection 1cm proximal to pivot point.

References

- [1]. Ian A McGregor, Ian T Jackson. The groin flap. *Br J Plas Surg.* 1972; vol25: 3-16
- [2]. Liu DX, Wang H, Li XD, Du SX. Three kinds of forearm flaps for hand skin defects: experience of 65 cases. *Arch Orthop Trauma Surg.* 2011;131:675–80. [[PubMed](#)] [[Google Scholar](#)]
- [3]. Otene CI, Achebe JU, Ogbonnaya IS. The radial forearm flap in reconstruction of upper limb injuries: a case series. *J West Afr Coll Surg.* 2011;1:131–44. [[PMC free article](#)] [[PubMed](#)] [[Google Scholar](#)]
- [4]. Hora'cio Costa, Armindo Pinto, Hora'cio Zenha. The posterior interosseous flap e a prime technique in hand reconstruction The experience of 100 anatomical dissections and 102 clinical cases. *J Plast Reconstr Aesthet Surg.* 2007;60:740e747. [[PubMed](#)] [[Google Scholar](#)]
- [5]. Angrigiani C, Grilli D, Dominikow D, Zancolli EA. Posterior interosseous reverse forearm flap: experience with 80 consecutive cases. *Plast Reconstr Surg.* 1993;92:285e93. [[PubMed](#)] [[Google Scholar](#)]
- [6]. Nikhil S Panse, Sheetal B Joshi, Parag B Sahasrabudhe, B Bahetee, Pradnya Gurude, Ajay Chandanwale. The anterior interosseous artery perforator flap: Anatomical dissections and clinical study. *World J Plast Surg.* 2017;6(2): 152-158
- [7]. Martin D, Bakhach J, Casoli V, Pellisier P, Ciria-Llorens G, Khouri RK, Baudet J. Reconstruction of the hand with forearm island flaps. *Clin Plast Surg.* 1997;24:33–48. [[PubMed](#)] [[Google Scholar](#)]
- [8]. Hu W, Martin D, Foucher G, Baudet J. Le lambeau interosseux anterieur. *Ann Chir Plast Esthet.* 1994;39:290–300. [[PubMed](#)] [[Google Scholar](#)]
- [9]. Shibata M, Ogishyo N. Free flaps based on the anterior interosseous artery. *Plast Reconstr Surg.* 1996;97:746–55. [[PubMed](#)] [[Google Scholar](#)]

PICTURES

Case1.

Fig1.a.b.c.schematic pictures showing pre-operative defect over distal forearm. Harvested flap showing cutaneous branch of perforator. Early post-operative results with well settled flap.

Case1.fig.1 a.b.c

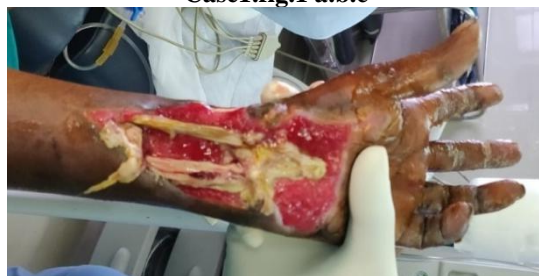

Fig2.

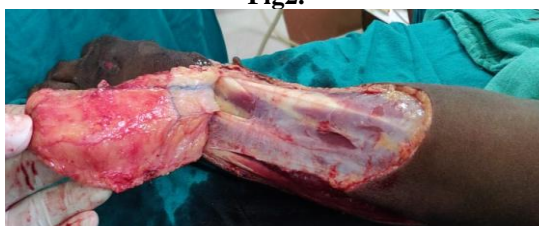
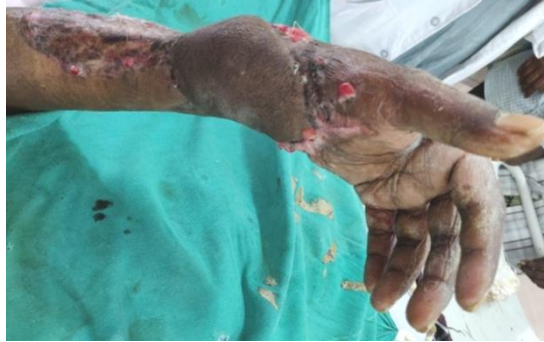
Fig 3.



Case2.Fig2.a.b.c. schematic pictures showing defect over upper limb with exposed vital structures. Harvested flap ready to transfer. Post operative results.

Fig.4

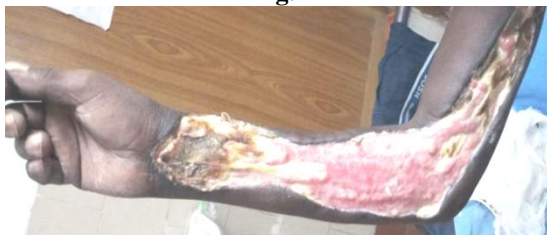

Fig.5

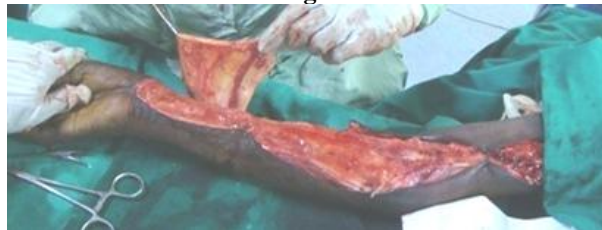
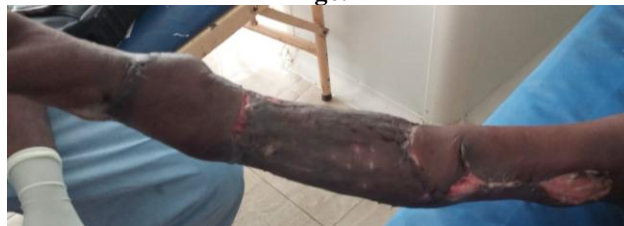
Fig6.



Case3.Fig3 A.b.c. schematic pictures showing dorsal hand defect. Anterior interosseous artery perforator island flap. Well healed flap.

Fig7

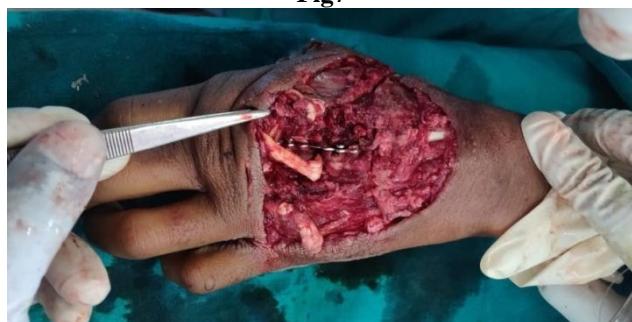

Fig8

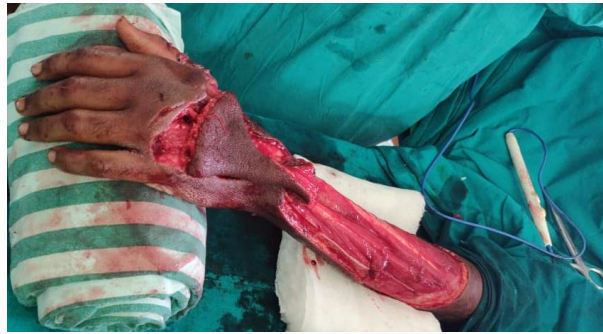
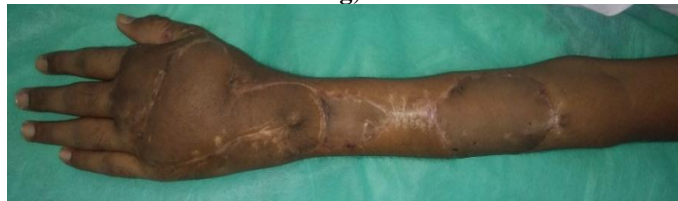
Fig.9



Dr.Jyostna Poldas. "Anterior Interosseous Artery Perforator Flap for Distal Forearm and Hand Defects." IOSR Journal of Dental and Medical Sciences (IOSR-JDMS), vol. 18, no. 4, 2019, pp 42-47.