

## Extra Isolated Port-Site Metastases after Laparoscopic Surgery of Endometrial Cancer: A Case Report and Review of Literature.

Nesrine Tounsi<sup>1</sup>, Maher Slimane<sup>1</sup>, Nawel Abdelwahed<sup>1</sup>, Olfa jaidanne<sup>1</sup>, Raoudha Doghri<sup>2</sup>, Bouzaine Hatem<sup>1</sup>, Khaled Rahel<sup>1</sup>.

<sup>1</sup> Department of surgery carcinologique, Salah-Azaiez institute, boulevard of 9-Avril, 1001 Tunis, Tunisia.

<sup>2</sup> Department of Pathology, Salah-Azaiez institute, boulevard of 9-Avril, 1001 Tunis, Tunisia.

Corresponding Author: Nesrine Tounsi

---

**Abstract:** Endometrial cancer has lately been increasingly treated by laparoscopic surgery. Although there's been a good technique to treat patients with endometrial cancer, port-site metastasis (PSM) is a possible complication.

In our article, we will present a case of a 65-year-old female diagnosed with single PSM following laparoscopic surgery for stage II grade II endometrioid endometrial cancer (EEC). The patient developed a recurrence within 12 months following the first surgery. A surgical excision followed by adjuvant chemo- radio therapy was realized. After 09 months, the patient remained disease - free.

In the literature, outcomes of patients with (PSM) were rarely described and there are no obvious risk factors for development of port-site metastasis or easily identifiable prevention. The purpose of this study is to bring a better knowledge of this mysterious complication.

**Keywords:** Endometrial cancer; Laparoscopy; Port-site metastasis.

---

Date of Submission: 27-03-2019

Date of acceptance: 12-04-2019

---

### I. Introduction

Over latest years, endometrial cancer has been increasingly treated by laparoscopic surgery. One of the known complications is Port-site metastases (PSMs) after a gynecologic oncology laparoscopic surgery [1].

The incidence among patients with early-stage endometrial cancer varies from 0.18% to 0.33% [2]. Only few cases of isolated PSM were reported.

Laparoscopy offers several benefits when compared with open laparotomy procedures: shorter recovery time, improved performance status following surgery, reduced pain and a decreased risk of adhesions [1]-[2].

The purpose of the present case study is: to describe a rare case of isolated port- site metastasis following laparoscopic surgical staging for EEC, to review the published cases of isolated PSMs after laparoscopic surgery for EEC, to describe factors responsible for this phenomenon and how to prevent it.

### II. Case Report

Our present case, a 65-year-old woman G4P4 who had been complaining of postmenopausal uterine bleeding for 8 months underwent hysteroscopy with endometrial biopsy in April 2016. The pathology report showed a well-differentiated endometrial adenocarcinoma grade II.

After clinical and radiological evaluation, the disease was confined to the uterus. It invading more than 50% of the myometrium and involving the stroma of the upper half of the cervix. The Patient underwent a laparoscopic surgical staging consisting in radical hysterectomy with bilateral salpingo-oophorectomy and pelvic lymphadenectomy. The surgical procedure started with uterine manipulator placement. Pneumoperitoneum was created using a Veress needle with a maximum intra-abdominal pressure of 12 mm Hg. The standard 12- and 10-mm midline ports and two 5-mm lateral ports were used. Both fallopian tubes were coagulated at the beginning of the operation to prevent tumor cell spread to the peritoneal cavity. The entire specimen (the uterus, fallopian tubes, ovaries and nodes) were removed on bloc through the vagina using a protective bag. The trocars were removed after desufflating through the umbilical port and. A surgical drain through the left lateral port was left in situ for 24 h. No complications occurred during and after the operation.

The histopathological diagnosis was endometrial adenocarcinoma; Grade 2; 50% myometrial invasion into the outer half of the myometrium; cervical stromal involvement. Surgical margins were tumor-free. A total of 12 pelvic lymph nodes were sampled, which were negative of metastasis. Peritoneal lavage was negative. The

patient obtained a FIGO (2009) stage II. A recommendation of external beam while pelvic radiation and brachytherapy was indicated for this patient.

The patient was evaluated every 3 months.

She remained without evidence of disease until her 12-month follow-up. During the routine clinical examination, two well-palpated and tender nodules each about 4 cm in size, were found on her anterior abdominal wall. One in the right and the second in the left lower quadrant, it was corresponding of the sites of the 5 mm trocars. Abdominal pelvic scanner revealed two highly vascularized nodules localized in front of the anterior fascia, the largest one measuring 40 mm and the second measuring 30 mm (Figure.1). Except that, there was no evidence of local abdominal or pelvic recurrence.

The patient underwent surgery. No peritoneal carcinomatosis was observed during the laparotomy exploration; the abdominal metastatic lesion with the corresponding fascia and skin was removed (Figure.2).

The fascia defect was repaired with a synthetic and non-absorbable polypropylene mesh. The pathology report revealed a metastatic endometrioid Grade II tumor (Figure.3).

The patient had six rounds of adjuvant chemotherapy with carboplatin, taxol and external radiation therapy of the area of excision. Nine months after the patient had no evidence of tumor recurrence.

### **III. Discussion**

The first case of PSM after laparoscopic surgery for endometrial cancer (EC) was reported in 1997 [1].

After this, PSM following laparoscopy has been reported in gastrointestinal, biliary malignancies, peritoneal carcinomatosis, gallbladder cancer, gynecologic malignancies and hepatocellular carcinoma [3] - [4]-[5].

Port-site metastases were defined as a tumor growth at one or more areas from prior laparoscopic trocars. This could be an isolated finding which by definition means the recurrence occurs at one or more port-site without evidence of other tissues involved at the time of diagnosis [3].

Prospective results of the Gynecologic Oncology Group 2222 trial reported that the risk to develop PSM after laparoscopic surgical for endometrial cancer, was 4 (0.24%) of 1696 patients [2].

The most reported case of PSM following laparoscopic surgical of endometrial cancer was associated with concomitant distant metastases. However, only few cases of isolated PSM were reported [1]-[2]-[3]-[4]-[5]-[6]-[7] - [8] - [9] (table 1) and they present a complex management and prognostic scenario for which few data exist [3].

A recent review by Douglas Grant [2] reported seven patients with endometrial cancer who developed isolated port-site metastases and were treated with radiation therapy (RT) at MD Anderson Cancer Center, this review showed that (RT) could improve outcome.

PSMs are also reported after robotic surgery in women with gynecological cancer. Their incidence was 1.9% [3]. Only four isolated PSM following robotic surgery for endometrial cancer was reported [2]-[4] - [10].

At the moment, no conclusions can be drawn for advantages of robotic surgery compared with laparoscopic surgery regarding port-site metastasis [3].

The pathophysiology of PSM is not well apprehended. Many influencing factors could increase the transition of tumor cells and may be the main cause of their development: hematogenous spread diminished immune response, the pressure of the pneumoperitoneum and CO<sub>2</sub>, direct contamination by instruments and advanced stage of disease [1]-[2].

In accordance with the literature, surgeons to prevent development of PSM elaborated many measures. Preoperative measures such: proper patient selection, avoiding laparoscopy use if ascites was present, adequate equipment for laparoscopy surgery and well trained surgeon was necessary. Technical measure like resection without rupture and with adequate margin, minimal tumor manipulation, peritoneal lavage with heparin, use of protective bags, exsufflation of the peritoneum before removal of the ports, irrigation ports with heparin, fallopian tube occlusion, and even port-site resection [1]-[2].

The prognostic impact of PSMs was not well known at present and remains controversial. It was not clear, if PSMs should be considered a local or systemic recurrence [1]. In the report of Ataseven et al, PSM did not seem to have a negative prognostic impact on overall survival of epithelial ovarian cancer [11].

The gold-standard treatment has not been established. In the majority of cases, combined approach with surgery, chemotherapy and radiotherapy has been achieved [1]. Outcomes in patients with PSM whose were treated by surgery and radiotherapy of the area of PSM were generally favorable [2].

In our case, isolated PSM recurrence occurred 12 months after laparoscopic surgery. There has been no recurrence at the vaginal stump, no at 10-mm trocar site and no dissemination in the peritoneal cavity. Treatment consisted in a wide resection followed by chemotherapy and radiotherapy of the area of excision. Nine months after completion of chemotherapy and radiation, the patient had no evidence of tumor recurrence.

#### IV. Conclusion

The etiology of port-site metastases is still unclear, and probably it is a multifactorial phenomenon. Our experience indicates that isolated PSM is not necessarily a harbinger of aggressive disseminated disease. We recommend including control of ports site trocar in oncologic surveillance after laparoscopic surgery.

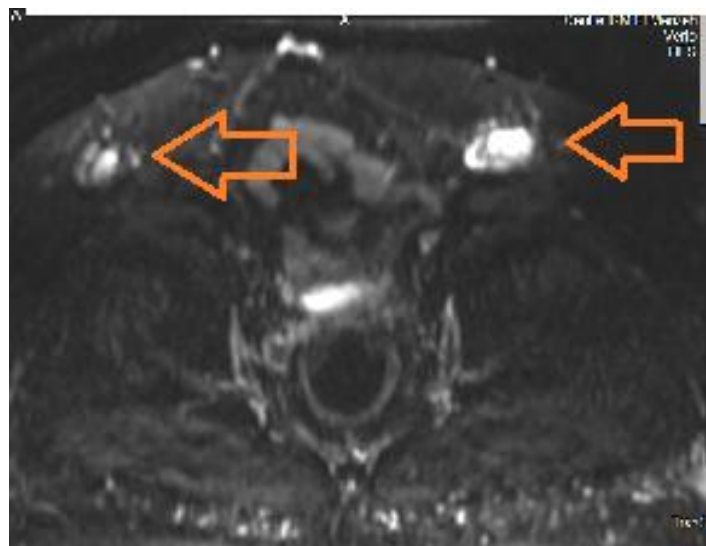
The etiology of PSM is not yet understood; many factors could contribute. All efforts should be made to prevent port site metastases and surgeons should rigorously adhere to the principles of oncological surgery.

**TABLE (1): Characteristics of cases of isolated port-site metastases.**

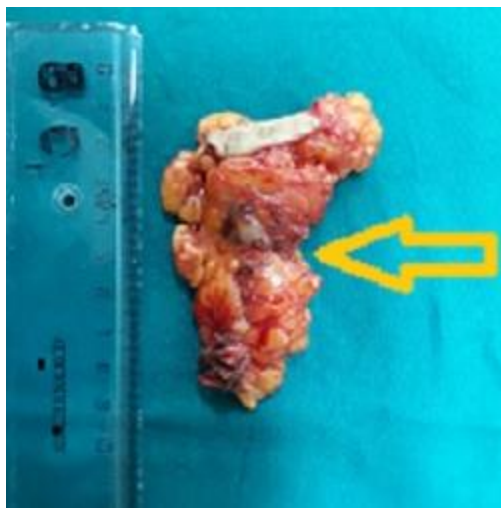
Authors	Age (y)	Disease	FIGO stage	Surgery	Ports (no)	Preventions strategies	Adjuvant Therapy	Time from surgery (mo)	Location	Concomitant metastasis	Treatment	Survival outcomes
Faught (1999) (6)	84	G2 EAC	IC	LAVH / LPL PC	4	Fascia suture of 10 mm ports	EBRT	7	10 mm left lateral and right (extraction ports)	NA	HT and palliative local RT	Died of disease after 5 months.
Muntz (1999) (7)	58	G2 EAC	IA	LAVH/BSO LPL PC	4	No uterine manipulation Fascia suture of 10 mm ports	No	21	5 mm left lateral	-	Excision Laparoscopic restaging EBRT	DFS 30 months
Sanjuan (2005) (8)	55	G2 EAC	IIB	LAVH / BSO LPL	5	Extraction bag Trocar site irrigation (water) Peritoneum suture of the 10–12 mm ports	EBRT	48	5 mm right lateral Lower	-	Excision Local RT CT	NA
Palomba (2012) (9)	66	G2 EAC	IB	LAVH / BSO LPL	4	Tubal coagulation Extraction bag Trocar site irrigation (5% polyvidone iodine) Fascia suture of 10 mm ports	EBRT BT	24	10 mm left lateral (not extraction PS)	-	Excision Laparoscopic restaging Local RT CT	DFS 10 months.
Grabosch (2013) (10)	56	G1 EAC	IA	robot-assisted TH+BSO+LPL	NA	NA	NO	10	right lateral	NO	Excisions+ CT+RT	DFS 13months
	54	G2 EAC	IA	robot-assisted TH+BSO+LPL	NA	uterine perforation		36	left lateral		Excisions+ CT+RT	DFS 4months
Leonferro (2013) (11)	68	Carcinoma	IB	Robotic TLH+BSO LPAL	NA		CT	9	Optic trocar	NO		
Grant et al (2015) (2)	54	EAC G3	IIIA	TLH/BSO with LND	NA		Pelvic and VC RT	18	Left flank	NO	RT+CT	DFS 7.6y

	64	Endometrioid G1	II	TLH/BSO			Pelvic and VC RT+CT	15	Right lower abdomen		Excision+RT+CT	DFS 2.2y
	63	Endometrioid G1	IA	TLH/BSO			None	10	Left rectus abdomens		Excision+RT	DFS 0.6y
	45	Endometrioid G2	IA	TLH/BSO			None	44	Right anterior abdomen		Excision+RT	DFS 1.42y
	60	Endometrioid G2	IA	TLH/BSO with LND			Pelvic and VC RT	12	Left anterior abdomen		Excision+RT	DFS 1.5y
	81	Endometrioid G2	IB	TLH/BSO with LND			VC RT+CT	36	Right anterior abdomen		Excision+RT	DFS 0.3y
	73	Serous G3	IA	TLH/BSO LND (robot-assist)			None	15	Left anterior abdomen		Excision+RT	DFS 1.83y
		Serous G3					CT		Right abdomen (3 PSM)		Excision+RT+HT	
Barraez (2015)(4)	53	EEC G1	IIIA	TLH/BSO LND	5	Extraction bag Trocar site irrigation (normal saline)	No	94	Left and right	NO	NA	NA
	67	EEC G2	IB	TLH/BSO	5		RT	48		NO		
MAUTONE (2016) (1)	57	EEC G1	IA	TLH/BSO	4	No protection bag	No adjuvant Therapy	7	Left and right	NO	Excision+RT+CT	DFS 9m
Present case(2016)	65	EEC G2	II	TLH/BSO LND	4	Protection bag	EBRT BT		Left and right		Excision+RT+CT	DFS 9 Months

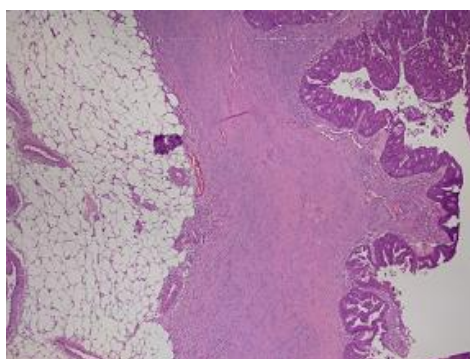
FIGO International Federation of Gynecology and Obstetrics; G=grade; AC= adenocarcinoma; BSO=bilateral salpingo-oophorectomy; BT=brachytherapy;CT=chemotherapy;EAC=endometrioid adenocarcinoma; EBRT=external beam radiotherapy; HT=hormonotherapy; LP=laparoscopic ports; LPAL=laparoscopic pelvic and paraortic lymphadenectomy;LPL=laparoscopic pelvic lymphadenectomy; LAVH=laparoscopic assisted vaginal hysterectomy; NA=not availableal ; PC=peritoneal cytology; PS=port site; RT=radiotherapy;TLH=total laparoscopic hysterectomy; DFS:disease-free survival .



**Figure 1:** MRI of the abdomen showing two well nodule on her anterio abdominal wall on the right and left.



**Figure 2:** Photograph of the right anterior abdominal wall specimen showing a well-defined pearl-white lesion below the skin.



**Figure 3:** Histological view of the port-site metastasis.

### References

- [1] Mautone D, Dall'asta A, Monica M, Galli L, Capozzi VA, Marchesi F *et al* "Isolated port-site metastasis after surgical staging for low-risk endometrioid endometrial cancer: A case report". *Oncol Lett* 2016 Jul; 12 (1):281-84.
- [2] Grant JD, Garg AK, Gopal R, Soliman PT, Jhingran A, Eifel PJ *et al* "Isolated Port-Site Metastases After Minimally Invasive Hysterectomy for Endometrial Cancer: Outcomes of Patients Treated With Radiotherapy". *Int J Gynecol Cancer* 2015 Jun; 25(5):869-74.
- [3] Barraez D, Godoy H, McElrath T, Kredentser D, Timmins P. "Low incidence of port-site metastasis after robotic assisted surgery for endometrial cancer staging: descriptive analysis". *J Robot Surg*. 2015 Mar; 9(1):91-5.
- [4] Grabosch S and Xynos F "Isolated port-site metastasis after robotic hysterectomy for stage IA endometrial adenocarcinoma". *Obstet Gynecol*. 2013 Aug; 122(2 Pt 2):437-9.
- [5] Kihara K, Endo K, Suzuki K, Nakamura S, Sawata T, Shimizu T *et al* "Isolated port-site metastasis of hepatocellular carcinoma after laparoscopic liver resection". *Asian J Endosc Surg*. 2017 May; 10(2):191-193.
- [6] Faught W, Fung Kee FM "Port site recurrences following laparoscopically managed early stage endometrial cancer. *Int J Gynecol Cancer*". 1999 May;9(3):256-258.
- [7] Muntz HG, Goff BA, Madsen BL, Yon JL. "Port-site recurrence after laparoscopic surgery for endometrial carcinoma. *Obstet Gynecol*". 1999 May; 93(5 Pt 2):807-9.
- [8] Sanjuán A, Hernández S, Pahisa J, Ayuso JR, Torné A, Martínez Román S *et al*. "Port-site metastasis after laparoscopic surgery for endometrial carcinoma: Two case reports". *Gynecol Oncol*. 2005 Feb; 96(2):539-42.
- [9] Palomba S, Falbo A, Oppedisano R, Russo T and Zullo F "Isolated port-site metastasis after laparoscopic surgery for endometrial cancer: A case report. *Gynecol Oncol Case Rep*. 2011 Dec 2; 2(1):16-7.
- [10] Lönnerfors C, Bossmar T and Persson J "Port-site metastases following robot-assisted laparoscopic surgery for gynecological malignancies". *Acta Obstet Gynecol Scand*. 2013 Dec; 92(12):1361-8.
- [11] Ataseven B, Grimm C, Harter P, Heikaus S, Heitz F, Traut A *et al* "Prognostic Impact of Port-Site Metastasis After Diagnostic Laparoscopy for Epithelial Ovarian Cancer" *Ann Surg Oncol*. 2016 Dec; 23:834-40.

Nesrine Tounsi. "Extra Isolated Port-Site Metastases after Laparoscopic Surgery of Endometrial Cancer: A Case Report and Review of Literature." *IOSR Journal of Dental and Medical Sciences (IOSR-JDMS)*, vol. 18, no. 4, 2019, pp 72-76.