

## Mini-Implants in Pediatric Dentistry

Dr. Shalini Dixit<sup>1</sup>, Dr. Binita Srivastava<sup>2</sup>, Dr. Nidhi Gupta<sup>3</sup>,

Dr. Natasha Gambhir<sup>4</sup>, Dr. Rashi Singh<sup>5</sup>

<sup>1</sup>PG student, <sup>2</sup>Prof&HOD, <sup>3,4</sup>Reader, <sup>5</sup>Senior Lecturer

Department of Pedodontics and Preventive Dentistry, Santosh Dental College and Hospital, Ghaziabad, Delhi  
NCR

Corresponding Author: Dr. Shalini Dixit

---

Date of Submission: 27-03-2019

Date of acceptance: 12-04-2019

---

### INTRODUCTION

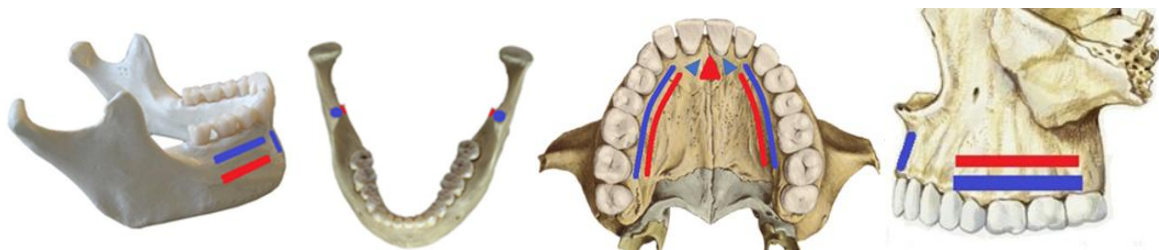
Mini implants have become the evolutionary change in the phase of implant placement. Unlike dental implants where multiple visits become hassles for patients, mini implants eliminate the need for surgery and multiple appointments. The most common use for mini dental implant is the stabilization of overdenture and orthodontic treatments but now they are also used in pediatric dentistry for congenitally missing teeth and tooth loss due to trauma. Dental prosthesis helps in conventional oral rehabilitation of patients with anterior tooth loss. Mini implant is a temporary anchorage device, constitutes of pure titanium or titanium alloy as they are biocompatible and highly inert.<sup>5</sup>

### CONFIGURATION OF MINI DENTAL IMPLANT

Mini dental implants are an alternative to traditional dental implants but are generally used in situations where the amount of space is less and small size implant can be placed. Teeth which are smaller in size like incisors, become the favourable candidates for mini dental implants. The design and structure of it promotes quick healing and long lasting results. The head portion of mini implant look very much like a ball, this ball helps in the retaining mechanism. Together these structures hold the teeth at designated overjet and overbite.

### SELECTION OF THE INSERTION SITE<sup>10</sup>

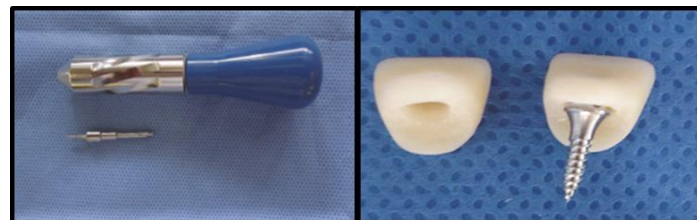
When choosing a site for the placement of an orthodontic mini-implant, the clinician should consider the certain factors like - Fail-safe areas: Areas in which there is potential for irreversible injuries to important anatomic structures are high should be avoided. Accessibility: It allows proper surgical procedures and provides adequate stability. Hard tissue conditions (quality and quantity of cortical bone): The cortical bone must be thick enough to provide sufficient stability (mechanical stabilization immediately after implantation). Attached gingiva should be in good condition for soft tissue sealing. Usability: An implant should be placed in a biomechanically favorable position to allow application of the necessary orthodontic force. Discomfort: Implants should be placed in areas that result in minimal discomfort for the patient. Selection of an implantation site in maxilla and mandible, the safe zones are indicated in blue, while the danger zones are indicated in red.



SITE SELECTION -  SAFE ZONE  DANGER ZONE

**METHODOLOGY**

Important factors to be considered when treating a child with missing tooth, apart from growth, are dentition present, residual space between the teeth present in the arch, amount of alveolar bone, and the timing of implant placement. Treatment planning should be done with study models and radiographs. Mini-implants should be selected according to the site and preparation of temporary crowns should be done. A mild anesthetic is administered in the tissues at the site. A self-tapping and self-drilling mini dental implant is chosen, made of titanium alloy with correct dimensions selected. A small hole is drilled in the bone to situate each mini implant at its assigned location. The implant is screwed at its assigned place and tightened with a winged wrench. The insertion of the implants will be transmucosal at occluso- gingival position. Acrylic resin is used in order to resemble the characteristics of the lost tooth to adapt to the remaining gum line configuration. The provisional crowns act as space maintainer and takes up the final retention. It was important to ensure that the transmucosal profile region remained completely free of any hindrance.



The final coupling was done with the partial filling of the cavity by almost 1mm below the alveolar ridge with acrylic resin which was still in plastic phase, to allow mechanical inter locking between the crowns and heads of mini-implants after setting time. In almost all cases, no suturing is required and no discomfort is felt after the procedure. After this step, occlusal adjustment was done in order to encourage physiological contacts in maximum inter cuspation and eccentric movements.

**SIZES:**

DIAMETER	HEIGHT
1.4mm	6 mm,8mm,10mm
1.6mm	6mm,8mm,10mm,12mm
2.0mm	6mm,8mm,10mm,12mm

**ADVANTAGES**

- True innovations for children who are reluctant to have dental surgery.
- Biocompatible
- It minimizes the cost for treatment
- Easier cleaning
- No cutting or sutures required

**DISCUSSION**

The prevalence of trauma in anterior is observed mainly in the age group 6–17 years old ranges between 4% and 37.9%. Among the resulting injuries, avulsion of permanent teeth occurs in approximately 16% of the cases, and the most affected teeth are the maxillary incisors.<sup>4</sup> Mini implant can be recommended in these types of cases because it restores function, aesthetic, reduces the psychological trauma.<sup>6</sup> Unlike conventional dental implants that behave as ankylosed teeth interfering with bone growth,<sup>7</sup> mini-implants without surface treatment present minimum Osseo integration.

**CONCLUSION**

Mini-implant is becoming promising alternative to crown anchorage in the anterior region, especially in oral rehabilitation of patients under development due to its simple ways to use, versatility and great biocompatibility. Despite limitations; it is a simple, single appointment and superior technically. As it provides good aesthetic and functional results which improves the patient’s quality of life, social integration and increases the self-esteem.

### Bibliography

- [1]. C. M. Viegas, S. M. Paiva, A. C. Carvalho, A. C. Scarpelli, F.M. Ferreira, and I. A. Pordeus, "Influence of traumatic dental injury on quality of life of Brazilian preschool children and their families," *Dental Traumatology*, vol. 30, no. 5, pp. 338–347, 2014.
- [2]. Agarwal N, Kumar D, Anand A, Bahetwar SK. Dental implants in children: A multidisciplinary perspective for long-term success. *Natl J Maxillofac Surg* Volume 7 | Issue 2 | July-December 2016.
- [3]. S. Lin, O. Zuckerman, Z. Fuss, and M. Ashkenazi, "New emphasis in the treatment of dental trauma: Avulsion and luxation," *Dental Traumatology*, vol. 23, no. 5, pp. 297–303, 2007.
- [4]. D. Brüllmann, R. K. Schulze, and B. d'Hoedt, "The treatment of anterior dental," *Deutsches " Arzteblatt International*, vol. 108, no.34-35, pp. 565–570, 2010.
- [5]. E.-J. Oh, T.-D. T. Nguyen, S.-Y. Lee, Y.-M. Jeon, T.-S. Bae, and J.-G. Kim, "Enhanced compatibility and initial stability of Ti6Al4V alloy orthodontic miniscrews subjected to anodization, Cyclic precalcification, And heat treatment," *Korean Journal of Orthodontics*, vol. 44, no. 5, pp. 246–253, 2014.
- [6]. Y.-S. Shin, H.-W. Ahn, Y.-G. Park et al., "Effects of predrilling on the osseointegration potential of mini-implants," *Angle Orthodontist*, vol. 82, no. 6, pp. 1008–1013, 2012.
- [7]. E. Rossi and J. O. Andreasen, "Maxillary bone growth and implant positioning in a young patient: a case report," *Int J Periodontics Restorative Dent.*, vol. 23, no. 2, pp. 113–119, 2003.
- [8]. D. Brüllmann, R. K. Schulze, and B. d'Hoedt, "The treatment of anterior dental," *Deutsches " Arzteblatt International*, vol. 108, no.34-35, pp. 565–570, 2010.
- [9]. S. Kiran, S. D. Bargale, S. Sikligar, and S. L. Shanthraj, "Bizarre cause for avulsion of permanent maxillary lateral incisor tooth," *BMJ Case Reports*, Article ID 010143, 2013.
- [10]. Jong Suk Lee, Jung Kook Kim ,Young-Chel Park ,Robert L Vanarsdall, Jr:Applications of Orthodontic Mini-Implants, *TREATMENT PLANNING(ch4)* Quintessence Publishing Co, Inc pg. 53-54