

Management of Transmigrated and Transposed Mandibular Canines- A Case Report

Neeteesh K Shukla¹, Vipul K Sharma², TP Chaturvedi³

¹(MDS student at Department of Orthodontics and Dentofacial Orthopaedics, Faculty of Dental Sciences/Banaras Hindu University, India)

²(Assistant professor at Department of Orthodontics and Dentofacial Orthopaedics, Faculty of Dental Sciences/Banaras Hindu University, India)

³(Professor at Department of Orthodontics and Dentofacial Orthopaedics, Faculty of Dental Sciences/Banaras Hindu University, India)

Corresponding Author: Neeteesh K Shukla

Abstract: Transmigration is a rare intraosseous migratory phenomenon related almost exclusively to mandibular canine. Transposition is a rare condition present in mandible but commonly encountered in maxillary arch. There are number of treatment options for these ectopic situations depend upon variety of case presentations, severity and presence of related pathologies. In this case report a 16 year old male patient presented with transmigrated 43 and transposed 33 along with retained 73 and 83. Arches were in class I molar relation. There was absence of any other related pathology. Fixed orthodontics treatment mechanics was considered as a treatment option. There was utilization of preadjusted edgewise appliance (MBT 0.022X0.028") for fixed orthodontic treatment. A well planned treatment biomechanics was followed for traction of ectopic canines to their respective positions. After around 22 months of full treatment, appliance was debonded and retainers were delivered. Patient kept on follow-ups and shows good prognosis.

Keywords: Transmigration, Transposition, Mandibular canine, Orthodontics, Preadjusted edgewise.

Date of Submission: 07-05-2019

Date of acceptance: 23-05-2019

I. Introduction

There can be three important ectopic situations related to canine those are most commonly encountered in orthodontic clinic - impacted, transposed, and transmigrated canine. A canine is defined as being impacted if it was unerupted after complete root development or if the contralateral tooth was erupted for at least 6 months with complete root formation.⁽¹⁾ Maxillary canine impaction is more commonly encountered than mandibular canine impaction. Maxillary canines are the second most frequently impacted teeth after the third molars, with a prevalence ranging from 0.9 to 5 per cent.⁽²⁾ There are different treatment strategies for impacted maxillary canines, ranging from interceptive approaches (extraction of deciduous canine at earlier age around 12 yr) to guided forced eruption or extraction and orthodontic space closure.⁽³⁾

Transposition of canine: A transposition is an exchange of position of two adjacent teeth, especially of their roots. It could also be the eruption of a tooth into a position usually occupied by a non-adjacent tooth.⁽⁴⁾ Complete transposition is the situation where both crowns and roots changed their position while in incomplete transposition where only the crown is transposed.⁽⁵⁾ The incidence of tooth transposition varies from 0.09% to 1.4%.^(6,7) Tooth transposition in mandibular arch is a rare condition and most commonly involve the transposition between canine and lateral incisor while In the maxilla the canine is transposed most frequently with the first premolar, less often with the lateral incisor and rarely with the other teeth.⁽⁴⁾

Transmigration of canine: Ando *et al.* coined the term 'transmigration' for this rare intraosseous migration phenomenon of unerupted teeth across the midline.^(8,9) Dental transmigration is almost exclusively reported in mandible. The prevalence is ranging from 0.8–3.6%.^(10,11) Mupparapu classified transmigrated mandibular canines into five types.⁽¹²⁾ : **Type 1:** Mesioangularly impacted canine across the midline with only crown portion crossing the midline. **Type 2:** Horizontally impacted canine near the lower border of the mandible below the root apices of the incisors. **Type 3:** Canine present either mesially or distally to the opposite canine. **Type 4:** Horizontally impacted canine near the lower border of the mandible below the root apices of the premolars or molars on the opposite side. **Type 5:** Canine positioned vertically in the middle with the long axis of the tooth crossing the midline

II. Case report

A 16-years-old male patient was reported to the orthodontics department, with the chief complaint of irregularly presence of two extra teeth in front of lower jaw and chief concern was aesthetic. Intraoral clinical examination revealed that he had all his permanent dentition in which right and left lower canine (43 and 33) were ectopic and partially erupted. Deciduous canines (73 and 83) were retained (figure 1). His medical and dental history was non-contributory. Routine orthodontic diagnostic procedures were carried out including cast analysis, panoramic radiograph, and lateral cephalogram. On orthopantomogram examination Right mandibular canine was classified as *type 1 transmigration according to Mupparapu classification* (Canine impacted mesioangularly across the midline, labial, or lingual to the anterior teeth with crown portion of tooth crossing the midline) and *Left mandibular canine was completely transposed with left lateral incisor*. Both the canines were healthy with complete formation of root. Roots of retained deciduous canines were resorbed around more than half of their total root length. There was absence of any other related pathology. Cephalometrically patient was having Class I sagittal skeletal jaw relation with convex profile and average growing along with dental Class I molar relation on right and left side with dental protrusion. There was presence of Protruded upper and lower lip and acute nasolabial angle (figure 2).

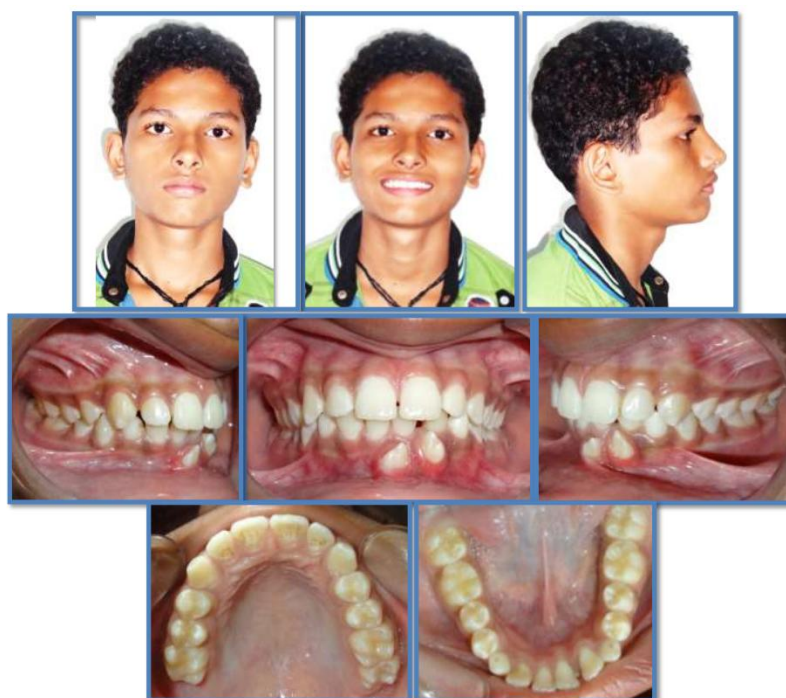

Figure 1- pre-treatment extraoral and intraoral photographs

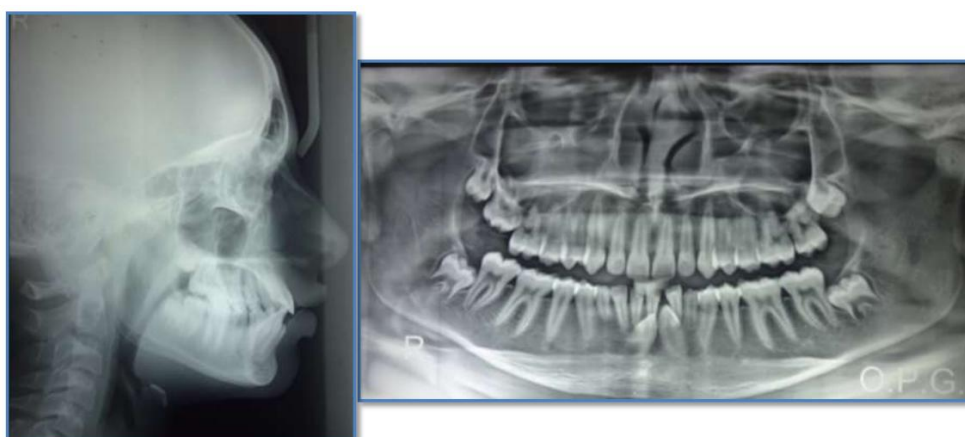

Figure 2- pre-treatment radiographs- lateral cephalogram and orthopantomogram

Treatment options

There are several treatment options proposed for impacted mandibular canines including surgical removal, exposure and orthodontic alignment, transplantation, and observation.⁽¹³⁾ If adequate space for alignment of an ectopic canine exists and it is mechanically possible to reposition that involved canine into proper position, then orthodontic treatment is indicated.

Treatment plan

Due to more than half of the root of deciduous canines was resorbed and presence of mobility on clinical examination were not in favour of long term prognosis, thus extraction of deciduous canines was planned and option like surgical removal of permanent canines was dropped. According to cast analysis adequate space was available for the proper alignment of both the ectopic canines. Transplantation of permanent canine to their respective position may possess uncertain prognosis so fixed orthodontic treatment was considered as final treatment plan.

Treatment progress (figure 3a, 3b, 4, 5, and 6)

Pre-adjusted orthodontic appliance (MBT prescription 0.022"×0.028"slot) was considered for bonding to the maxillary and mandibular teeth. Treatment was started by bonding MBT brackets on both the lower ectopic canines and open coil spring was inserted to attain favourable distal tipping of both the right and left canine to achieve proper angulation. Lip-bumper was installed to prevent soft tissue irritation. After 4 months of treatment, TADs (temporary anchorage devices) were inserted mesial to first premolar root on both right and left side for retraction of ectopic canines upto the location where T loop can be utilized for controlled retraction of canines. After 7 months of treatment, left deciduous canines were extracted and bonding was done in all mandibular teeth mesial to first molars except 41, 42, and 83. 33 was directly included in the main arch wire (SE NiTi 0.016"). Segmental T loop was installed for the retraction of 43 utilizing anchorage of 46. 83 were extracted later and rest of the teeth of lower and upper arch were also bonded subsequently. After around 15 months of treatment full retraction of right canine were achieved. T loop was removed and 43 was also included in the main arch wire (SE NiTi 0.018"). Residual space closure was done using working arch wire (SS 0.019x0.025"). Stainless steel 0.021"×0.025" wire was used as a stabilizing arch wire. Appliance was debonded after around 22 months of treatment. Upper and lower essix retainers were given for retention purpose and patient kept on regular follow-ups. No further gingival recession or root resorption were noticed during follow-up visits.

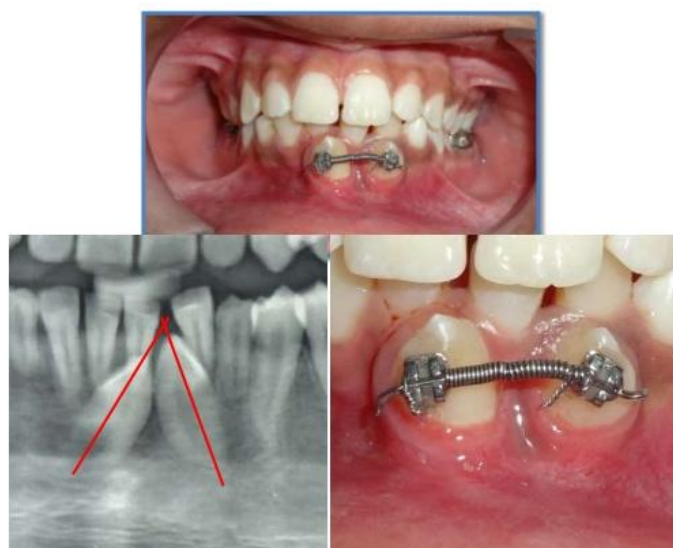

Figure 3a- treatment progress photographs: uprighting of canines by reciprocal action of open coil spring

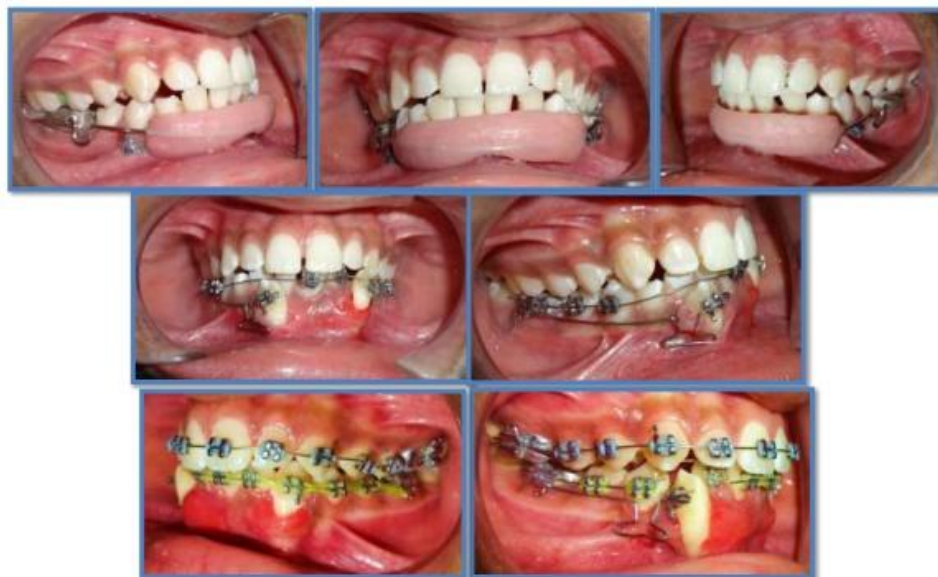

Figure 3b- treatment progress photographs: lipbumper to prevent soft tissue irritation and utilization of T loop for retraction of 43.

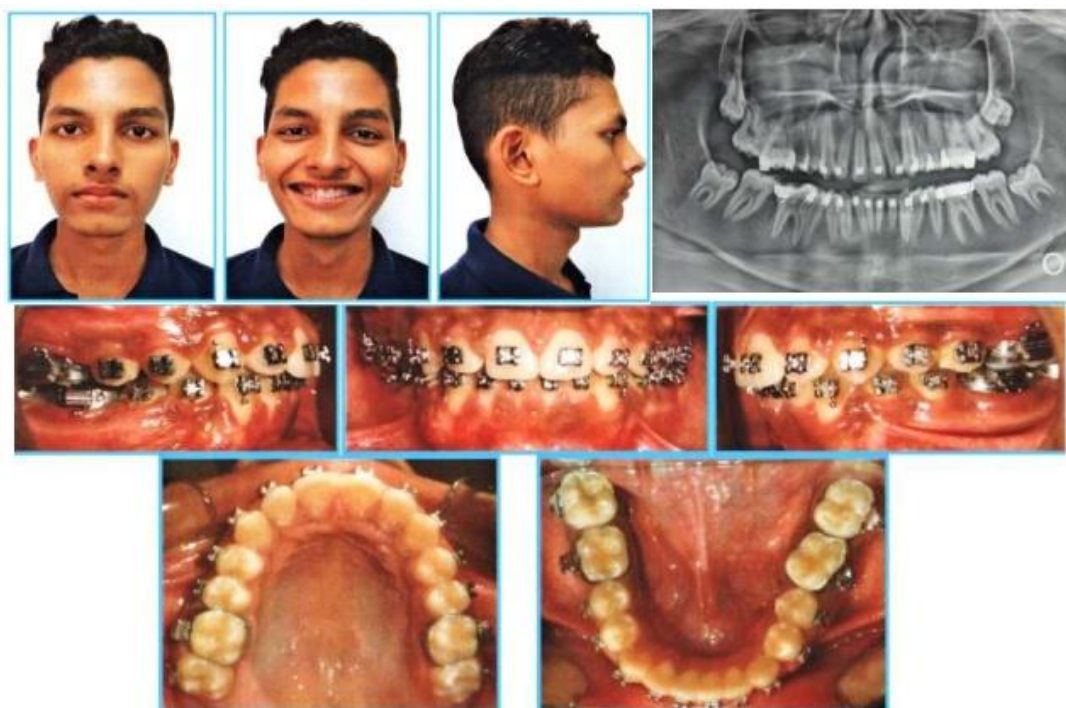


Figure 4- stage treatment extraoral and intraoral photographs and orthopantomogram

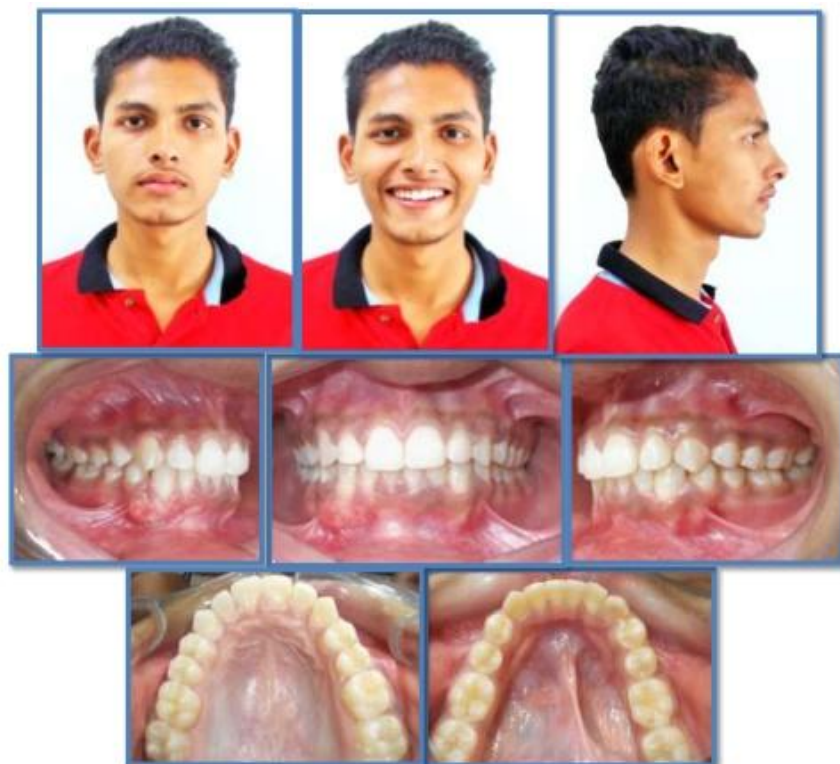

Figure 5- post-treatment extraoral and intraoral photographs

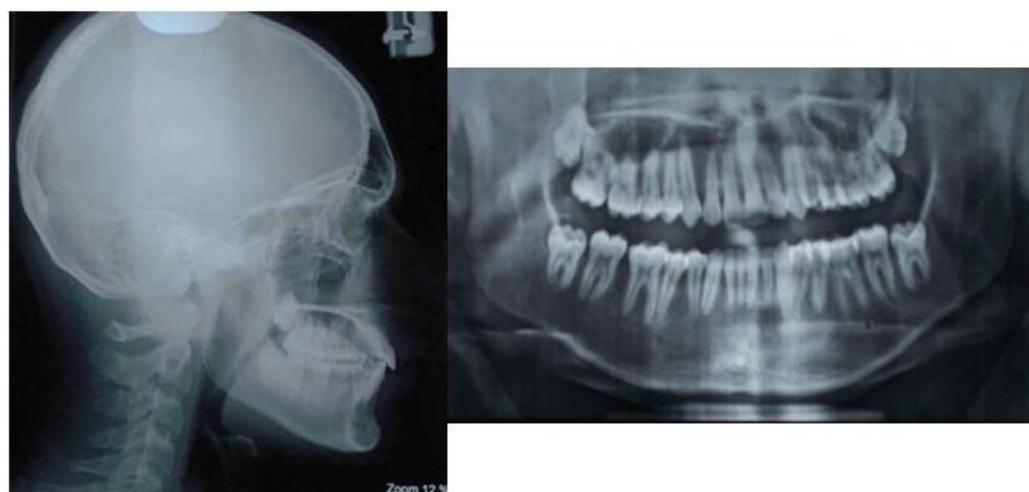


Figure 6- post-treatment radiographs

III. Discussion

This cases provide further evidence that transmigration of the mandibular canine is associated with an increased prevalence of other inherited dental anomalies, supporting Peck's opinion that the etiology of ectopic mandibular canines is genetic.⁽⁴⁾ It is believe that symptomless, unerupted teeth can be left in place for observation that include successive radiographic examinations for any progressive worsening of the position or pathological changes of the follicle like cystic transformation. These changes may lead the clinician to consider the possibility of surgical extraction. Periapical changes, periodontal problems, possible foci for the spread of infection, pressure resorption and malposition of adjacent teeth are the other possible indications for the surgical intervention of impacted mandibular canines.⁽¹⁴⁾ Autotransplantation of transmigrated/impacted canine is a technique-sensitive procedure and prognosis depends upon continued vitality of the periodontal membrane so this procedure involves interdisciplinary approach with immense care of periodontium. In cases where periodontal structures injured during transplantaion, external root resorption or ankylosis is the outcome.⁽¹⁵⁾ Most of the time it is possible to surgically expose and align the impacted/transmigrated canine in the dental arch if the treatment planning dictates it as reported by Watted *et al.*⁽¹⁶⁾ He reported a case with mesioangular

transmigration of 43 with odontoma in the region of 83. Treatment involved surgical removal of the odontoma followed by orthodontic traction and alignment of 43 in the arch. Although presented case was slightly different because transmigrated canine (43) and transposed canine (33) both were partially erupted. 43 was mesioangulated and transmigrated across the midline with only crown portion crossing the midline while 33 was fully transposed in place of 32. Both ectopic teeth partially erupted labially and gingivally to lower incisors. Clinical features and findings led us to go with fixed orthodontic treatment plan for both ectopically erupted lower canines that ended well according to described treatment plan. More the intraosseous migration across the midline, success with orthodontic traction of impacted canine will be poor.

IV. Conclusion

Canines are the most important teeth in terms of maintaining the facial harmony and functional efficiency. The unerupted canines are generally asymptomatic and patients often consult only for aesthetic reasons and occasionally for functional impairments. Radiographic examination is essential to diagnose impacted canines and panoramic radiographs are generally required to diagnose transmigrated/transposed canines. Timely detection and treatment can help to manage these canines, surrounding tissues and dentition, resulting in better aesthetic and function.

References

- [1]. Thilander B, Jakobsson SO. Local factors in impaction of maxillary canine. *Acta Odontologica Scandinavica* 1968;26:145-168.
- [2]. Dalessandri D, Parrini S, Rubiano R, Gallone D, and Migliorati M. Impacted and transmigrant mandibular canines incidence, aetiology, and treatment: a systematic review. *European Journal of Orthodontics*, 2017:161–169.
- [3]. Bishara SE. Impacted maxillary canines: A review. *Am J Orthod Dentofacial Orthop* 1992;101:159–71.
- [4]. Peck S, Peck L. Classification of maxillary tooth transpositions. *Am J Orthodont Dentofac Orthop* 1995;107:505-17.
- [5]. Perez B, Arad A. Bilateral transposition of maxillary canine and first premolars: case report. *Quintessence*, 1992;23:345-8.
- [6]. Hatzoudi M, Papadopoulos MA. Prevalence of tooth transposition in Greek population. *Hell Orthod Rev*. 2006;9:11–22.
- [7]. Onyeaso CO, Onyeaso AO. Occlusal/dental anomalies found in a random sample of Nigerian schoolchildren. *Oral Health Prev Dent*. 2006;4:181–186.
- [8]. Camilleri S, Scerri E. Transmission of mandibular canines- A review of the literature and a report of five cases. *Angle Orthod*. 2003;73:753–62.
- [9]. Tarsitano JJ, Wooten JW, Burditt JT. Transmigration of non-erupted mandibular canines: Report of cases. *J Am Dent Assoc*. 1971;82:1395–7.
- [10]. Javid B. Transmigration of impacted mandibular cuspids. *Int J Oral Surg*. 1985;14:547–9.
- [11]. Joshi MR. Transmigrant mandibular canines: A record of 28 cases and a retrospective review of the literature. *Angle Orthod*. 2001;71:12–22.
- [12]. Mupparapu M. Patterns of intraosseous transmigration and ectopic eruption of mandibular canines: Review of literature and report of nine additional cases. *Dentomaxillofac Radiol*. 2002;31:355–60.
- [13]. McDonald F, Yap WL. The surgical exposure and application of direct traction of unerupted teeth. *Am J Orthod*. 1986;89:331–40.
- [14]. Sinko K, Nemeš S, Seemann R, Eder-Czemberek C. Clinical Management of Impacted and Transmigrated Lower Canines. *J Oral Maxillofac Surg*. 2016;74:2142e1–16.
- [15]. Clokie CM, Yau DM, Chano L. Autogenous tooth transplantation: An alternative to dental implant placement? *J Can Dent Assoc*. 2001;67:92–6.
- [16]. Watted N, Hussein E, Awadi O, Abu-Hussein M. Transmigration of Impacted Canines: A Report of Two Cases and a Review of the Literature. *J Dent Sci*. 2014;12:23–32.

Neeteesh K Shukla." Management of Transmigrated and Transposed Mandibular Canines- A Case Report." *IOSR Journal of Dental and Medical Sciences (IOSR-JDMS)*, vol. 18, no. 5, 2019, pp 80-85.