

Role of Magnetic Resonance Imaging in Shoulder Pain

Suhail Rafiq¹, Shariq Shah², Sheema³, Sajad Dar⁴

¹ Senior Resident, Department of Radiodiagnosis and Imaging, GMC Srinagar, India.

² Senior Resident, Department of Radiodiagnosis and Imaging, GMC Jammu, India.

³ Senior Resident, Department of Gynecology and Obstetrics, SKIMS, India.

⁴ Professor, Department of Radiodiagnosis and Imaging, GMC Srinagar, India.

Corresponding Author: Suhail Rafiq

Date of Submission: 13-05-2019

Date of acceptance: 30-05-2019

I. Introduction

Shoulder pain is the third most common musculoskeletal complaint in the general population, and accounts for 5% of all musculoskeletal consultations. It is second only to knee pain for referrals to the Orthopedics. Shoulder pain can be acute or chronic. Nonacute shoulder pain is a common medical condition, particularly in middle-aged and older adults [1, 2]. Nonacute, or chronic, shoulder pain is defined as pain lasting at least 6 months, often without a definite inciting traumatic event. There are many causes of nonacute shoulder pain. Common causes of nonacute shoulder pain, listed in order from the most to the least common, include rotator cuff impingement, tendinosis, and tears; adhesive capsulitis; subacromial-subdeltoid bursitis; calcific tendinosis; glenohumeral and acromioclavicular (AC) osteoarthritis (OA); biceps tendinosis, tears, and dislocation; instability and labral tears; paralabral cyst; distal clavicular osteolysis; internal impingement; rheumatologic disorders; tumors; stress fractures; and cervical spine disease [3, 4].

Acute shoulder pain is usually secondary to trauma. Anterior dislocation of the shoulder may be associated with rotator cuff tears, which, if undetected, may be the cause of recurrent anterior instability [5]. Posttraumatic subscapularis tendon tears may be isolated or associated with injuries to the long head of the biceps brachii tendon [6]. In older individuals, tendon rupture may occur after acute trauma to rotator cuff tendons with underlying chronic degenerative changes [7].

The major cause of shoulder pain in patients older than 40 years is rotator cuff impingement and tears. With the development of new arthroscopic techniques for treating rotator cuff disorders, magnetic resonance imaging (MRI) has played an increasingly important role as a noninvasive test for determining which patients [8-11] may benefit from surgery.

The rotator cuff is the most commonly affected structure in the shoulder, and sub acromial impingement syndrome is the leading [12-16] cause of rotator cuff injury.

II. Aim and objectives:

1. To demonstrate the role of MRI in detecting shoulder pathologies encountered in patients of shoulder pain with or without history of trauma .
2. To assess the common painful pathologies of shoulder encountered on MRI in Kashmir.

III. Materials and methods

The study was a prospective study done in department of Radiodiagnosis, GMC Srinagar from November 2018 to April 2019. 36 patients referred for MRI Shoulder with or without history of trauma after excluding any fracture on routine radiographs.

PROTOCOL: MRI of the Shoulder was performed on SOMATOM Seimens 3 TESLA. The sequences used were— Axial T1 Weighted images, axial STIR(Short Tau Inversion recovery images), Coronal oblique STIR, Coronal oblique T1 Weighted images, sagittal oblique T2 Weighted images and sagittal oblique STIR. No medication/IV contrast were used in the study

EXCLUSION CRITERIA: 1. Patients with Fractures on shoulder radiographs
2. Patients with previous operative history over Shoulder.
3. Patients with contraindications for MRI like metallic tattoos, claustrophobia etc.

IV. Results And Discussion

The age of the patients was between 23 years to 53 years with maximum number of patients in age group of 30 to 40 years. 20 of patients were males and 16 were females.

Causes of shoulder pain as diagnosed by MRI were Rotator cuff tears especially Supraspinatus tears with partial tears in 7 patients and complete tear in 5 patients. Infraspinatus tear was seen in one patient. Complete tears were divided into small (≤ 1 cm), medium (1-3 cm), large (3-5 cm) or massive (≥ 5 cm) tears [17,18] on the basis of greatest dimension. The dimensions of rotator cuff tears may have implications for selection of treatment and surgical approach, postoperative prognosis, and tear recurrence. For example, with a different classification system, rotator cuff tears greater than 1 cm² are associated with an unfavorable outcome if treated conservatively and will, therefore, likely be treated surgically [19]. In contrast, primary repair is often not possible when both the length and the width of the tear exceed 4 cm at preoperative MR imaging [20]. tear is suspected to be irreparable if MR imaging depicts retraction of the tendon edge medial to the glenoid

fossa [21] Partial-thickness tears can be classed as articular, bursal, or intratendinous. MR imaging can provide information about rotator cuff tears such as tear dimensions, tear depth or thickness, tendon retraction, and tear shape that can influence treatment selection and help determine the prognosis.

Labral tears were second most common cause of shoulder pain with Anteroinferior Labral tears accounting for 5 patients and SLAP tears for 3 patients. Associated Hillsachs lesion could only be found in 1 patient. We were able to characterize labral tears in only 3 patients into perthes lesion in 1 patient, humeral avulsion of inferior glenohumeral ligament (HAGL) in 1 patient and Glenolabral articular disruption (GLAD) in one patient. In 2 patients we couldn't characterize labral tear since MR arthrography is superior to conventional MR imaging for diagnosis of labral lesions (even at 3 T) [22-26].

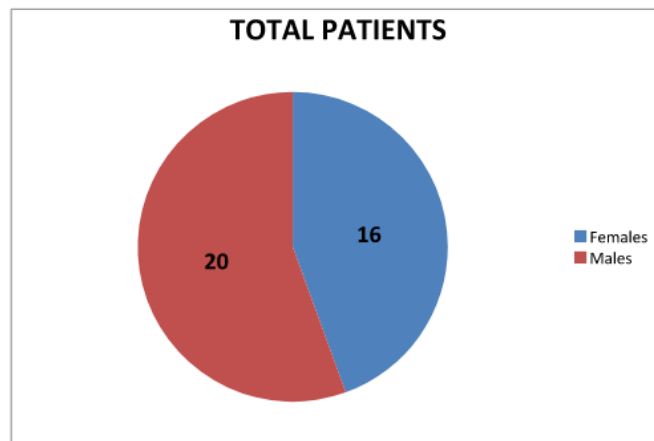
We had 3 cases of SLAP (superior labral anteroposterior) tears in our study. A SLAP lesion is a tear of the superior labrum, usually centered at the LHBT origin, and it can extend to the anterior and posterior labrum [27]. It can also propagate along the periarticular fiber system to the surrounding anatomic structures (the superior glenohumeral ligament, IGHL, rotator interval, or LHBT origin) [28]. Clinical diagnosis of SLAP lesions is difficult; most patients present with nonspecific shoulder pain, associated shoulder injuries, and no objective clinical instability [29]. Therefore, MRI shoulder has very important role in its detection.

Third most common cause of shoulder pain were adhesive capsulitis and acromioclavicular(AC) joint arthropathy each accounting for 4 cases. Adhesive capsulitis is a clinical syndrome of pain and severely decreased joint motion ("frozen shoulder") caused by thickening and contraction of the joint capsule and synovium. Most common findings in our study were abnormal soft tissue thickening within the rotator interval with signal alteration and thickened axillary recess.AC joint arthropathy was seen in patient above 40 years of age.

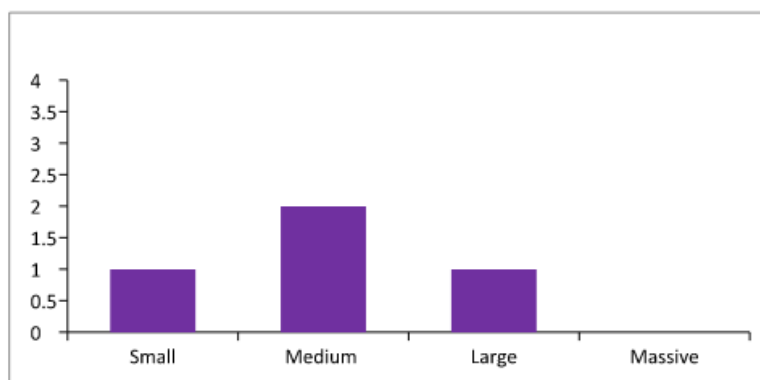
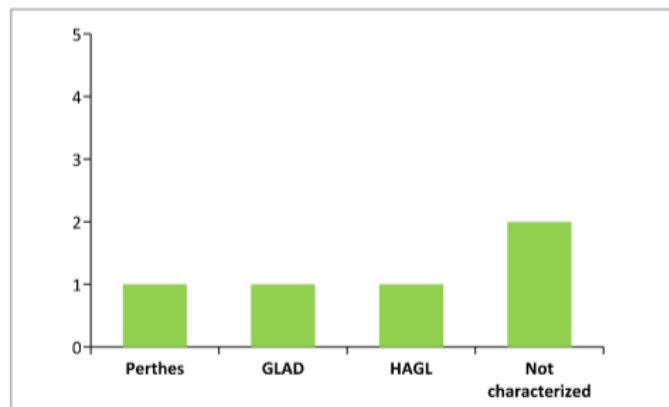
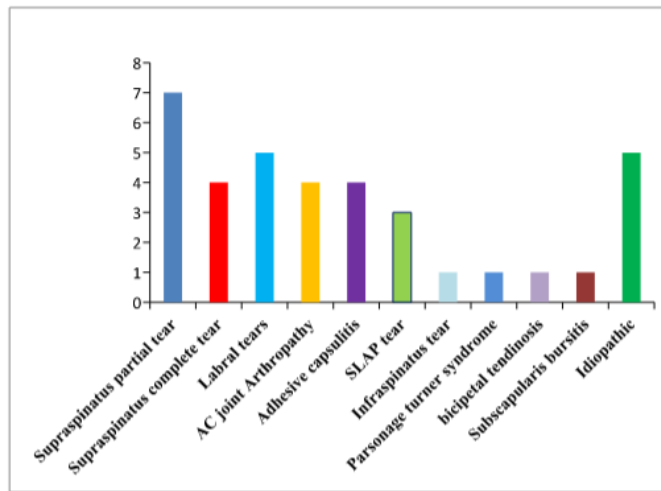
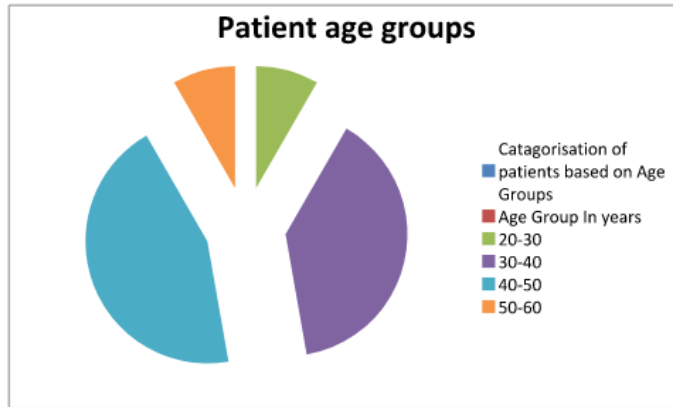
We had single case of Infraspinatus tear, Parsonage Turner syndrome, subscapularis bursitis and bicipetal tendinosis each.

MRI Shoulder is beneficial in giving information about what the mode of treatment whether medical or surgical should be given to patients. Patients with full thickness supraspinatus tears, labral and SLAP tears would need surgical treatment while as shoulder pain causes like adhesive capsulitis, AC joint arthropathy, Parsonage Turner syndrome would easily respond to medical treatment.

Proper surgical follow up from orthopedic surgeons was available for patients needing surgical treatment. We had 100% accuracy in diagnosing complete supraspinatus tears, labral and SLAP tears. However, one of limitation of our study was failure to characterize all labral tears and classify SLAP tears which is of vital importance to Orthopedician.



Age Group In years	No. Of Patients
20-30	3
30-40	14
40-50	16
50-60	3



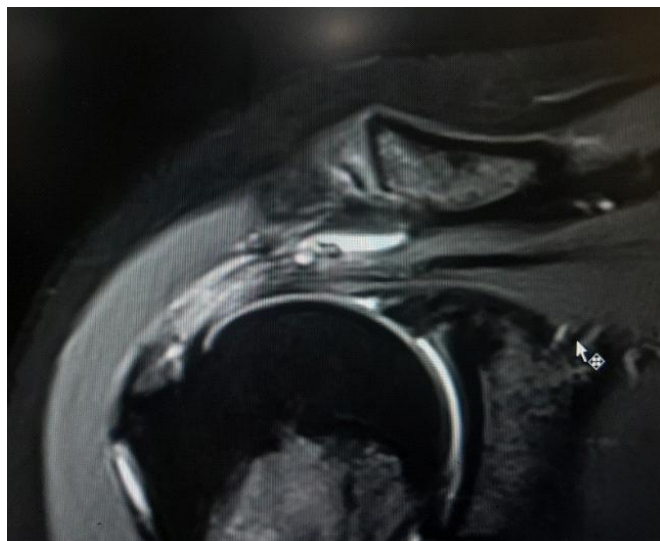


Fig 1: Coronal MRI Shoulder image shows increased signal intensity in Supraspinatus tendon predominately involving Bursal surface with associated subdeltoid subacromial bursitis.

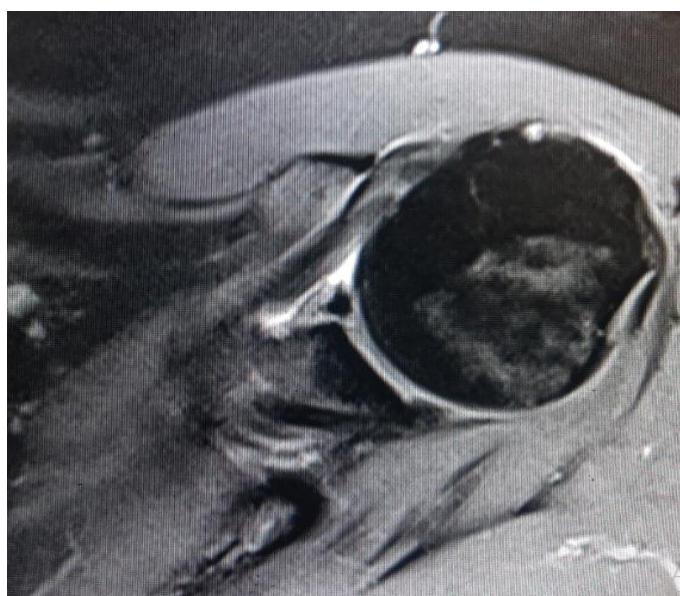

Fig 2: Axial MRI shoulder image revealing anterior –inferior labral tear characterized as Perthes lesion.

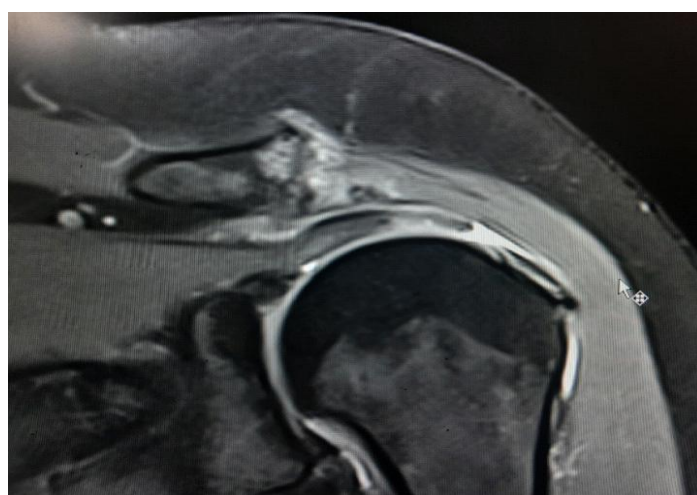


Fig 3: Coronal MRI Shoulder image revealing subchondral edema and irregularities involving acromio-clavicular joint consistent with arthropathy along with complete tear involving Supraspinatus tendon.

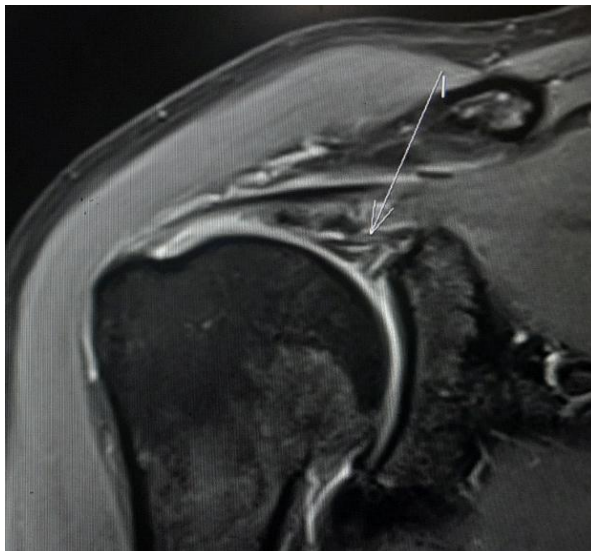

Fig 4 : Coronal MRI Shoulder image revealing SLAP extending to long head of biceps (arrow) along with partial tear involving articular surface of Supraspinatus.

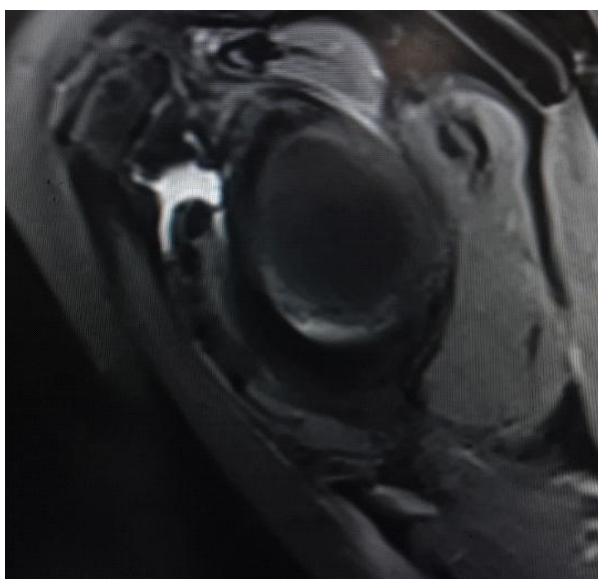


Fig 5: Sagittal oblique MRI Shoulder revealing fluid collection along subscapularis tendon consistent with Subscapularis bursitis.

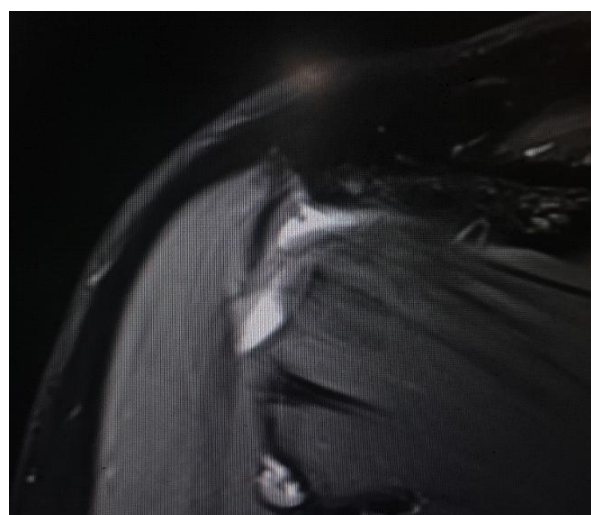


Fig 6: Coronal MRI Shoulder image revealing fluid in relation to Infraspinatus tendon consistent with Infraspinatus tear.

V. Conclusion

MRI is a non-invasive, non ionizing modality of choice for evaluating patients with shoulder pain. MRI shoulder is also helping in deciding which patients will benefit from medical and surgical treatment. Conventional MR imaging has limitation of characterizing all labral tears and proper classification of SLAP tears which can be overcome by MR Arthrography.

References

- [1]. Andrews JR. Diagnosis and treatment of chronic painful shoulder: review of nonsurgical interventions. *Arthroscopy* 2005; 21:333–347 [Crossref] [Medline] [Google Scholar]
- [2]. Burbank KM, Stevenson JH, Czarnicki GR, Dorfman J. Chronic shoulder pain. Part I. Evaluation and diagnosis. *Am Fam Physician* 2008; 77:453–460 [Medline] [Google Scholar].
- [3]. Van der Windt DA, Koes BW, de Jong BA, Bouter LM. Shoulder disorders in general practice: incidence, patient characteristics, and management. *Ann Rheum Dis* 1995; 54:959–964 [Crossref] [Medline] [Google Scholar]
- [4]. Stevenson JH, Trojjan T. Evaluation of shoulder pain. *J Fam Pract* 2002; 51:605–611 [Medline] [Google Scholar]
- [5]. Neviasser RJ, Neviasser TJ, Neviasser JS. Anterior dislocation of the shoulder and rotator cuff rupture. *Clin Orthop Relat Res* 1993;291:103–106.
- [6]. Deutsch A, Altchek DW, Veltri DM, Potter HG, Warren RF. Traumatic tears of the subscapularis tendon: clinical diagnosis, magnetic resonance imaging findings, and operative treatment. *Am J Sports Med* 1997;25(1):13–22.
- [7]. Norwood LA, Barrack R, Jacobson KE. Clinical presentation of complete tears of the rotator cuff. *J Bone Joint Surg Am* 1989;71(4):499–505.
- [8]. Lambert A, Loffroy R, Guiu B, Mejean N, Lerais J, Cercueil J, et al. [Rotator cuff tears: value of 3.0T MRI]. *J Radiol*. 2009 May. 90(5 Pt 1):583-8. [Medline].
- [9]. De Jesus JO, Parker L, Frangos AJ, Nazarian LN. Accuracy of MRI, MR arthrography, and ultrasound in the diagnosis of rotator cuff tears: a meta-analysis. *AJR Am J Roentgenol*. 2009 Jun. 192(6):1701-7. [Medline].
- [10]. Burks RT, Crim J, Brown N, Fink B, Greis PE. A prospective randomized clinical trial comparing arthroscopic single- and double-row rotator cuff repair: magnetic resonance imaging and early clinical evaluation. *Am J Sports Med*. 2009 Apr. 37(4):674-82. [Medline].
- [11]. Murray PJ, Shaffer BS. Clinical update: MR imaging of the shoulder. *Sports Med Arthrosc*. 2009 Mar. 17(1):40-8. [Medline].
- [12]. Van der Windt DA, Koes BW, De Jong BA, Bouter LM. Shoulder disorders in general practice: incidence, patient characteristics, and management. *Ann Rheum Dis* 1995; 54:959–64.
- [13]. Teefey SA, Hasan SA, Middleton WD, Patel M, Wright RW, Yamaguchi K. Ultrasonography of the rotator cuff. A comparison of ultrasonographic and arthroscopic findings in one hundred consecutive cases. *J Bone Joint Surg Am* 2000; 82:498–504.
- [14]. Neer CS. Anterior acromioplasty for chronic impingement syndrome of shoulder. *J Bone Joint Surg* 1972; 54A:41–50.
- [15]. Blanchard TK, Bearcroft PW, Constant CR, Grifn DR, Dixon AK. Diagnostic and therapeutic impact of MRI and arthrography in the investigation of full-thickness rotator cuff tears. *EurRadiol* 1999; 9:638–42.
- [16]. Torstensen ET, Hollinshead RM. Comparison of magnetic resonance imaging and arthroscopy in the evaluation of shoulder pathology. *J Shoulder Elbow Surg* 1999; 8:42–5. 2012;34(1):49–56.
- [17]. Farley TE, Neumann CH, Steinbach LS, Jahnke AJ, Petersen SS. Full-thickness tears of the rotator cuff of the shoulder: diagnosis with MR imaging *AJR Am J Roentgenol*. 1992 Feb;158(2):347-51.
- [18]. Post M, Silver R, Singh M. Rotator cuff tear: diagnosis and treatment. *Clin Orthop* 1983; 173:78-91.
- [19]. Bartolozzi A, Andreychik D, Ahmad S. Determinants of outcome in the treatment of rotator cuff disease. *Clin Orthop Relat Res* 1994;308:90–97.
- [20]. Sugihara T, Nakagawa T, Tsuchiya M, Ishizuki M. Prediction of primary reparability of massive tears of the rotator cuff on preoperative magnetic resonance imaging. *J Shoulder Elbow Surg* 2003; 12(3):222–225.
- [21]. Thomazeau H, Boukobza E, Morcet N, Chaperon J, Langlais F. Prediction of rotator cuff repair results by magnetic resonance imaging. *Clin Orthop Relat Res* 1997;344:275–283.
- [22]. Beltran J, Bencardino J, Mellado J, Rosenberg ZS, Irish RD. MR arthrography of the shoulder: variants and pitfalls. *RadioGraphics* 1997;17(6):1403–1412; discussion 1412–1415
- [23]. Chloros GD, Haar PJ, Loughran TP, Hayes CW. Imaging of glenoid labrum lesions. *Clin Sports Med* 2013;32(3):361–390.
- [24]. Sheridan K, Kreulen C, Kim S, Mak W, Lewis K, Marder R. Accuracy of magnetic resonance imaging to diagnose superior labrum anterior-posterior tears. *Knee Surg Sports Traumatol Arthrosc* 2015;23(9):2645–2650.
- [25]. Bencardino JT, Beltran J, Rosenberg ZS, et al. Superior labrum anterior-posterior lesions: diagnosis with MR arthrography of the shoulder. *Radiology* 2000;214(1):267–271.
- [26]. Major NM, Browne J, Domzalski T, Cothran RL, Helms CA. Evaluation of the glenoid labrum with 3-T MRI: is intraarticular contrast necessary? *AJR Am J Roentgenol* 2011; 196(5):1139–1144.
- [27]. Chang D, Mohana-Borges A, Borso M, Chung CB. SLAP lesions: anatomy, clinical presentation, MR imaging diagnosis and characterization. *Eur J Radiol* 2008;68(1):72–87.
- [28]. Huber WP, Putz RV. Periarticular fiber system of the shoulder joint. *Arthroscopy* 1997;13(6):680–691. 19. Arai R, Kobayashi M, Toda Y, Nakamura S, Miura T, Nakamura T. Fiber components of the shoulder superior labrum. *Surg Radiol Anat*
- [29]. Chang EY, Fliszar E, Chung CB. Superior labrum anterior and posterior lesions and microinstability. *Magn Reson Imaging Clin N Am* 2012;20(2):277–294, x–xi.

Suhail Rafiq. “Role of Magnetic Resonance Imaging in Shoulder Pain.” *IOSR Journal of Dental and Medical Sciences (IOSR-JDMS)*, vol. 18, no. 5, 2019, pp 16-21.