

## Advanced Diagnostic Imaging in Periodontal Diseases: A Review

P. S. Rakhewar<sup>1</sup>, Anuja Muley<sup>2</sup>, Kedar Saraf<sup>3</sup>, Manojkumar Thorat<sup>4</sup>,  
Lisa Chacko<sup>5</sup>, Saurabh Patil<sup>6</sup>, Apeksha Birla<sup>7</sup>

<sup>1</sup>Department Of Periodontology, SMBT Dental College and Hospital & Post Graduate Research Centre, Sangamner, Maharashtra, India.

<sup>2</sup>Department Of Periodontology, SMBT Dental College and Hospital & Post Graduate Research Centre, Sangamner, Maharashtra, India.

<sup>3</sup>Department Of Oral Medicine & Radiology, SMBT Dental College and Hospital & Post Graduate Research Centre, Sangamner, Maharashtra, India.

<sup>4</sup>Department Of Periodontology, SMBT Dental College and Hospital & Post Graduate Research Centre, Sangamner, Maharashtra, India.

<sup>5</sup>Department Of Periodontology, SMBT Dental College and Hospital & Post Graduate Research Centre, Sangamner, Maharashtra, India.

<sup>6</sup>Department Of Periodontology, SMBT Dental College and Hospital & Post Graduate Research Centre, Sangamner, Maharashtra, India.

<sup>7</sup>Department Of Periodontology, SMBT Dental College and Hospital & Post Graduate Research Centre, Sangamner, Maharashtra, India.

Corresponding Author: Anuja Muley

---

**Abstract:** Radiographs are an integral part of a periodontal assessment for those with clinical evidence of periodontal destruction. A variety of radiographic exposure types helps in the development of periodontal treatment plans. Radiographs provide diagnostic information on alveolar bone levels, plaque retention factors, caries, furcation defects, subgingival calculus and additional pathology. A relationship exists between probing attachment loss and radiographic bone height, with a range in level of correlation; clinical attachment may correspond more closely to surgical measurements of bone height. Radiographs can be used in planning initial, corrective and supportive phases of therapy, though some decisions may be made on clinical assessments alone. Thus the aim of this review is to discuss in detail all the diagnostic imaging used in periodontics.

**Keywords:** advanced diagnostic imaging, periodontitis, diagnosis, treatment, periodontics.

---

Date of Submission: 26-04-2019

Date of acceptance: 11-05-2019

---

### I. Introduction

Periodontal disease is a chronic bacterial infection that affects the gingiva and bone supporting the teeth<sup>1</sup>. Treatment of patients with advanced periodontal diseases requires not only extensive clinical recording but also radiological examination. A clinical evaluation of the periodontium is always performed first, followed by the radiographic study. These two examinations are complementary<sup>2</sup>, and therefore the gold standard of veterinary oral health care includes thorough clinical assessment of all teeth (periodontal probing) as well as full mouth radiography. This article describes various diagnostic imaging used in periodontics.

#### History:

Roentgen reported the discovery of an unusual type of radiation in 1895. The first dental X-ray was taken in Frankfurt in 1896 by W. Konig. Edmond Kells of New Orleans was the first United States dentist to routinely use dental X-rays diagnostically, beginning in 1896. In the introduction to a textbook on dental radiology, McCall, a pioneer in both periodontology and radiology, describes a referral he made to a physician in 1905 to locate an impacted third molar.<sup>3</sup> One of the early pioneers in periodontology and a founder of the American Academy of Periodontology, Arthur Merritt was among the early advocates of radiographic diagnosis and had developed a very sophisticated awareness of the limitations of radiographic diagnosis. As early as 1916 he noted: "The bone loss in pyorrhea frequently takes place on one or two sides only of the four root surfaces. If this happens to be the labial or lingual surface, the roentgenogram will have the appearance of a normal tooth". In one of the early textbooks on dental radiology (1916), Thoma noted: "The Roentgen method affords an excellent means of studying the progress of pyorrhea alveolaris, and is a valuable aid in the diagnosis and prognosis of the disease, as it registers the extent to which bone has been affected and destroyed." He also

observed that the etiology and duration (of periodontal disease) cannot be determined by X-ray and that it is necessary to know normal anatomy to be proficient in roentgenological diagnosis.<sup>3</sup>

He described nodular calculus as well as bone loss to the apex of one surface of a tooth without the tooth becoming mobile. An early atlas of dental pathology documented periodontal bone loss patterns of varying degrees and correlated the radiographic findings with the clinical appearance of the periodontal condition (128). Pollia advised that in early cases with “absolutely no clinical symptoms, radiographs will reveal more of interest to the diagnostician than clinical examination.” It is interesting to note that many of the original publications and observations on the use of dental radiographic findings were made by pioneers in periodontology, including Merritt, McCall, Hirschfeld, Prinz and Weski. Radiopaque markers to record pocket topography were used by Neumann in the 1920s. Hirschfeld later quantified this technique. As the distortion caused by nonstandardized film placement became evident, several investigators attempted to develop techniques that insured great anatomical accuracy. These modifications recognized that the short film target distance commonly used in dental radiography resulted in unacceptable enlargement and resolved the inaccuracy by lengthening the tube to create parallel rays and film placement closer to the object, reducing the enlargement distortion. In recent decades, many periodontists have adopted the standardized film placement holders developed by Updegrave. Other factors such as kilovoltage, exposure time, development time and film sensitivity were further standardized. The clinician who successfully championed radiographic accuracy in periodontal diagnosis in modern times was John Prichard. A comparison between anatomical and radiographic interpretation of marginal periodontal disease was reported in 1958 and, by 1960, quantitative methods for assessing small changes in bone height were being described. In the 1970s, the clinical trials evaluating surgical and nonsurgical therapy carried out in the United States and Sweden required the use of individually adapted X-ray film holders, to ensure accurate and reproducible measurements of bone level changes. These and other studies concluded that the “results indicate poor agreement between clinical and radiographic diagnoses”. Other investigators suggested that radiographs result in substantial underestimation of attachment loss, due to limits of interproximal diagnosis. More recently, as interest in identifying local sites of active inflammatory disease has increased, computerization and subtraction radiography have provided tools for much more sophisticated radiographic assessment of marginal bone changes.

#### **When To Advise Radiographs In Periodontal Diseases?**

After taking thorough clinical history and examination for diseases of periodontium, dentist can decide when to go for radiographic investigations.

Clinical periodontal findings not captured on radiographs are:

- Gingival redness
- Gingival swelling
- Gingival bleeding
- Gingival recession
- Gingival enlargements
- Bleeding on probing
- Probing pocket depth
- Tooth mobility
- Suppuration

Detectable features of interest on radiographs are:

- Bone levels
- Bone loss-horizontal  
-angular(vertical)
- Intra(infra)-bony defects
- Furcation radiolucencies
- Local irritating factors-calculus  
-radio-opaque restorative margins-deficiency, overhang
- Endodontic mishaps
- Root morphologies/topographies and crown to root ratio
- Open interproximal contacts ,which may be sites for food impaction
- Root length and shape(s) embedded in alveolar bone, root resorption
- Widened periodontal ligament space
- Approximal root caries
- Root canal fillings
- Periapical periodontitis, cysts, granulomas
- Anatomic considerations -position of the maxillary sinus in relation to periodontal

deformity

-Impacted third molars

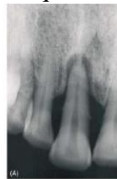
- Retained & fractured roots
- Cemental tears
- Cysts/tumors
- Developmental anomalies

### 1] Conventional Radiographs:

A conventional radiographic image consists of the arrangement of silver grains in the photographic emulsion. The density of the silver grains depends on the intensity of the X Ray beam. When a radiograph is viewed on a light box using transmitted light, the pattern of the different densities of the silver grains is transferred to the eyes and perceived as different shades of gray.<sup>4</sup> It is the traditional method to assess the destruction of alveolar bone associated with periodontitis. It can be used to evaluate bone loss even or angular patterns eg.intra(infra)bony defects ,root morphologies / topographies , furcation radiolucencies, endodontic lesions, endodontic misshapes, developmental anomalies and root length and shape remaining in bone.

### 2] Intra Oral Periapical Radiographs:

Two common techniques used to take conventional radiographs are Paralleling and Bisecting angle techniques .X-ray film is placed parallel to the long axis of tooth and central ray of x-ray beam is directed at right angle to teeth and film in paralleling and central ray is directed at right angles to a plane bisecting the angle between long axis of teeth and film in bisecting techniques .<sup>5</sup>



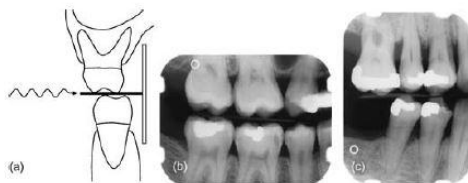
True combined endodontic-periodontal disease

Advantages of IOPA:

Gives assessment of periodontal status and apical infection, teeth and alveolar bone condition after trauma , unerupted teeth and detailed evaluation of apical cysts and other lesions in the alveolar bone.

### 3] Bitewing Radiographs:

Records the coronal part of upper & lower dentition along with periodontium. It is used to study the height and contour of interdental alveolar bone, interproximal calculus and caries, periodontal changes, gingival margins of approximal fillings. There are two common types one is horizontal and the other is vertical. Horizontal bitewing radiographs are useful for proximal caries detection. But it has limited use in periodontal treatment and treatment planning if bone loss is advanced. In vertical bitewing radiographs the film is placed with its long axis at 90° to the placement for horizontal bitewing radiography and is helpful in evaluating periodontium.<sup>6</sup>



The ideal projection geometry creates an image without distorting the relationship between the buccal alveolar crest, the lingual alveolar crest and the cemento enamel junction(a), (b) example of a horizontal bitewing radiograph(c) example of a vertical bitewing radiograph.

#### **4] Occlusal Radiographs:**

It enables viewing of a relatively large segment of dental arch. These types of radiographs are taken in patients with trismus, impacted canines and third molars. It is also used to localize foreign bodies in the jaws, determining the extent of diseases like cysts and to measure the changes in size and shape of the mandible.<sup>7</sup>

#### **5] extraoral radiographs:**

Extra-oral radiographs are taken when large areas of the skull or jaw must be examined when patients are unable to open their mouths for film placement. It is not adequate for detection of early stages of dental caries or periodontal disease.<sup>8</sup>

#### **6] Conventional Panoramic Imaging(Orthopantomography):**

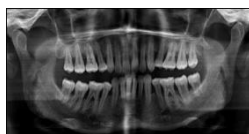
Oral pantomography is used as substitute for full mouth IOPA. It can be used in follow-up treatment, progress of pathology ,postoperative bony healing and prior to any surgical procedures( extraction of impacted teeth, enucleation of cyst) <sup>9</sup>.It is also used to view of the alveolar bone levels and evaluation of vertical height of alveolar bone before inserting osseo – integrated implants, arc shaped bone loss seen in aggressive periodontitis.

Advantages of OPG

1. Broad coverage of the facial bones and teeth
2. Low patient radiation dose
3. Convenience of the examination for the patient
4. Use in patients unable to open their mouths
5. Short time required to make a panoramic image, usually in the range of 3 to 4 minutes.<sup>10</sup>
6. Patients readily understand panoramic films; thus they are also a useful visual aid in patient education and case presentation.

Limitations of OPG

The main disadvantage of panoramic radiology is that the image does not display the fine anatomic detail available on intraoral periapical radiographs. Thus it is not as useful as periapical radiography for detecting small carious lesions, fine structure of the marginal periodontium, or periapical disease. The proximal surfaces of premolars also typically overlap. Accordingly, the availability of a panoramic radiograph for an adult patient often does not preclude the need for intraoral films for the diagnoses of most commonly encountered dental diseases. Other problems associated with panoramic radiography include unequal magnification and geometric distortion across the image. Occasionally the presence of overlapping structures, such as the cervical spine, can hide odontogenic lesions, particularly in the incisor regions. Further, clinically important objects may be situated outside the plane of focus (image layer) and may appear distorted or not present at all.<sup>10</sup>



#### **7] Radiovisiography (Rvg):**

The RVG system is capable of rapidly displaying a digital radiographic image on a monitor which results in a lower patient radiation. The "Radio" component is the conventional x-ray generator with a timer, capable of very short exposure time, along with image receptor. The "Visio" portion converts the output signal from a CCD to a digital format and displays it on a monitor.

The "Graphy" component consists of data storage unit connected to a video printer <sup>11</sup>. Duret F et al (1988) described RVG based on use of CCD. A filmless environment allows rapid image acquisition, less expensive storage, multiple viewing, and remote exchange of images. Development of a filmless environment also facilitates the teaching and research responsibilities incumbent in an academic environment. Electronic teaching files, electronic conferences, teleconsultation, and other communication processes are enabled with the availability of electronic images. It can be used in dental caries detection, intra bony defects and periapical pathologies detection .<sup>12</sup>

#### **8] Digital Image:**

The electric signal that is produced by the sensor is a voltage that is varying as a function of time. The sensor is connected to a special board in the computer, called a frame grabber; the function of this board is to sample the signal at short intervals, thus converting the analog signal into a digital signal. The output of the measurements is stored in the computer as numbers.<sup>13</sup>When the image is captured and digitized by means of an electronic sensor system, the radiation intensities are measured a long a rectangular two- dimensional grid of

sensor elements, called pixels. The outcome of the measurement of each sensor elements transferred to the computer and stored as a number between 0 and 255. To display the image, the numbers are read out and used to control the intensities of the pixels on the monitor screen. Several methods exist to acquire a digital image.<sup>14</sup>

**(a) Conventional radiograph digitized, using a flat-bed scanner and transparency adapter**

This procedure assumes that a conventional radiograph is available. The radiograph is scanned, using a flatbed scanner with a transparency adapter. Usually the spatial resolution can be chosen such that the diagnostic details are preserved in the digital image.

**(b) Semi direct Digital Image, Acquired Using Photo stimulable Phosphor Plates**

Photo stimulable phosphor plates can hold a latent x-ray image for some time. The latent image is the result of excitation of electrons in the phosphor crystals by the x-ray photons. Later a laser beam scans the image plate. The electrons return to the original energy level; during this process, energy is emitted in the form of light, which can be captured by a photo-multiplier device. The output of the photo-multiplier is converted into pixel values, comprising the image information. This technology is called semidirect because of the intermediate phase of the latent image. Photo stimulable phosphor plates are available in sizes comparable to conventional dental film.<sup>15</sup>

**(c) Direct Digital Image, Acquired Using a Charge Coupled Device, Complementary Metal- Oxide Semiconductor, or Other Electronic Device**

In this method, the intensity of the radiation in the x-ray beam is measured directly by an electronic device consisting of a large number of light-sensitive elements. The output of these elements is transferred to the computer as an electric signal and digitized in the frame grabber board. A scintillation layer (such as a screen phosphor material) is put on top of the sensor array. X-ray photons are converted into light photons, increasing the efficiency of the detector. The size of the electronic sensors has been considerably smaller than a No. 2 dental film, but currently sensors with an active area that approaches the dimensions of standard intraoral film are available.

**9] Intra Oral Detector:**

Direct sensor systems are capable of real-time imaging; an image is displayed on the monitor in a few seconds. The systems are built around a CCD sensor. CCDs are arrays of x-ray-sensitive or light-sensitive pixels.<sup>15</sup> A CCD is made up of a large number of photoelectric cells (several thousand) that generate voltage in proportion to the amount of light or x-rays striking them. The CCD charge is read by transferring the collected charge in each pixel, in a serial fashion to a read out amplifier. The same photon generated charge collected at each pixel site is transferred pixel by pixel (similar to a bucket brigade) in a predesigned sequence that cannot be interrupted. When the pixel charge is transferred to the readout amplifier, it is destroyed.

**Advantage of CCD** Lowest noise of any competing technology.

**Disadvantages of CCD devices**

Blooming- Blooming is similar to allowing too much light through a viewbox, blinding the operator and washing out radiographic information in the excessively bright image. This blooming occurs in CCD systems by excess charge leakage to other pixels. Because commercial grade CCDs contain some flaws, regions of bad pixels result in a partially or a totally bad column or row of pixels. The output from the CCD is to be digitized. A special hardware converter (Analog-To- Digital converter [ADC]) then takes the voltages generated by the individual elements of the CCD and rounds them off into the number of alternative values to be used to represent the image digitally. If 256 shades of gray are to be represented, the signal from each CCD element is converted to the appropriate value within this range. Initial sensor systems captured the image using this gray scale from 0 to 255.

**10] Complementary Metal Oxide Semiconductor Cmos:**

Based sensors are now finding their way into intraoral sensors systems. The first advantage of CMOS technology is design integration. The major advantages of CMOS image sensors are integration, lowpower, manufacturability, and low cost. Another advantage of CMOS technology is the ability to benefit from the high-volume manufacturing capacity already in place to support the CMOS semiconductor industry.<sup>16</sup> A CMOS chip is already in every computer in the world. CMOS sensors also permit the integration of control circuit, including ADC, directly into the sensor. The Schick CDR sensor (Schick Technologies, LongIsland, NY) is an example of the application of this new technology. On the downside, although they perform well in bright light conditions (eg: digital photographic cameras), CMOS sensors may not perform well in lowlight conditions or with the rigorous demands of medical imaging systems. They have more fixed pattern noise and use some of the chip or

area for other operations, leaving less active area for image acquisition. Besides CBCT, panoramic imaging also uses CMOS technology. Dentists use the panoramic mode to image the entire set of teeth and parts of the jaw in a single view for placement of dental implants and assessment of TMJ disorders, sinus infections and other problems.

### **11] Digital Subtraction Radiography:**

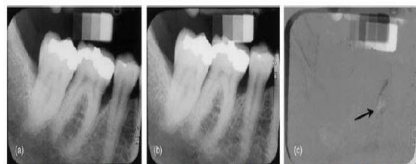
In 1935 Zeidse des Plantes first demonstrated this technique, who used a photographic technique. It is the technique by which images not of diagnostic value in a radiograph, are reduced so that the changes in the radiograph can be precisely detected. Digitalisation achieved by taking a picture of radiograph using video camera. This technique facilitates both qualitative & quantitative visualization of even minor density changes in bone by removing the unchanged anatomic structures from image. Digital subtraction radiography(DSR) has been developed to enhance the visualization of mineral changes that have occurred. To show these changes against a homogeneous background of unchanged anatomy, a high level of standardization in projection geometry and image density needs to be achieved. The application of subtraction radiography in dentistry was facilitated by the development of micro computer, allowing conventional radiographs to be digitized and subtracted.<sup>17</sup> When two images of the same objects are registered and the image intensities of corresponding pixels are subtracted, a uniform difference image will be produced. If a change in the follow up image has occurred, this change will show up as a brighter area when the change represents gain as a darker area when the change represents loss. The strength of the DSR that it cancels out the complex anatomical background against this changes occurs.<sup>14</sup>

#### **Advantages of DSR**

It can able to detect small osseous lesions. There is high degree of correlation between changes in alveolar bone. The overall contrast is improved ,trabecular marrow spaces can be visualized with enhancement of low and high density images.<sup>7</sup>

#### **Disadvantages of DSR**

DSR is not capable to give an objective description. Presence of high standardization of x rays, no reduction in exposure, not an economical and time consuming process. It also needs for identical projection alignment during exposure of sequential radiographs.<sup>7</sup>



Application of DSR for detection and quantification of periodontal bone healing (a) baseline image (b) 1-yr follow up (c) subtraction image showing bone gain.

### **12] Computer Assisted Densitometric Image Analysis System:**

It is introduced by Urs Brägger et al 1988. A video camera measures the light transmitted through a radiograph then the signals are converted to grey scale images .Camera is inter faced with computer and image processor for storage and mathematic manipulation of image. It offers an objective method for studying alveolar bone changes quantitatively. This gives a high degree of sensitivity, accuracy and reproducibility.<sup>19</sup>

### **13] Computer-Based Thermal Imaging:**

It compares the re-warming rates of normal and inflamed human gingiva. Aid in gingival temperature measurement. Valuable objective method for the diagnosis of periodontal diseases. Infra-red thermograph provides a non-invasive method.

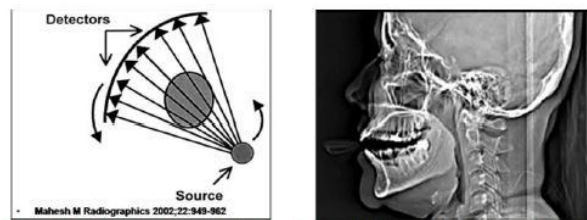
### **14] Conventional Tomography:**

It is designed to image a slice or plane of tissue accomplished by blurring the images lying outside the plane of interest. It consists of an x ray tube and radiographic film rigidly connected which moves about a fixed axis and fulcrum. As exposure begins tube and film move in opposite direction simultaneously. Objects located within the fulcrum remain in fixed positions and are viewed clearly. It is used less frequently with the introduction of MRI, CT and Cone beam imaging.

### **15] Computed Tomography:**

Godfrey Hounsfield and Allan MacLeod Cormack (1979) shared Nobel prize .It consists of a x ray tube emitting finely collimated x- ray beam directed through the patient to a series of scintillating detectors or ionizing chambers. Detectors form a continuous ring and x-ray tube moves in a circle with in the ring. Patients

lie stationary and x ray tube rotates one turn .Then the table will move 1 to 5 mm to next scan. <sup>20</sup> The three dimensional information has led to exploring the value of CT for the assessment of alveolar bone height. CT machines use a rotating fan beam to image one thin slice.



(a)rotating the ray source with a wide fan beam (b) CT scan taken for oral implant planning

### a)helical CT

Introduced in 1989.The gantry containing x ray tube and detectors continuously revolve around the patient ,where as patients table advances through the gantry.Result is acquisition of a continuous helix of data.The detectors are gas filled ion chambers of xenonand solid state detectors of cadmium tungstate . <sup>21</sup>

### Advantages:

It eliminates superimposition of images of structures outside area of interest. It has got wide field of view, operator independent, good soft tissue discrimination, sensitive for soft tissue calcification and bone involvement. It gives a high contrast resolution differences between tissues that differ in density. Images can be viewed in axial coronal and sagittal planes.

### Disadvantages:

The main disadvantages are high radiation dose, difficult to scan in planes other than axial planes, require intravenous contrast for best results and costly.

### b)small volume CT

It is a form of CBCT utilizes small field high resolution detector to generate high resolution 3D volume. Generally comparable to size of intraoral radiographs. Van Daatselaar 2003 based on comparison made between a full CT geometry and a local CT geometry implies “local CT of dental structures appears to be a promising diagnostic instrument.”

### c) Denta CT scan

DentaScan is a unique computer software program provides computed tomographic (CT) imaging of the mandible and maxilla in three planes of reference: axial, panoramic, and oblique sagittal. Provides visualization of internal bone morphology in three dimensions; precise treatment planning. In cross sectional view, observation regarding bone quality, density can be made. Preoperative planning of endosseous dental implants and sub-periosteal implants. <sup>22</sup>

CT provides information of the internal structures that cannot even be gained by direct intra-operative visualization, the bony structures visualization. It gives precise location of the mandibular canal and the floor of the maxillary sinuses. It has the advantages of minimum additional cost; Low radiation dose; Multi planer reformation; Eliminates streak artifacts; exact information about alveolar bone dimensions and Location of mandibular canal and maxillary sinus. In implant imaging, it helps in measuring Bone quantity: Height and buccolingual dimension of implant site; Bone volume: Extent of bone resorption; Bone quality and precise location of vital structures.

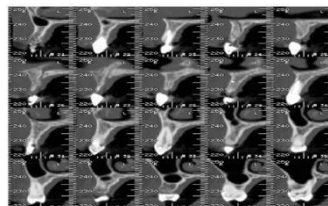
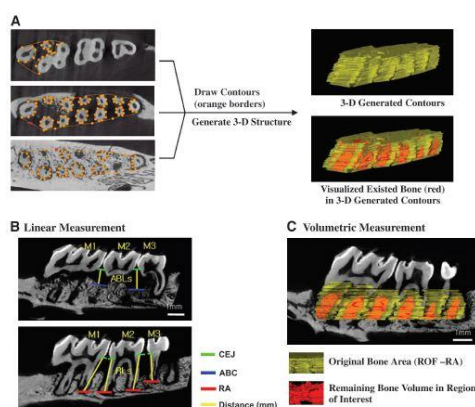


Fig. Dental CT

**d)micro CT**

Because of alveolar bone's non-uniformity and porous structure and its close proximity to dental structures, it is difficult to quantify. Current approaches that attempt to quantify alveolar bone include histomorphometry, two-dimensional (2-D) radiography, and more recently, micro-computed tomography (micro-CT)<sup>23, 24</sup>. Micro-CT or medical CT is a non-destructive technique that can be used in 3-D to image specimens on the micron level and allows for computer-aided reorientation following image scanning, thus assuring nearly identical alignment. Micro-CT for preclinical application provides higher spatial resolution images than medical or dental CT for clinical assessment.<sup>25</sup> Using this technique, compared to histologic sections, micro-CT scans show slight deviations at periodontal defects or in cases of alveolar bone loss.<sup>26</sup>



Method for creating 3-D ROI used in analysis of alveolar bone A) Two-dimensional contours are drawn at regular intervals from the ROFs to the RAs. Once all contours are drawn, a 3-D ROI is generated for reconstruction. B) Linear measurements are taken of alveolar bone loss (ABL) in the interdental space from the CEJ to ABC and RLs from the CEJ to RA( in mm) C) volumetric measurement with 3-D generated ROIs. Software assesses the amount of bone and analyzes volumetric parameters in the volume of interest that are 3-D generated contours

The selected landmarks for quantification of alveolar bone (ROF) [roof of furcation], the most Distal end of molar roots, and tangent line between roots on the coronal plane for landmark detection of ROI[region of interest]) provided critical criteria and reproducibility to measure volumetric osseous parameters. This methodology can serve as a standard for static bone assessment of disease progression and alveolar bone regeneration with high accuracy.

**16] Cbct( Cone-Beam Computed Tomography):**

Three-dimensional (3D) diagnostic imaging of the jaws has been of interest from the introduction of computerized tomography (CT) as a clinical tool. However, due to the factors like high cost and high radiation dosage, use of this technology in dentistry has been limited (CBCT) is a relatively new imaging modality and with the introduction of dedicated dentomaxillofacial CBCT scanners in the late 1990s, there has been an explosion of interest in these devices in the field dentistry. It has the obvious advantage of relatively low cost and low-dose. CBCT differs from CT in that it uses a single X-ray source that produces a cone beam of radiation (rather than a fan beam, as with CT).<sup>27</sup> CBCT uses a single, relatively inexpensive, flat-panel or image intensifier radiation detector. CBCT imaging is performed using a rotating platform to which the X-ray source and detector are fixed. As the X-ray source and detector rotate around the object, it produces multiple, sequential, and planar images that are mathematically reconstructed into a volumetric dataset. A single rotational sequence would capture enough data for volumetric image construction. The entire scanning of the target region is performed in a single rotation thereby significantly reducing the radiation exposure. Further, the exposure is reduced by 50% (0.0037mGy) if a 180 degree scan is performed instead of 360 degree.<sup>28</sup>

Misch et al.<sup>29</sup> reported that CBCT is as accurate as direct measurements using a periodontal probe and as reliable as intraoral radiographs for interproximal areas. Also, since buccal and lingual defects could not be diagnosed with intraoral radiography, CBCT could be considered a superior technique.

Benic et al.<sup>30</sup> stated that in ethically approved clinical research, three-dimensional imaging (computed tomography or cone beam computed tomography) can be used pre- and postoperatively to evaluate bone and soft tissues, as well as the implant position, with reference to the anatomic structures. Cone beam computed tomography imaging is increasingly being used for three-dimensional assessment of bone following ridge preservation, sinus floor elevation and implant placement with simultaneous bone augmentation or staged procedures following block grafts. Besides visualization of bony structures, cone beam computed tomography is



also used to assess the contour and dimension of the periimplant mucosa. This is accomplished by applying radio-opaque contrast materials, such as thin foils, on the surface of the mucosa, or by displacing the lips and the cheeks from the alveolar process by means of lip retractors or cotton rolls .

CBCT	MEDICAL CT
Single rotation	Multiple rotations
Lower radiation dose	Higher radiation dose
Isotropic voxels	Anisotropic voxels
Lower cost	Higher cost
Smaller space requirement	Larger devices
Better spatial resolution	Better contrast resolution
Deficiency to display soft tissues	Clear evaluation of soft tissues
Higher scatter radiation	Lower scatter radiation

CBCT	CONVENTIONAL RADIOGRAPHY
3D imaging	2 D imaging
Cross-sectional and volumetric images	Superpositions
Elimination of image deformity	Distortion and magnification
Higher radiation dose	Lower radiation dose
Higher cost larger devices	Lower cost smaller apace requirement

Mol et al <sup>31</sup> observed that the CBCT images provided more accurate information on periodontal bone levels in three dimensions than the images of photo stimulated phosphor plates. In a similar study, it was found that CBCT was better in morphological description of periodontal bone defects, while the images obtained by charged coupled device sensor provided more bone details.<sup>32</sup> Moreover, it was reported that CBCT and conventional periapical radiographs differed in instead of about measuring the height of the alveolar bone crest but there was not a significant difference between the two methods in detecting the depth and width of bone defects.<sup>33</sup> Mengel et al <sup>34</sup> demonstrated that CBCT images were better in detection of periodontal defects compared with periapical radiographs and medical CT. Likewise, Noujeim et al <sup>35</sup> concluded that CBCT technique has better diagnostic accuracy than periapical films in the detection of interradicular periodontal bone defects.

**Furcation involvement**

An accurate diagnosis of inter radicular bone loss is an important issue prior to the decision of appropriate treatment options including apically repositioned flaps with or without tunnel preparation, root amputation, hemi-/trisection or root separation. Conventional two dimensional radiographs can be deceptive in evaluating periodontal tissue support and inter radicular bone due to superposition of anatomical structures. However, 3D images provide detailed information about areas of multi rooted teeth. CBCT images of maxillary molars provided detailed information of furcation involvement and a reliable basis for treatment decision.<sup>36</sup> Intrasurgical furcation involvement measurements were compared by using CBCT images and it was reported that CBCT images demonstrated a high accuracy in assessing the loss of periodontal tissue and classifying the degree of furcation involvement in maxillary molars.<sup>37</sup> Authors evaluated CBCT images of artificially created furcation involvement of the second molars in pig mandibles and accuracy for furcation lesion detection ranged between 78% and 88%.<sup>38</sup> A study compared dental radiographs and high resolution CT (HR-CT) in detecting and grading of artificial furcation involvements in jaw specimens from cadavers. The diagnostic rate of dental radiographs was 21% whereas HR-CT was 100%.<sup>39</sup>

**Soft tissue assessment**

CBCT is a more appropriate tool for evaluating mineralized tissues than soft tissues. However, a practical method named soft tissue CBCT (ST-CBCT), was reported, and it was utilized to determine the dimensions and relationships of the structures of the dentogingival unit. The tongues were retracted toward the floor of patients’ mouths and a plastic lip retractor was used to retract the soft tissues away from the teeth and gingiva during CBCT scans and the images that were obtained provided clear information for the analysis of various dentogingival unit measurement.<sup>40</sup> Mentioned method was used in another study in which the average thickness of the palatal mucosa according to ages and specific localizations were determined on thirty one patients. The thickness of palatal mucosa has a major importance for the treatment planning of soft tissue grafts. However, this technique provides only quantitative assessment, thus the differences between the epithelial, fat and connective tissues can not be distinguished on ST-CBCT images.<sup>40, 41</sup>

**Periodontal ligament space**

The earliest sign of periodontitis that can be detected on radiographs is a wedge-shaped radiolucent area in the inter-proximal region. At this stage, the continuity of lamina dura is lost and some changes in

periodontal ligament space can be observed.<sup>42, 43, 44</sup> Authors compared CBCT with conventional radiography in terms of their ability to produce images of periodontal ligament space on a phantom model with artificially created periodontal ligament of various thicknesses. Periapical radiographs were found to be superior to CBCT for the measurement of periodontal ligament space. However, authors of another study concluded that CBCT images had higher accuracy than intraoral radiographs in the determination of periodontal space in a similar research.<sup>44</sup> Conflicting findings may be attributed to the differences between radiographic systems and settings used in various studies. Visibility of periodontal ligament space using different radiographic techniques should be assessed in further studies.

### **Alveolar bone defects**

Radiographs are frequently utilized to diagnose the amount and shape of alveolar bone destruction that affects treatment planning in periodontal therapy.<sup>3,4</sup> 2D radiographs can be insufficient for the detection of intra-bony alveolar defects due to obstruction of spongy bone changes by cortical plate. Thus, three-dimensional imaging is required for mapping of alveolar defects.<sup>45</sup> Periodontal defects in pigs and human mandibles were displayed using intraoral radiography, panoramic radiography, CT and CBCT which were compared with histological specimens. The results of the mentioned study showed that 3D imaging had high accuracy in the detection of alveolar defects. Whereas, intraoral and panoramic radiographs could not determine the dehiscence unequivocally, tomographic images displayed all dehiscences and provided accurate measurements of the defects. Authors also reported that CBCT displayed the best imaging quality. Authors evaluated periodontal defects in human dry cadaver skulls using CBCT and traditional methods. Consequently, they found that there was no difference between intraoral radiography and CBCT in linear measurements for all defects. In another study<sup>46</sup>, authors evaluated accuracy and reliability of CBCT for measuring alveolar bone height and detecting bony dehiscence and fenestration. CBCT measurements were found to be equivalent to direct measurements and dehiscences were diagnosed with higher accuracy than fenestrations. CBCT and multi-slice CT (MSCT) images were used for alveolar bone width measurements.<sup>47</sup> There was no significance difference between the measurements obtained by CBCT and MSCT or direct measurements and radiographic methods.

### **Regenerative periodontal therapy and bone grafts**

Bone grafting is commonly used for maxillary sinus lifting and treatment of intra bony defects but evaluation of osseous defect regeneration with conventional radiography can be insufficient due to superimpositions.[34,48] Furthermore, histological evaluation of a sample of the graft is not a preferred method due to its quite invasive procedure. CBCT was found to be significantly more accurate than digital intraoral radiographs when direct surgical measurements served as the gold standard for the evaluation of intra-bony defects' regenerative treatment outcomes. CBCT can replace surgical re-entry by providing 3D images and measurements that are almost equivalent to direct surgical measurements.<sup>48</sup> Dimensions of alveolar process should be examined in detail prior to dental implant placement to avoid various complications and evaluation of CBCT images has a major importance in preoperative planning and postoperative localization of dental implants . Moreover, the evaluation of CBCT images are preferred method to observe bone graft healing prior to dental implant placement .<sup>49</sup> In a previous study, which was based on measurement accuracy and reliability of CBCT and MSCT with the specific implant planning software package and the stereolithographic drill guide, authors applied implant surgeries in a one-stage flapless procedure. The deviations were acceptable and no complications were observed.<sup>50</sup> In contrary, authors of another study concluded that CBCT may be deceptive compared to direct caliper measurements and they found that ridge mapping method gave more accurate results than CBCT.<sup>51</sup> However, ridge mapping technique is an invasive technique whereas CBCT is not. CBCT evaluation can be used for determining the width, height and distance to the anatomical structures of alveolar process in pre-surgical dental implant planning. Likewise, the surgical guide stents were used while dental implant surgery was produced by aid of CBCT images and software packages. Immediate implant placement enables one-stage surgery and eliminates bone recovery time. In this technique, dimensions of alveolar process which is selected for dental implant placement and relationships with adjacent anatomical structures of this region should be carefully assessed. Jin et al<sup>52</sup> studied bone thickness evaluation on the buccal and palatal aspects of the maxillary canine and premolars using CBCT and it was concluded that CBCT images might be advantageous in preoperative planning of dental implants. As a summary, in cases, where two-dimensional imaging is an inadequate method for accurate diagnosis of periodontal defect configuration and guiding for appropriate treatment planning, three-dimensional radiographic examinations may be required. Periodontal intra-bony defects and furcation involvements keep a challenge for the examiner. Misdiagnosed or misclassification of these pathologies can lead to progress of bone destruction and teeth loss as a result of improper treatment. CBCT evaluation can be used for determining the width, height and distance to the anatomical structures of alveolar process in pre-surgical dental implant planning. Likewise, the surgical guide stents used during dental implant surgery is produced by aid of CBCT images and software packages. There are

numerous studies that 3D imaging had high accuracy in the detection of alveolar defects and furcation involvements. CBCT is well complied for imaging the highly mineralized structures such as bone or teeth but it cannot provide clear images of soft tissues. However, a novel, CBCT-based method to display and measure the dimensions of the palatal mucosa was reported in a recent study. There are contradictory results on whether CBCT or conventional radiographs are more efficient in evaluation of periodontal ligament space. Assessment of regenerative periodontal therapy and bone grafts' outcomes can be performed accurately and reliably with CBCT imaging. In conclusion, CBCT applications provide obvious benefits in periodontology, although it should be used when two-dimensional radiographs are insufficient considering the necessity and the potential radiation hazards of the examination.

### Other Periodontal Applications of CBCT

Even within the field of periodontology, CBCT has found numerous applications. CBCT has been widely used in the detection of periapical pathology. Various studies have reported on the effectiveness of using CBCT for the diagnosis of periapical pathology.<sup>53,54,55</sup> The literature shows that CBCT images are superior for the detection of apical periodontitis than conventional radiographs. Apical periodontitis is one of the most common endodontic diseases, and it is considered to be the primary indication for root canal treatment and a sequela of inadequate or failing treatment.<sup>56</sup> CBCT has found application even in epidemiological surveys. A recent study<sup>57</sup> used CBCT images from a database to determine the prevalence of apical periodontitis. Dutta et al. investigated the prevalence of periradicular periodontitis using CBCT scans in a retrospective cross-sectional epidemiological study in a Scottish subpopulation. CBCT is a radiological technique that has been more successful in detecting periradicular changes than conventional radiography. In a recent case-report, CBCT was used in the diagnosis of a palatogingival groove.<sup>58</sup> Another recent study evaluated bone resorption at the extraction sites of a group of patients under orthodontic treatment using CBCT to evaluate the periodontal and bone support loss after tooth extraction. CBCT was preferred due to its higher precision in detecting bone changes.

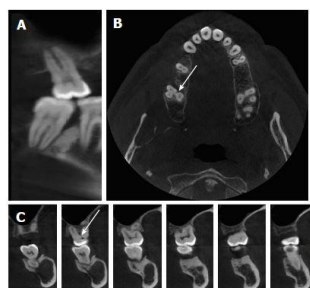


Fig. Furcation involvement can not be observed in the panoramic like section(A) whereas it can be evaluated in the axial (B) cone beam computed tomography image(arrows)

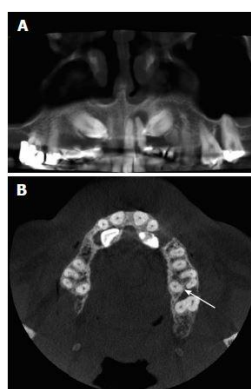


Fig. The amount and shape of bone resorption in the furcation area of maxillary molar tooth can not be assessed in the panoramic-like section(A) this involvement is seen in the axial section(B)

**cbct in implant dentistry**

The use of CBCT imaging following insertion of dental implants should be restricted to specific postoperative complications (such as damage to neurovascular structures) or postoperative infections in relation to the maxillary sinus. To confirm the position of an implant in relation to anatomic landmarks after insertion, and also for evaluation of peri-implant bone conditions during follow up visits, conventional (two-dimensional) radiographic techniques, such as periapical or panoramic views, are sufficient. Regarding peri-implantitis, the diagnosis and severity of the disease should be evaluated primarily based on clinical parameters and on radiological findings based on periapical radiographs (two dimensional radiographic techniques, such as periapical or panoramic views, are sufficient). Cone beam computed tomography imaging is used in research to evaluate, pre- and postoperatively, bone and soft tissues as well as the implant position with reference to the anatomic structures. The effect on peri-implant hard and soft tissues of surgical techniques, such as ridge preservation, sinus floor elevation and implant placement with simultaneous bone augmentation, or following staged procedures using block grafts is evaluated in a short- and long-term perspective with quite variable frequencies between the actual cone beam computed tomography scans.<sup>59</sup>

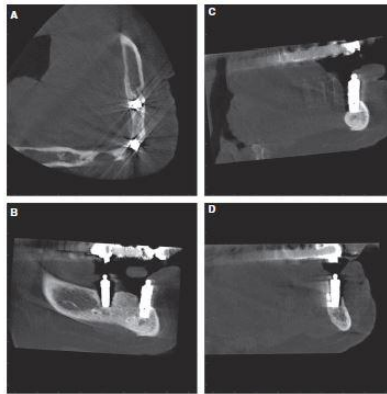


Fig. (a) axial view showing the two implants (symphysis and left first – premolar region) and a bone defect resulting from implant loss in the right canine area. (B) sagittal view showing the implant in the symphysis and the left – premolar region. (C) sagittal view showing the implant in the symphysis with almost no visible bone on the buccal and lingual aspects. (D) coronal view showing the implants in the left first-premolar region with evident bone loss on the buccal and lingual aspects.

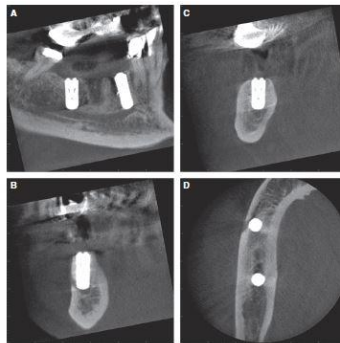
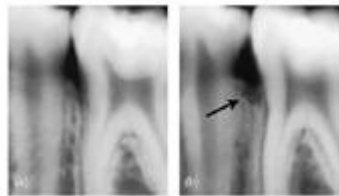


Fig. (A) sagittal view showing proximity of the dental implant in region 45 to the mental foramen located distally to the tooth 44. (B) coronal view of implant penetration in region 45 into the mandibular canal and the region of mental foramen. (C) coronal view of the implant in region 47 exhibiting its relation to mandibular canal. (D) axial view visualizing penetration of the implant in region 45 into the mental foramen.

### 17] Tuned Aperture Computed Radiography:

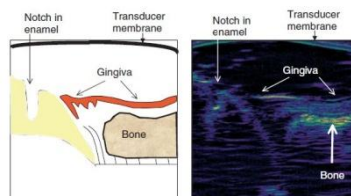
Tuned-aperture computed tomography (TACT) that have indicated the superiority of detection of signals that were not appropriately visualized using other available imaging modalities. Significant advantages include a demonstrated increased sensitivity and specificity for a variety of diagnostic tasks, high resolution, lower dose, post processing of images, and absence of artifacts associated with CT. The diagnostic task was indeed a challenging one in that a small area of bone loss was intended to be detected in an area superimposed by osseous and dental tissue densities without the use of digital subtraction. Detection of these defects by TACT-IR (iterative restoration) indicates that this imaging modality could be used in clinical practice routinely as an adjunctive decision support system to diagnose incipient bone loss in this area. The superior diagnostic efficacy of TACT-IR demonstrates that the ease of detection of lesions in slices was probably not dependent on image manipulation that involved contrast and brightness enhancements.<sup>60</sup>

Application of TACT (a) image slice through the buccolingual center of the alveolar bone (b) image slice through the buccal aspect of the alveolar bone. The presence of a bone defect in the buccal aspect of the interproximal alveolar bone is evident (arrow)



### 18] Ultrasonography:

One of the first reports of ultrasonography in periodontology was by Spranger (1971) who tried to determine the height of the alveolar crest in periodontitis patients. He concluded that if carefully used, this technique could add some information to X-ray diagnosis, although he encountered many technical difficulties. Palou et al. (1987) also used ultrasonography for the determination of periodontal bone morphology in periodontitis patients. They concluded that measurements of the alveolar bone topography with their ultrasonic probe were not accurate and there were problems with reproducibility, especially in areas of difficult access. Under ideal experimental conditions (the ultrasound pulses striking perpendicular to smooth, parallel / aligned interfaces), Lo'st et al. (1988) were able to determine the width of the periodontal ligament, using one-dimensional A-scans in specially prepared pig jaws. Ultrasound could provide reliable images of the alveolar crest and the gingival tissues and sometimes of the entrance of the periodontal ligament space. The advantages of using non-invasive assessments without ionising radiation could lead to applications in the evaluation of soft and hard tissue healing after periodontal surgery (regenerative, mucogingival or implant surgery), as well as for the clinical assessment and treatment planning prior to implant placement.<sup>61</sup>



### 19] MRI:

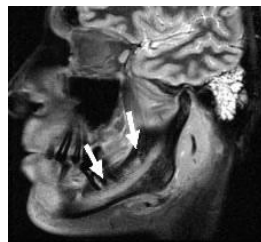
It does not involve the use of ionizing radiation. It involves the behaviour of protons in a magnetic field. The image itself is another example of a tomograph or sectional image that at first glance resembles a CT. Used for imaging intracranial and soft tissue lesions. In head and neck region MRI is used for the assessment of intracranial lesions involving particularly the posterior cranial fossa, the pituitary and the spinal cord. For investigation of the salivary glands & Tumour staging, investigation of the TMJ to show both the bony and soft tissue components and implant assessment. Schara et al 2009 in an in vitro study evaluated the use of MRI to characterize inflammation and healing process in periodontal tissues and it was concluded that MRI can characterize the type and healing process of inflammation.<sup>62</sup>

### Advantages of MRI:

Non ionizing radiation is used. there is no biological effects. It gives higher soft tissue contrast. Blood vessels clearly seen. High resolution images can be constructed in all planes. MRI image before and after initial periodontal therapy is useful.

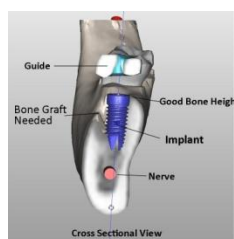
### Disadvantages of MRI:

It is an expensive procedure time consuming. Metallic objects in the oral cavity produce artifacts.



### 20]SIMPLANT:

It is a computer program for assessing oral implant site .Uses raw data from CT along with advanced computer graphics. The advantages are assessment of bone volume, bone height & quality, Proper length of implant can be selected and clear visualization of inferior alveolar canal.<sup>7</sup>



### 21] BONE SCANNING OR RADIONUCLIDE IMAGING:

In contrast to X-ray, CT, MRI which require structural or anatomic changes to be recorded, this technique assesses biochemical alteration in body. It is a nuclear scanning test that identifies new areas of bone growth or breakdown. It can be done to evaluate damage to the alveolar bones, and monitor conditions that can affect the periodontium (including metastatic lesions and malignant lesions.)

### 22] DICOM STANDARD:

The Digital Imaging and Communications in Medicine. It facilitates communications between imaging devices and systems. By dictating specific data and interface requirements, DICOM ensure that devices, particularly devices made by different suppliers, can communicate with one another.<sup>7</sup>

## II. Conclusion

The adoption of advances in the radiographic modality of the future, when based on sound scientific evidence, has the potential to transform the way we visualize the periodontal tissues. Digital image standardization, subtraction radiography, 3D imaging and quantitative image analysis are already a reality. There is little doubt that periodontists of the future will be using more advanced imaging modalities, either directly as a chair side procedure, or indirectly through the services of an oral and maxillo facial radiologist. Dentists should have knowledge of the working principles, requirements, clinical benefits and hazardous effects of these systems for proper usage.

## References

- [1]. B. L. Pihlstrom, B. S. Michalowicz, and N. W. Johnson, "Periodontal diseases," *The Lancet*, vol. 366, no. 9499, pp. 1809–1820, 2005.
- [2]. A. Tugnait, V. Clerehugh, and P. N. Hirschmann, "The usefulness of radiographs in diagnosis and management of periodontal diseases: a review," *Journal of Dentistry*, vol. 28, no. 4, pp. 219–226, 2000.
- [3]. Steveni. gold diagnostic techniques in periodontology: a historical review *periodontology* 2000, vol. 7, 1995, 9-21.
- [4]. Fermin A. Carranza and Henry H. Takei. Radiographic Aids in the Diagnosis of Periodontal Diseases. *Carranza's Clinical Periodontology* 2006; 10: 454 – 469.
- [5]. Andre' Mol .Imaging methods in periodontology.*Periodontology* 2000,2004(34),34-48.
- [6]. Marjorie K. Jeffcoat, L-Chung Wang & Michael S. Reddy. Radiographic diagnosis in periodontics. *Periodontology* 2000(19995); 07:54–68.
- [7]. Dr. Rasila Sainu J .Biosci Tech, Imaging Techniques in Periodontics: A Review Article Vol 7(2),2016,739-747.
- [8]. Chai-Hui Chen, Shui-Hui Lin, Hui-Lin Chiu, Hui-Lin Chiu, Yu-Ju Lin, Yuk-Kwan Chen, et al. An aiming device for an extraoral radiographic technique.*JOE* 2007;33(6):758-60.
- [9]. Stuart C. White , Michael J Pharoah . *Oral Radiology Principles and Interpretation* 2009; 6 :109 – 244.
- [10]. Stuart C. White , Michael J Pharoah . *Oral Radiology Principles and Interpretation* 2009;5<sup>TH</sup> EDITION:191
- [11]. Macdonald R. Digital imaging for dentists. *Australian Dental Journal* 2001; 46:(4):301-305.

- [12]. Weathers K. RadioVisioGraphy Comes of Age. *Practical Endodontics* 1993; January: 1.
- [13]. Brennan .An introduction to digital radiography in dentistry *J orthodontics* 2002;(29):66-69.
- [14]. Parks ET et al *Digital Radiography: An overview J Contemp Dent Pract* 2002; 4 (3): 23-39.
- [15]. Paul F et al *The implementation of digital sensors in maxillofacial radiography Nuclear Instruments and Methods in physics research*2001;460:45-49.
- [16]. White et al *The Evoluti Evolution and application of dental maxillofacial Imaging modalities Dent Clin N Am* 2008;52:689–705.
- [17]. Grondahl H-G, Grondahl k, Webber RL.A digital subtraction technique for dental radiography.*Oral surg oral med oral pathol* 1983;55:96-102.
- [18]. Andre' Mol .Imaging methods in periodontology.*Periodontology* 2000,2004 (34),34-48.
- [19]. Urs Bragger. Radiographic parameters: biological significance and clinical use . *Periodontology* 2000(2005); 39 : 73 – 90.
- [20]. Ekkestubbe A,Thilander A,Gröndahl K, Gröndahl H-G .Absorbed doses from computed tomography for dental implant surgery: comparison with conventional tomography. *Dento maxillofac Radiol*1993;22:13–1.
- [21]. Samuel J. Zeichner, Marjorie Jeffcoat . *Radiography in Periodontal Assessments. Fundamentals of Periodontics* 2006; 2: 284- 294.
- [22]. Dentascan in oral imaging,Au- Yeung ,K .M. etal. (2001) .*Clinical Radiology* 56, 700 – 713.
- [23]. Hamada Y, Kondoh T, Noguchi K, et al. Application of limited cone beam computed tomography to clinical assessment of alveolar bone grafting: A preliminary report. *Cleft Palate Craniofac J* 2005;42:128-137.
- [24]. Hausmann E. Radiographic and digital imaging in periodontal practice. *J Periodontol* 2000;71:497-503.
- [25]. Van Oosterwyck H, Duyck J, Vander Sloten J, et al. Use of microfocus computerized tomography as a new technique for characterizing bone tissue around oral implants. *J Oral Implantol* 2000;26:5-12.
- [26]. Chan Ho Park,\*† Zachary R. Abramson,† Mario Taba Jr.,† Qiming Jin,† Jia Chang,‡Jaclynn M. Kreider,§ Steven A. Goldstein,\*§ and William V. Giannobile\*†Three-Dimensional Micro-Computed Tomographic Imaging of Alveolar Bone in Experimental Bone Loss or Repair/*jop.2007.060252*.
- [27]. W. Kalender and K. O. Khadivi, “Computed tomography: fundamentals, system technology, image quality, applications,” *Medical Physics*, vol. 33, p. 3076, 2006.
- [28]. R. A. Danforth, I. Dus, and J. Mah, “3-D volume imaging for dentistry: a new dimension,” *Journal of the California Dental Association*, vol. 31, no. 11, pp. 817–823, 2003.[
- [29]. Accuracy of cone beam computed tomography for periodontal defect measurements Kelly A. Misch,Erica S. Yi,and David P. Sarment *JPeriodontol*2006;77:1261-1266.
- [30]. Novel digital imaging techniques to assess the outcome in oral rehabilitation with dental implants: a narrative review Goran Benic,Moustafa Elmasry, Christoph H. F. Hammerle Volume 26, Issue S11: September 2015 :Pages 86–96.
- [31]. Mol A, Balasundaram A. In vitro cone beam computed tomography imaging of periodontal bone. *Dentomaxillofac Radiol* 2008; 37: 319-324.
- [32]. Vandenberghe B, Jacobs R, Yang J. Diagnostic validity (or acuity) of 2D CCD versus 3D CBCT-images for assessing periodontal breakdown. *Oral Surg Oral Med Oral Pathol Oral Radiol Endod* 2007; 104: 395-401.
- [33]. De Faria Vasconcelos K, Evangelista KM, Rodrigues CD, Estrela C, de Sousa TO, Silva MA. Detection of periodontal bone loss using cone beam CT and intraoral radiography. *Dentomaxillofac Radiol* 2012; 41: 64-69.
- [34]. Mengel R, Candir M, Shiratori K, Flores-de-Jacoby L. Digital volume tomography in the diagnosis of periodontal defects: an in vitro study on native pig and human mandibles. *J Periodontol* 2005; 76: 665-673.
- [35]. Noujeim M, Prihoda T, Langlais R, Nummikoski P. Evaluation of high-resolution cone beam computed tomography in the detection of simulated interradicular bone lesions. *Dentomaxillofac Radiol* 2009; 38: 156-162.
- [36]. Walter C, Kaner D, Berndt DC, Weiger R, Zitzmann NU. Three-dimensional imaging as a pre-operative tool in decision making for furcation surgery. *J Clin Periodontol* 2009; 36: 250-257.
- [37]. Walter C, Weiger R, Zitzmann NU. Accuracy of threedimensional imaging in assessing maxillary molar furcation involvement. *J Clin Periodontol* 2010; 37: 436-441.
- [38]. Umetsubo OS, Gaia BF, Costa FF, Cavalcanti MG. Detection of simulated incipient furcation involvement by CBCT: an in vitro study using pig mandibles. *Braz Oral Res* 2012; 26: 341-347.
- [39]. Fuhrmann RA, Bücker A, Diedrich PR. Furcation involvement: comparison of dental radiographs and HR-CT-slices in human specimens. *J Periodontal Res* 1997; 32: 409-418.
- [40]. Januário AL, Barriviera M, Duarte WR. Soft tissue conebeam computed tomography: a novel method for the measurement of gingival tissue and the dimensions of the dentogingivalunit. *J Esthet Restor Dent* 2008; 20: 366-373; discussion 374.
- [41]. Barriviera M, Duarte WR, Januário AL, Faber J, Bezerra AC. A new method to assess and measure palatal masticatory mucosa by cone-beam computerized tomography. *J Clin Periodontol* 2009; 36: 564-568.
- [42]. Ozmeric N, Kostjoutchenko I, Hägler G, Frentzen M, Jervøe- Storm PM. Cone-beam computed tomography in assessment of periodontal ligament space: in vitro study on artificial tooth model. *Clin Oral Investig* 2008; 12: 233-239.
- [43]. Mohan R, Singh A, Gundappa M. Three-dimensional imaging in periodontal diagnosis - Utilization of cone beam computed tomography. *J Indian Soc Periodontol* 2011; 15: 11-17.
- [44]. Jervøe-Storm PM, Hagner M, Neugebauer J, Ritter L, Zöllner JE, Jepsen S, Frentzen M. Comparison of cone-beam computerized tomography and intraoral radiographs for determination of the periodontal ligament in a variable phantom. *Oral Surg Oral Med Oral Pathol Oral Radiol Endod* 2010; 109: e95-e101.
- [45]. Misch KA, Yi ES, Sarment DP. Accuracy of cone beam computed tomography for periodontal defect measurements. *J Periodontol* 2006; 77: 1261-1266.
- [46]. Leung CC, Palomo L, Griffith R, Hans MG. Accuracy and reliability of cone-beam computed tomography for measuring alveolar bone height and detecting bony dehiscences and fenestrations. *Am J Orthod Dentofacial Orthop* 2010; 137: S109-S119.
- [47]. Loubelle M, Van Assche N, Carpentier K, Maes F, Jacobs R, van Steenberghe D, Suetens P. Comparative localized linear accuracy of small-field cone-beam CT and multislice CT for alveolar bone measurements. *Oral Surg Oral Med Oral Pathol Oral Radiol Endod* 2008; 105: 512-518.
- [48]. Grimard BA, Hoidal MJ, Mills MP, Mellonig JT, Nummikoski PV, Mealey BL. Comparison of clinical, periapical radiograph, and cone-beam volume tomography measurement techniquesfor assessing bone level changes following regenerative periodontal therapy. *J Periodontol* 2009; 80: 48-55.
- [49]. Eshraghi T, McAllister N, McAllister B. Clinical applications of digital 2-D and 3-D radiography for the periodontist. *J Evid Based Dent Pract* 2012; 12: 36-45.
- [50]. Van Assche N, van Steenberghe D, Quirynen M, Jacobs R. Accuracy assessment of computer-assisted flapless implant placement in partial edentulism. *J Clin Periodontol* 2010; 37: 398-403.

- [51]. Chen LC, Lundgren T, Hallström H, Chere F. Comparison of different methods of assessing alveolar ridge dimensions prior to dental implant placement. *J Periodontol* 2008; 79: 401-405.
- [52]. Jin SH, Park JB, Kim N, Park S, Kim KJ, Kim Y, Kook YA, Ko Y. The thickness of alveolar bone at the maxillary canine and premolar teeth in normal occlusion. *J Periodontal Implant Sci* 2012; 42: 173-178.
- [53]. S. Lofthag-Hansen, S. Huuonen, K. Gröndahl, and H.-G. Gröndahl, "Limited cone-beam CT and intraoral radiography for the diagnosis of periapical pathology," *Oral Surgery, Oral Medicine, Oral Pathology, Oral Radiology, and Endodontics*, vol. 103, no. 1, pp. 114–119, 2007.
- [54]. C. Estrela, M. R. Bueno, C. R. Leles, B. Azevedo, and J. R. Azevedo, "Accuracy of cone beam computed tomography and panoramic and periapical radiography for detection of apical periodontitis," *Journal of Endodontics*, vol. 34, no. 3, pp. 273– 279, 2008.
- [55]. R. Ordinola-Zapata, C. M. Bramante, M. H. Duarte et al., "The influence of cone-beam computed tomography and periapical radiographic evaluation on the assessment of periapical bone destruction in dog's teeth," *Oral Surgery, Oral Medicine, Oral Pathology, Oral Radiology and Endodontology*, vol. 112, no. 2, pp. 272–279, 2011.
- [56]. M. A. Al-Omari, A. Hazaa, and F. Haddad, "Frequency and distribution of root filled teeth and apical periodontitis in a Jordanian subpopulation," *Oral Surgery, Oral Medicine, Oral Pathology, Oral Radiology and Endodontology*, vol. 111, no. 1, pp. e59–e65, 2011.
- [57]. L. M. Paes da Silva Ramos Fernandes, R. Ordinola-Zapata, M. A. H'ungaro Duarte, and A. L. Alvares Capelozza, "Prevalence of apical periodontitis detected in cone beam CT images of a Brazilian subpopulation," *Dentomaxillofacial Radiology*, vol. 42, no. 1, pp. 8017–9163, 2013.
- [58]. A. Rajput, S. Talwar, S. Chaudhary, and A. Khetarpal, "Successful management of pulpo-periodontal lesion in maxillary lateral incisor with palatogingival groove using CBCT scan," *Indian Journal of Dental Research*, vol. 23, no. 3, pp. 415–418, 2012.
- [59]. Michael M. Bornstein, Keith Horner & Reinhilde Jacobs Use of cone beam computed tomography in implant dentistry: current concepts, indications and limitations for clinical practice and research *Periodontology* 2000, Vol. 73, 2017, 51–72.
- [60]. M.K. Nair\*† and Jaklin Bezik‡ Tuned-Aperture Computed Tomography for Detection of Induced Mid-Buccal/ Lingual Alveolar Bone Defects *jop.2006.050452*
- [61]. Tsiolis FI, Needleman IG, Griffiths GS: Periodontal ultrasonography. *J Clin Periodontol* 2003; 30: 849–854.
- [62]. Stuart C. White , Michael J Pharoah . *Oral Radiology Principles and Interpretation* 2009; 6: 109 – 244.

Anuja Muley" *Advanced Diagnostic Imaging in Periodontal Diseases: A Review*" *IOSR Journal of Dental and Medical Sciences (IOSR-JDMS)*, vol. 18, no. 5, 2019, pp 55-70.