

## Subcutaneous Onlay Laparoscopic Approach for Ventral Hernias – A Case Series

Dr P Sandeep Naidu, Dr Vishwanath Pai , Dr Khalilur Rahman ,  
Dr Saravanasundaram

Corresponding Author: Dr P Sandeep Naidu , Dr Vishwanath Pai

---

### **Abstract:**

**Background:** Ventral hernia frequent surgical condition that surgeons encounter in day to day practice. Ventral hernias include epigastric hernia, umbilical hernia, para umbilical hernia and incisional hernia. Often these cases are treated by open onlay mesh plasty or laparoscopic intraperitoneal placement of mesh or enhanced totally extra peritoneal technique. This is a case series to describe a newer technique called subcutaneous onlay laparoscopic approach(SCOLA) for the repair of the ventral hernias.

**Methods:** SCOLA was performed in 5 patients who presented with ventral hernia and followed up for 1 month to look for any post operative complications.

**Results:** Of the 5 patients who were diagnosed with ventral hernia , 3 were female 2 were male. Of the 5 patients 3 presented with umbilical hernia , 1 presented with epigastric hernia and 1 presented with incisional hernia (previous tubectomy was done). The mean age of presentation is 42.4. The mean operative time was 150minutes. Post operatively 1 patient had seroma collection. Patients were on further follow up.

**Conclusion:** Sub cutaneous onlay laparoscopic approach for the repair of ventral hernia is found to be safe , feasible , cost effective , reproducible .

**Keywords:** ventral hernia/subcutaneous onlay laparoscopic approach/surgical technique.

---

Date of Submission: 26-04-2019

Date of acceptance: 11-05-2019

---

### **I. Introduction**

Ventral hernias are one of the common condition presenting in the surgical OPD. Prior to the early 90's open method was practiced either anatomical repair alone (or) anatomical repair along with mesh placement. With the advent of prosthesis placement for hernia repair , the recurrence rate of hernia has dramatically come down(1). In 1993 pioneers including Leblanc, booth, Heniford, Park, Ramshaw, and Voeller subsequently introduced the laparoscopic approach to ventral hernia repair (2,3). Laparoscopic ventral hernia repair(LVHR) involves various methods like intra peritoneal placement of mesh(polypropylene mesh). LVHR has excellent results but it has its own complications like omental adhesions leading to adhesive colic , adhesive obstruction , enteocutaneous fistula (4,5). This study provides the details of the surgical technique , post operative complications , advantages of the procedure and early results.

### **II. Methodology**

This study was conducted during the period between Jan 2019 and Feb 2019 at Saveetha medical college , Chennai. Out of 12 patients who presented with ventral hernia to the surgical OPD 5 patients who met the inclusion criteria were taken into the study. Of the 5 patients with ventral hernia 1 is epigastric hernia, 3 were umbilical hernia , 1 is incisional hernia. SCOLA technique was performed in these 5 patients and followed up post operatively for 1 month.

#### **Inclusion criteria:**

- Presence of primary ventral hernia with hernia defect less than cms.
- Patients who were fit for general anaesthesia.5
- ASA grade 1 and 2.
- Reducible hernias
- Patients who were willing for laparoscopy.

#### **Exclusion criteria:**

- Recurrent ventral hernias.
- Defect >8cms.

- Not fit for general anaesthesia.
- ASA grade 3 and 4.
- Irreducible hernias.
- Defect size > 5cms.

#### **Surgical technique:**

This procedure was performed under general anaesthesia. At the time of induction all patients received antibiotic prophylaxis. Patient was placed in supine position with the surgeon standing at the head end for the ventral hernias of the lower abdomen and at the hip, for the ventral hernias of the upper abdomen. For the ventral hernias of the lower abdomen 15mm incision placed 7cms above the umbilicus, subcutaneous tissue opened using monopolar till anterior rectus sheath is seen. By the use of retractors flap is raised between the subcutaneous tissue and anterior rectus sheath both anteriorly and laterally for the placement of 5mm working ports on either side of the 12mm camera port. After raising adequate flaps camera was inserted through the 12mm port and CO<sub>2</sub> insufflated until the pressure raises upto 8 to 10mmhg followed by insertion of 5mm working ports. Using monopolar hook or scissors further flaps are raised between the subcutaneous tissue and anterior rectus sheath (fig 1). After identification of the hernial defect adequate flaps has to be raised all around the defect (fig 2). Hernial defect is closed primarily using the 2-0 prolene. Selection of the size of the mesh depends on the hernia defect size and number of defects. After preparation of the mesh, it was delivered into the operative field through the 12mm port. Mesh is laid open and adjusted all around the defect and fixed to anterior rectus sheath with 2-0 prolene (fig 3). 16F suction drain was placed over the mesh and brought out through one of the 5mm port and fixed. Ports were taken out and port sites were closed. Post operatively drains were retained till it drains less than 20ml for two consecutive days.

#### **III. Results**

Out of the 5 cases in whom SCOLA was performed 3 were female, 2 were male with a mean age of 43.4. 4 cases were having single defect for whom one 15\*15cms mesh is used and one patient is having two defects which are 5cms apart from each other, for this patient two mesh (one 15cms\*15cms and one 15cms\*10cms) were used. The mean operative time was found to be 150minutes. No case has been converted into open. There are no intra-operative complications. Post operatively one patient developed seroma collection which has been aspirated once. Further patients are under follow up.

#### **IV. Discussion**

Ventral hernia is defined as the fascial defect in the anterior abdominal wall. It is of two types. Primary ventral hernia and secondary ventral hernia. Primary ventral hernia include epigastric hernia, umbilical hernia, lumbar hernia. Secondary ventral hernias include all incisional hernias that were secondary to primary surgery (5). Ventral hernias can also be irreducible, obstructed and strangulated that increase the morbidity of the patient (5). These are often associated with diastasis of rectus muscle (6).

Various surgical options available for the repair of ventral hernias include open onlay mesh plasty, laparoscopic intra peritoneal onlay mesh and newer methods like enhanced view totally extraperitoneal repair (e-TEP) and sub cutaneous onlay laparoscopic approach (SCOLA) (2,3,4,5).

Although open onlay mesh plasty is the most commonly performed technique for the ventral hernia. It has many disadvantages and very few advantages over laparoscopy (1,7). The disadvantages like large skin incision, prolonged post operative pain and immobilisation of the patient, high rate of seroma collection, wound dehiscence, long hospital stay for the patient. When compared to the laparoscopic repair recurrence rate is higher in open procedures (1,7,8). The advantages of this procedure over laparoscopy is technically easy, cheaper mesh can be used and most of the cases are done under spinal anaesthesia with or without epidural anaesthesia avoiding the complications of general anaesthesia (7,8).

Laparoscopic ventral hernia repair that was introduced by Leblanc et al in early 1990's has revolutionised the surgical technique of ventral hernia repair (2). This is a minimal invasive procedure and always safe in experienced hands. The advantages of LVHR are low recurrence rate, minimal wound complications and early return to the work (9).

Intra peritoneal placement of mesh in laparoscopic IPOM has its own complications like bowel or omental adhesions leading to post operative adhesive colic, adhesive obstruction due to kinking of the bowel and bowel fistulation when polypropylene or polyester mesh were used intraperitoneally (9). To counter these complications new PTFE mesh were introduced which promote the tissue growth from the parietal side and minimise these complications. But PTFE mesh has disadvantages like, it is not a see through mesh and it is much expensive compared to polypropylene mesh (9).

To overcome these complications associated with IPOM, trans abdominal pre peritoneal approach has been introduced in which a thin peritoneal flap is raised contents reduced and sac excised or ligated, mesh

fixed in the preperitoneum and peritoneal flap closed. But most of the times while raising a thin **peritoneal flap** , we end up in peritoneal tear which may again result in exposure of the mesh to the peritoneal contents and leading to complications discussed with IPOM(10).

There is an other approach for the ventral hernia repair that is enhanced view totally extra peritoneal repair. In this technique surgeons uses the retro rectus space . Although the complications mentioned in the earlier procedures are avoided , this technique is complex and requires greater anatomical knowledge and laparoscopic skills than Onlay techniques(6).

Coming to the SCOLA , this surgical technique uses the plane that is used in open onlay mesh plasty. It has all the advantages of laparoscopy like minimal scar, minimal pain , minimal recurrence rate completely avoiding the intra abdominal complications and less hospital stay. Regular polypropylene mesh can be used for fixation. In our particular study out of 5 patients who has undergone SCOLA one patient had seroma collection that was aspirated once.

#### **Drawbacks :**

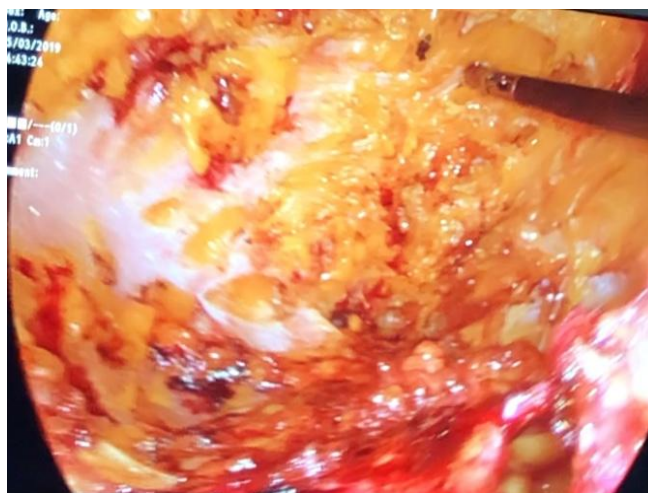
There were few drawbacks in the study that includes the number of cases taken up for study is small and period of postoperative follow up is very less.

### **V. Conclusion**

SCOLA was observed to be safe, cost effective and reproducible procedure.

### **References**

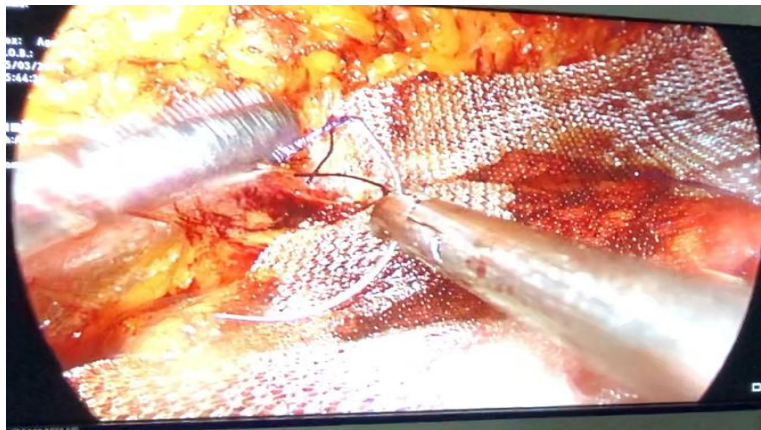- [1]. M.Miserez , F.Penninclair. endoscopic totally pre peritoneal ventral hernia repair . surgical technique and short term results.
- [2]. Leblanc KA , Booth WV(1993) Laparoscopic repair of incisional abdominal hernias using expanded poly tetra fluoro ethylene mesh. Priliminary findings.
- [3]. Heniford BT, Ramshaw BJ et al (2003) Laparoscopic repair of ventral hrnia , nine years experience with 850 consecutive cases.
- [4]. Wake B.L , Mc Cormack K , Fraser C et al (2005) transabdominal preperitoneal vs totally extraperitoneal laparoscopic technique for inguinal hernia repair.
- [5]. Shaikh afzal rubby , Purushothaman rangaswamy , Praveen sundar – A prospective study comparing laparoscopic and open ventral hernia repair.
- [6]. Christiano Marlo Paggi Claus , Favio malcher , [...]and Rodrigo Garcia: Subcutaneous onlay laparoscopic approach (SCOLA) for ventral hernia and rectus abdominis diastasis repair: technical description and initial results.
- [7]. Yamanur P. L amani, Subhash N Halbhavi , Bheemagowda V. Goudar , Eshwar B. Kalaburgi, Veerabhadra Gowd Y.C. :Openmesh repair, is still a standard technique for incisional hernia: a comparision study between sublay and onlay technique in the era of laparscopy.
- [8]. Leber GE , Garbdl , Alexander Al, Reud W.P(1998). Long term complications associated with prosthetic repair of incisional hernias. Arch Surg 133; 378-382.
- [9]. Pradeep k chowbey, MS, MNAMS, FIMSA, FAIS, FICS, Anil Sharma, MS, FICS, FRCS, Rajesh Khullar , MS FICS, Vandana Soni , MS and Manish Baijal, DND, MNAMS : Laparoscopic ventral hernia repair with extraperitoneal mesh.
- [10]. Igor Belyansky . Jorge Daes . Victor Gheorge Radu. Ramana balasubramanian. Et al : A novel approach using the enhanced view totally extraperitoneal (eTEP) technique for laparoscopic retromuscular hernia repair.



**Fig 1 :-** Shows raising of sub cutaneous flaps.



**Fig 2 :-** Defect closure with 2-0 prolene



**Fig 3 :-** Shows mesh fixation.

Dr P Sandeep Naidu “Subcutaneous Onlay Laparoscopic Approach for Ventral Hernias – A Case Series.” IOSR Journal of Dental and Medical Sciences (IOSR-JDMS), vol. 18, no. 5, 2019, pp 04-07.