

## Mini-Implant Supported Intrusion of Maxillary Incisors in A Deep Bite Case – A Case Report

Prof. Sanjeev Kumar Verma<sup>1</sup>, Dr. Yumna Qamar<sup>2</sup>, Dr. Shubhra Pathak<sup>3</sup>

<sup>1</sup>(Department of orthodontics and dentofacialorthopaedics, DrZiauddin Ahmad Dental College/ Aligarh muslim University, India)

<sup>2</sup>(Department of orthodontics and dentofacialorthopaedics, DrZiauddin Ahmad Dental College/ Aligarh muslim University, India)

<sup>3</sup>(Department of orthodontics and dentofacialorthopaedics, DrZiauddin Ahmad Dental College/ Aligarh muslim University, India)

\*Corresponding author: Prof. Sanjeev Kumar Verma I

**Abstract:** This case report describes the diagnosis and treatment of a 15 year old skeletal Class I male patient. The patient was treated by using 2 step retraction procedure where initial retraction of canine was done using closed coil Ni-Ti spring and later on the maxillary incisors were retracted with the help of T-loop. Along with retraction, deep bite in the patient was corrected using and placing mini-implants in the maxillary anterior region. The total time duration of the treatment was 30 months where simultaneous intrusion and retraction was performed using T-loop and mini-implants.

**Keywords:** Orthodontics, Orthodontic management, Skeletal Class I malocclusion, Non-extraction approach, 2 step retraction procedure, T-loop, mini-implants supported intrusion

Date of Submission: 02-05-2019

Date of acceptance: 16-05-2019

### I. Introduction

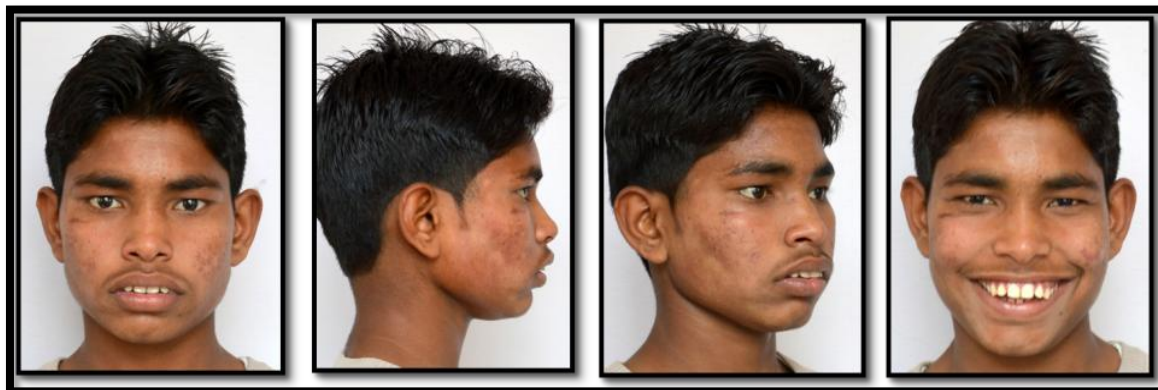Esthetics is the main concern of a person for which he or she visits a dentist. These esthetics are compromised because of malocclusion<sup>1</sup> which can be either dental or skeletal or both.<sup>2</sup> According to Angle, depending on molar relation, malocclusion can be divided in to Class I malocclusion, Class II malocclusion and Class III malocclusion. It is present in every society but with variable prevalence.<sup>3,4</sup> Depending on the severity, it can either cause functional problem or esthetic problem along with the psychological disturbances. Class I malocclusion which is characterized by the Class I molar relation may or may not be associated with the proclination of teeth and deep bite. If space is present in the arch then the treatment can be completed without extraction by consolidating the spaces and adjusting the anteriors in those spaces while if there are no spaces then extraction of teeth becomes necessary. Deep bite is a common orthodontic problem that may have deleterious effects on both TMJ and facial esthetics.<sup>5</sup> Its non-surgical correction includes either extrusion of posteriors or intrusion or anteriors or both, depending on certain factors like divergence of the patient, smile line, incisal display etcetera (Lindauer et al, 2005 ). For example, intrusion of anteriors is recommended in patient having increased or normal vertical height and high smile line which can achieved with the help of conventional methods such as RCS wires, intrusion arches etcetera however their efficacy is limited due to undesirable flaring and extrusion of posteriors.<sup>6</sup> The newer method that is being used now-a-days and can effectively cause true intrusion include placement of mini-implants in the anterior segment for true intrusion of anteriors which can intrude the maxillary incisors by about 2mm without causing adverse effects on the posteriors.<sup>7, 8, 9</sup> Various studies have advised the use of mini-implants for both retraction of anteriors in the extraction space and for intrusion of anteriors for correction of deep bite and gummy smile in both maxillary and mandibular arches successfully.

**Aim of this case report is to show the effective treatment of a Skeletal Class I patient with proclination and spaces in maxillary anteriors by a non-extraction approach using mini-implants for deep bite correction in anteriors.**

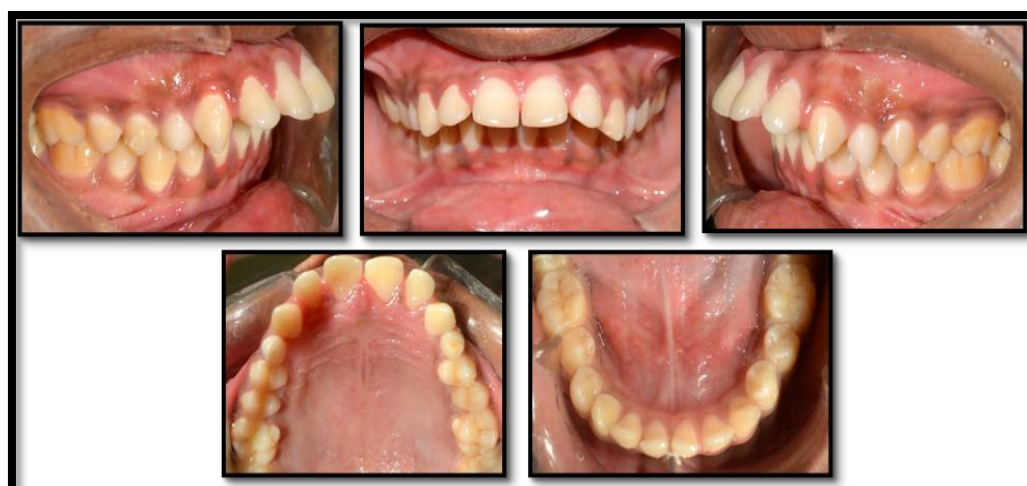A 15 years old male patient reported to the department of orthodontics and Dentofacial orthopedics with the chief complain of forwardly placed upper front teeth. Hisfamily, medical and dental histories were non-contributory and his temporomandibular joint was absolutely fine with no signs of dysfunction. Pretreatment extraoral features revealed apparently symmetrical, mesocephalic head form with mesoprosopic facial pattern, convex profile with incompetent lips and lip trap(**Fig. 1**). Smile of the patient was asymmetrical with gummy smile showing increased gingival and incisal display on smiling and the buccal corridors were

obliterated showing a broader maxillary arch of the patient. Lateral view revealed normodivergent growth pattern and prognathic maxilla and proclined incisors as the reason for convex profile.

His intraoral features revealed full cusp Angle's Class I molar relation bilaterally and Class II Canine relation bilaterally with retained C in both I<sup>st</sup> and II<sup>nd</sup> quadrants and spaces in both the arches. The arches were symmetric 'U' shaped with proclined and protruded incisors in the upper arch, hence, giving an overjet of 13 mm and overbite of 80%. The periodontal condition of the patient was good with discordant midline showing a shift of lower midline by 1.5 mm to right side (**Fig. 2**).



**Fig. 1** – Pre-treatment Extraoral photographs



**Fig. 2** – Pre-treatment Intraoral photographs

The panoramic radiograph demonstrated permanent dentition stage with developing 3<sup>rd</sup> molar buds in all the quadrants and retained C in 1<sup>st</sup> and 2<sup>nd</sup> quadrants (**Fig. 3**). Lateral Cephalogram of the patient revealed CVMI-Stage III with skeletal Class I based demonstrated by ANB of 3° and Wits of 2 mm with SNA of 86° and SNB of 83° (**Fig. 4**). Patient had a normodivergent growth pattern with Frankfort –Mandibular plane angle of 24° and SN-MP angle of 30° with proclined and protruded maxillary incisors having U1-NA 12mm/49° and proclined mandibular incisors shown with the value of L1-NB of 7.5mm/35° (**Fig. 5**). The soft tissue profile of the patient was also protrusive with reduced naso-labial angle of 74° and protruded upper and lower lips in relation with E line with a value of 3.5mm and 5mm respectively.

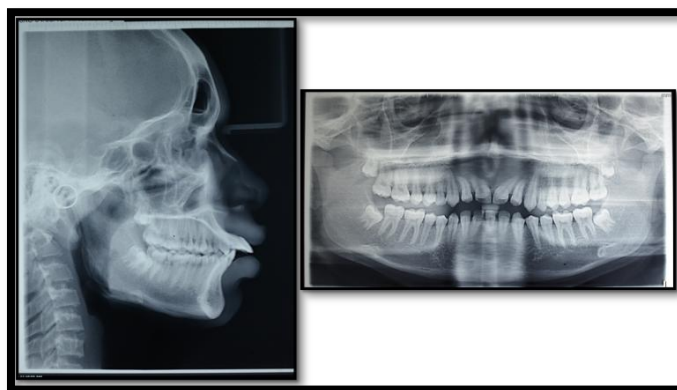


Fig. 3 – Pre-treatment radiographs (Lateral Cephalogram and OPG)

	pre	post	
<b>SNA</b>	86 °	86 °	
<b>SNB</b>	83 °	82 °	
<b>ANB</b> (3.12°±1.8°)	3 °	4 °	
<b>Wits</b> (-0.01mm)	3 mm	3 mm	
<b>APP- BPP</b> (5mm)	3mm	3.5mm	
<b>MM bisector</b> (-5mm)	-4mm	-4 mm	

Fig. 4 – Cephalometric findings showing Pre-treatment Skeletal Class I base

<b>FMA ( 23.83±2°)</b>	24°	24°		
<b>SN-MP (32-35°)</b>	30°	31°		
<b>Y Axis (59.62±3)</b>	60°	60°		
<b>Bjork's sum (394°)</b>	(124+141+122)=387°	(127+137+124)=388°		
<b>J ratio ( 59-63%)</b>	69%	70%		
<b>Gonial angle (123±7°)</b>	122°	124°		
<b>Upper anterior facial height (45%)</b>	43%	45%		
<b>Lower anterior facial height (55%)</b>	57%	55%		

<b>Mx 1 to A-Pg:</b> 6.74±1.3mm	14mm	8mm		
<b>Mx 1 to NA:</b> 4.92±2.05mm	12 mm	5 mm		
<b>Mx 1 to NA:</b> 24.02±5.82°	49°	23°		
<b>Mx 1 to Palatal Plane</b> ( 71°)	38°	67°		
<b>Md 1 to A-Pg ( -2mm to 2mm)</b>	5.5 mm	3 mm		
<b>Md 1 to NB (6±1.7mm)</b>	7.5mm	7.5mm		
<b>Md 1 to NB (27±4.3 °)</b>	35°	33°		
<b>IMPA (101°)</b>	105 °	107 °		
<b>Inter-incisor Angle (123°)</b>	92 °	118 °		

Fig. 5 – Cephalometric findings showing Normdivergent growth pattern and pre-treatment protruded and proclined maxillary anteriors

**Treatment objectives were to**

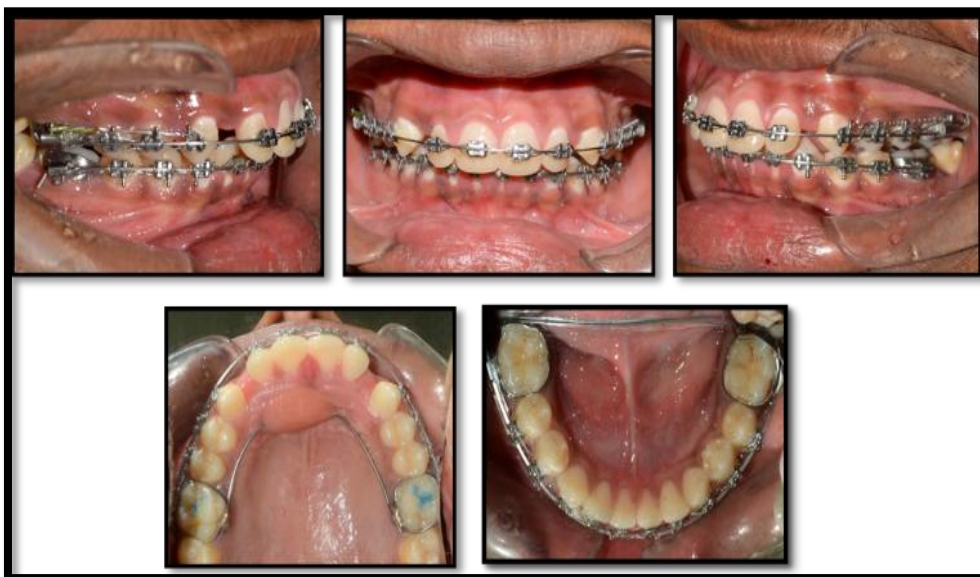- Maintain Class I molar relationship bilaterally
- Achieve Class I canine relationship bilaterally
- Extraction of retained C in the maxillary arch
- Correction of protruded and proclined maxillary anteriors
- Align and level the maxillary and mandibular dental arches
- Consolidation of spaces
- Obtain normal overjet and overbite
- Correction of protruded lips and to attaining optimum soft tissue relationship

### **Treatment plan**

Use of Non-extraction fixed orthodontic mechanotherapy was planned with the removal of retained canines to correct the protruded and proclined incisors, increased overjet and to achieve proper lip competency. Soft tissue balance was achieved by retraction of anteriors in the space present in maxillary arch while simple leveling and alignment was done in mandibular arch. Mini-implant was used in the upper arch for correction of deep bite.

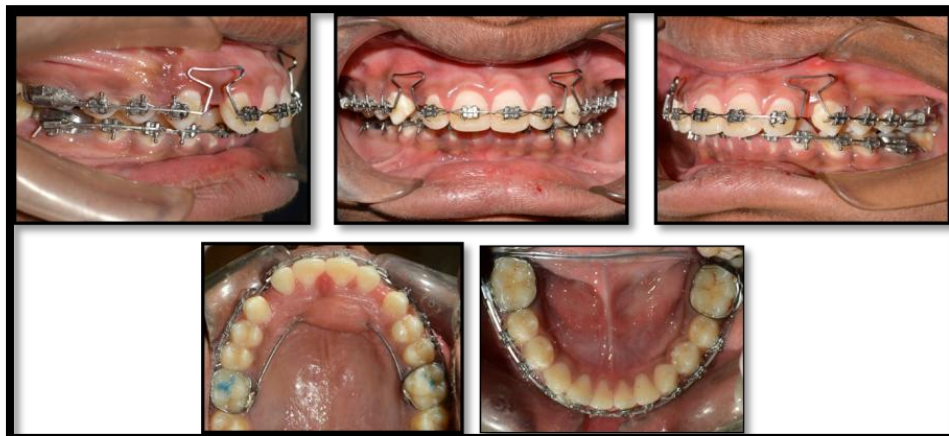### **Treatment progress**

Treatment started off with a pre-adjusted MBT straight wire appliance with 0.022 × 0.028" slot. Banding in both the arches was done and MBT brackets with 0.022 × 0.028" slot were fitted in the patient's mouth. Extraction of retained canine was performed in the maxillary arch and first phase of the treatment, that is, leveling and Alignment was started with a series of Nickel-Titanium round and rectangular wires followed by stainless steel rectangular wires like 0.016" nickel-titanium, 0.018" Nickel titanium, 0.020" Nickel titanium, 0.017×0.025" nickel titanium, 0.019×0.025" nickel titanium and 0.019×0.025" stainless steel arch wires. All these wires were cinched distal to molar and a tight figure of 8 using ligature wire was done to avoid any kind of further proclination. Meanwhile leveling and alignment was carried out in the lower arch. After the completion of alignment in maxillary arch, at 19 x 25" stainless steel retraction of canine in the extraction space was started with the help of sliding mechanics using Closed coil Ni-Ti spring of 9 mm length (Fig. 6). Space was given for anchorage to avoid any kind of anchor loss. Canine was retracted individually for about 5 months and after complete retraction, a unit of canine premolar and molar was made and retraction of 4 incisors against the above mentioned unit was started with the help of T-loop (Fig. 7). To facilitate intrusion along with retraction, the anterior arm of T-loop was kept smaller and a mini-implant (1.3mm x 6mm) was placed in between the roots of maxillary central incisors at the level of attached gingiva. E-chain was attached to the mini-implant connecting T-loop to facilitate intrusion. Simultaneous retraction and intrusion was carried out for 6 months as a result of which overjet reduced to 3mm and overbite reduced to 30%. Finally after all the corrections, finishing and detailing phase was carried out using flexible round wire and settling elastics. A panoramic radiograph was taken to evaluate the angulation of roots and after getting satisfactory results the patient was debonded after a period of 30 months. At the end of the treatment Class I molar relationship was maintained and Class I canine relation was achieved with no undesirable effects on the posteriors due to intrusive mechanics (Fig. 8).

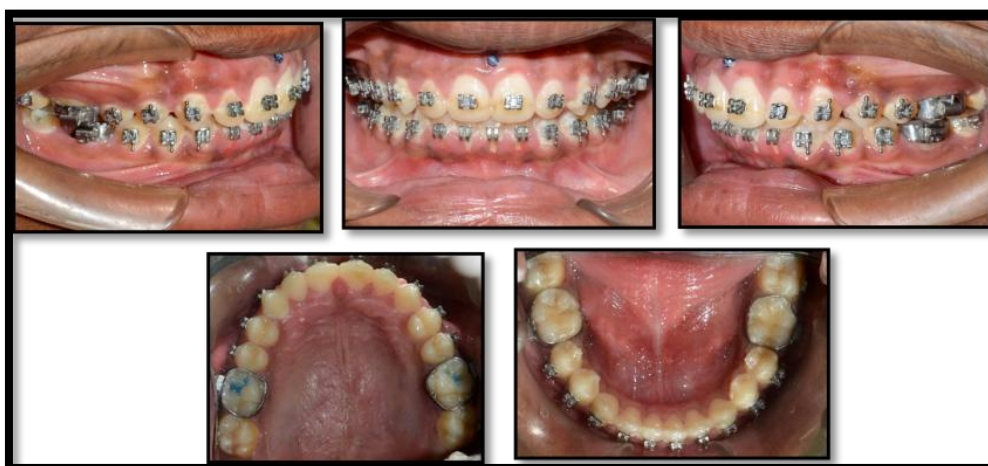

**Fig. 6** – Retraction of individual canine using Closed coil NI-Ti spring of 9 mm

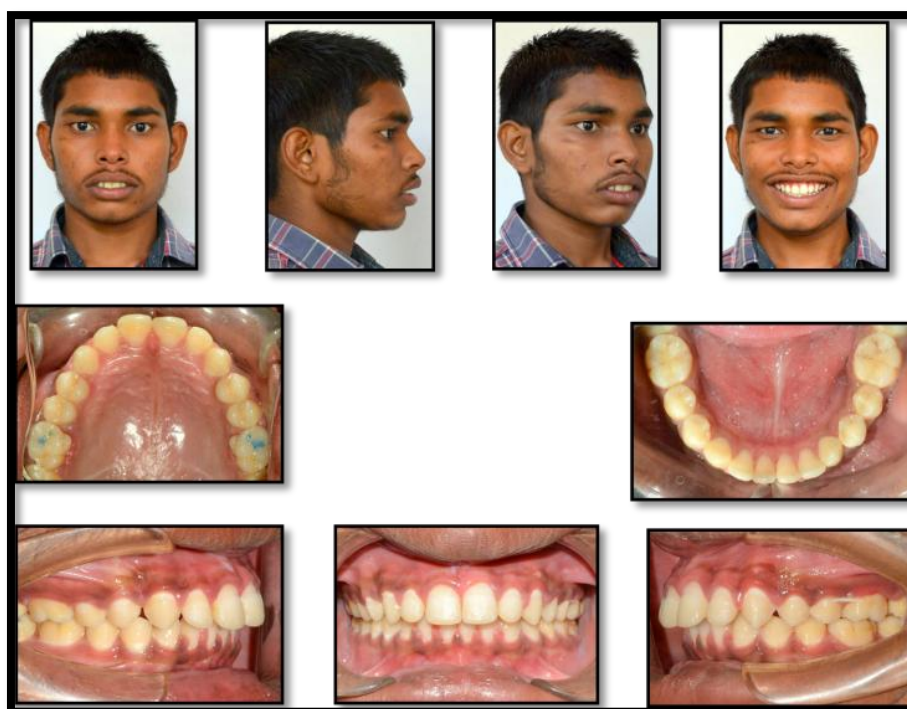




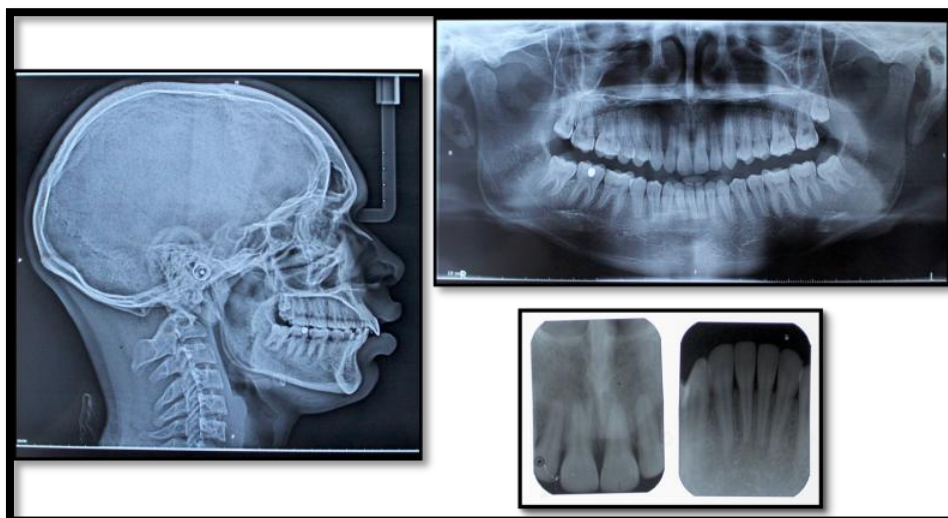
**Fig. 7** – Retraction of maxillary incisors using T-loop



**Stage record showing retracted anteriors in the space and correction of deep bite using mini-implants**

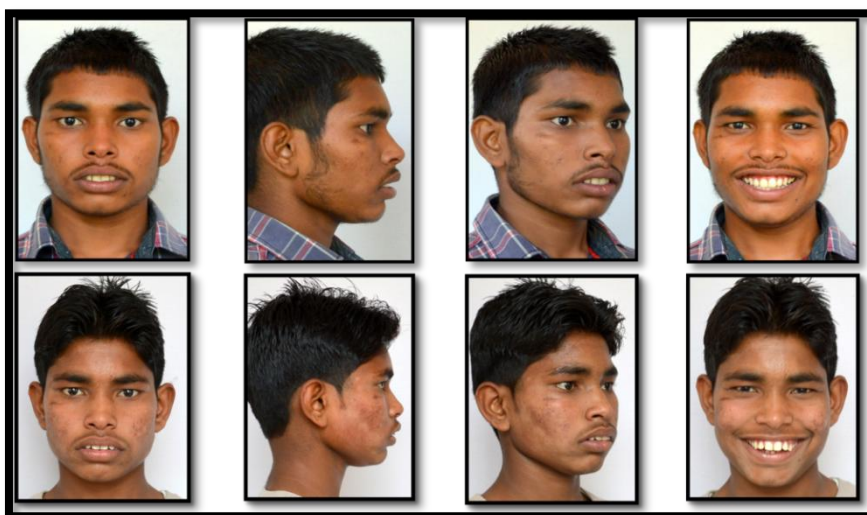

**Fig. 8** – Post treatment photographs

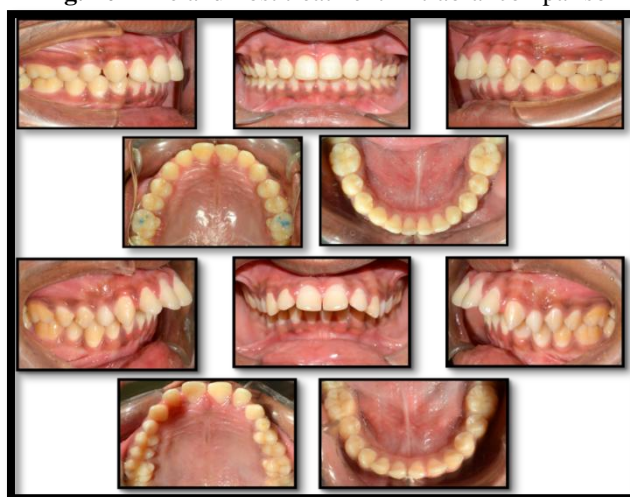

**Fig. 9** – Post treatment radiographs

Retainers were given after debonding with a removable wraparound Hawley retainer in the maxillary arch and a fixed canine-to-canine bonded lingual retainer in the lower arch. The patient is kept on follow up and is recalled once a month for evaluation and retainer tightening.



**Fig. 10** – Pre and Post treatment Extraoral comparison



**Fig. 11** – Pre and Post treatment Intraoral comparison

## II. Discussion

Class I malocclusion is the most common malocclusion in Indian population. It consists of Class I molar relationship bilaterally with crowding, spacing or bimaxillary protrusion. Depending on the severity of malocclusion extraction can or cannot be performed, but in both the cases the final motto is to give good function, stability and esthetics to the patient. Good esthetics helps in increasing both self-confidence and self-esteem of the patient in the society. Deep bite is again a complex yet very common problem seen in the human population that has a tendency to relapse. Its treatment can be done either surgically or non-surgically depending on the severity. Non-surgical treatment depends on either extrusion of posteriors or intrusion of anteriors or both using various conventional and recent modalities. The recent and most common way of correcting deep bite is by using mini-implants.

Our patient was a skeletal Class I patient with ANB of 3° and proclined and protruded maxillary anteriors with generalized spacing in both maxillary and mandibular arches. The molar relation was already Class I but the canine relation was Class II due to presence of retained deciduous canines in both 1<sup>st</sup> and 2<sup>nd</sup> quadrants. Space obtained by extraction of retained canines added to the generalized spacing in the arch helped us in retracting the anteriors and obtaining a normal overjet and overbite. Space was utilized for both retraction and intrusion of anteriors of the maxillary arch as a result of which, upper incisor to NA reduced from 12mm/49° to 5mm/23° while lower incisor to NB remained almost constant with the value of 7.5mm/35° and 7.5mm/33°. Friction mechanics was used to retract canine alone while frictionless mechanics was used to retract and intrude the incisors as loop mechanics helps in vertical control by changing the length of alpha and beta arms. Along with T-loop, miniscrew that was placed between the roots of upper central incisors, was also used to intrude the incisors using E-chain. Conventional mechanics has the disadvantage of extrusion and flaring of posteriors while miniscrews don't have such disadvantages thus facilitating true intrusion and not pseudo-intrusion, hence, they have proven to be a useful addition to the orthodontist armamentarium. However, a very light force of 15-20gms per tooth is recommended for intrusion. Hence total force required to intrude the 4 anteriors should not be more than 60 gms otherwise it may lead to root resorption instead of intrusion.<sup>10,11,12</sup> Various other authors like Shaivi Sharma, Hidetake Ohnishi et al, Deepak Chandrasekharan etcetera have also advocated the successful use of mini-implants in intrusion but the amount of force should be managed very carefully otherwise the advantage of using miniscrews may turn into disadvantage thus harming the patient.

## III. Conclusion

A proper treatment plan is very essential to achieve proper form, function and esthetics. Soft tissue profile of the patient plays an equally important role on deciding the type of treatment that should be given to the patient. Newer modalities have started replacing the conventional ones, for example, use of mini-implants is continuously increasing in the field of orthodontics for both retraction and intrusion. They can also be used for molar mesialization, molar uprighting, distalization etcetera, depending on what type of movement is required. This case has explained the clinical significance of mini implants for the purpose of intrusion of maxillary incisors in a 2 step method thus eliminating any reactionary forces in the posteriors.

## References

- [1]. M. B. Ackerman, *Enhancement Orthodontics: Theory and Practice*, Wiley-Blackwell, 2007.
- [2]. J. A. McNamara Jr., "Components of class II malocclusion in children 8–10 years of age," *The Angle Orthodontist*, vol. 51, no.3, pp. 177–202, 1981.
- [3]. J. Y. C. Wu, U. H'agg, H. Pancherz, R. W. K. Wong, and C. McGrath, "Sagittal and vertical occlusal cephalometric analyses Orthodontics and Dentofacial Orthopedics, vol. 137, no. 6, pp.816–824, 2010.
- [4]. A. H. Hassan, "Cephalometric norms for Saudi adults living in the Western region of Saudi Arabia," *The Angle Orthodontist*, vol. 76, no. 1, pp. 109–113, 2006.
- [5]. 5) Miniscrews for upper incisor intrusion Omur Polat-Ozsoy\*, Ayca Arman-Ozcirpici \* and Firdevs Veziroglu \*\* *European Journal of Orthodontics* 31 (2009) 412–416
- [6]. Nishimura M, Sannohe M, Nagasaka H, Igarashi K, Sugawara J. Nonextraction treatment with temporary skeletal anchorage devices to correct a Class II Division 2 malocclusion with excessive gingival display. *Am J Orthod Dentofacial Orthop*. 2014;145:85–94.
- [7]. Peddu R, Mallavarapu K, Lanka D, Nuvusetty B. Implant-supported maxillary incisor intrusion. *Indian Dent Sci* 2018;10:109-12.
- [8]. Hong RK, Lim SM, Heo JM, Baek SH. Orthodontic treatment of gummy smile by maxillary total intrusion with a midpalatal absolute anchorage system. *Korean J Orthod*. 2013;43:147–158.
- [9]. Nonsurgical correction of a severe anterior deep overbite accompanied by a gummy smile and posterior scissor bite using a miniscrew-assisted straight-wire technique in an adult high-angle case Xue-Dong Wang, Jie-Ni Zhang, Da-Wei Liu, Fei-fei Lei, and Yan-Heng Zhou
- [10]. Burstone C.J., Deep overbite correction by intrusion, *AM J Orthod*, 72, 1-22 (1977)
- [11]. Nanda R., Correction of deep overbite in adults, *Dental Clinics of North America*, 41(4), 67- 81 (1997)
- [12]. Smith R.J. and Burstone C.J., Mechanics of tooth movement, *Am J Orthod*, 85, 294-307 (1984).

Prof. Sanjeev Kumar Verma<sup>1</sup> "Mini-Implant Supported Intrusion of Maxillary Incisors in A Deep Bite Case – A Case Report." *IOSR Journal of Dental and Medical Sciences (IOSR-JDMS)*, vol. 18, no. 5, 2019, pp 26-32.