

## Mandibular Parasymphysis Fracture and Its Management: A Case Report

Dr. Partha Sundar Biswas<sup>1</sup> Dr. Ishita Das Mahapatra<sup>2</sup> Dr. Tathagatha Ghosh<sup>3</sup>  
Dr. Sanjay Kr. Upadhyay<sup>4</sup>

<sup>1</sup>MDS in oral and maxillofacial surgery, Clinical Tutor/Demonstrator IPGMER & SSKM HOSPITAL Kolkata West Bengal

<sup>2,3,4</sup>BDS, Housestaff in Department of Dentistry, IPGMER & SSKM Hospital

**Abstract:** In recent years, increase in occurrence of road traffic accidents due to avoidance & ignorance of traffic safety rules, self fall due to suicidal tendency, assaults due to interpersonal violence, professional hazards due to poor working conditions etc. resulted in increase in number of mandibular fractures. Though there is various treatment modalities in respect to immobilize the fracture segment but open reduction and rigid or nonrigid fixation by miniplate or Primary reconstruction plate as per Champys guideline is the best possible way for parasymphysis fractures.

Date of Submission: 13-07-2019

Date of acceptance: 29-07-2019

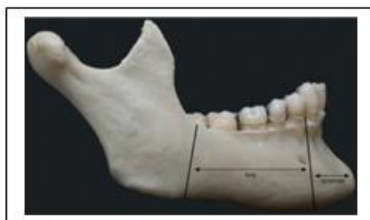### I. Introduction

In the era of increasing automobilization and industrialization, the treatment of mandibular fractures has attained a prominent position. Mandible is a corticocancellous bone and constitutes the strongest and most rigid component of the facial skeleton, second most commonly fractured part of the maxillofacial skeleton, a fact directly related to its prominence and exposed situation.<sup>1,2,3</sup>

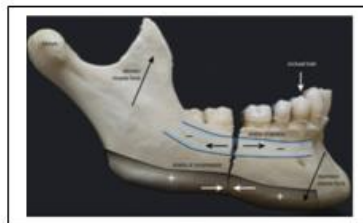
The Goal of the treatment of mandible fracture should be to return the patient to a preinjury state of function and esthetics, restore proper function by ensuring union of the fractured segments and reestablishing preinjury strength; to restore any contour defect that might arise as a result of the injury; and to prevent infection at the fracture site.

### II. Incidence Of Parasymphysis And Body Fracture

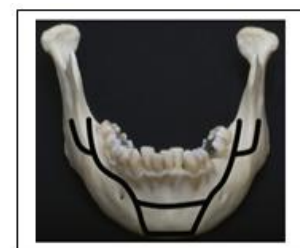Using the classification by Dingman and Natvig,<sup>2</sup> the region of the symphysis is bound by vertical lines just distal to the lower canine teeth. Fractures in this location are also commonly referred to as parasymphyseal. The region of the body comprises the mandible from the canine line to a line coinciding to the anterior border of the masseter muscle.



Anatomical interpretation of parasymphysis<sup>14</sup>



Zone of tension & compression<sup>14</sup>



Champys osteosynthesis line<sup>14</sup>

### III. Biomechanics

From a biomechanical aspect, the mandible represents two Class III levers joined in the midline with the fulcrum at the summit of each condyle, muscle force is applied distal to the fulcrum, and occlusal force is applied distal to the muscle force. Understanding of the muscle attachments and forces imposed on the mandible are useful in assisting the surgeon when planning treatment. Champy and colleagues<sup>12</sup> used this biomechanical approach when describing the ideal lines of osteosynthesis. In the body of the mandible, the masticatory forces create strains of tension along the alveolar bone superior to the mandibular canal, and compression strains along the inferior border of the mandible. With a fracture in the mandibular body, the zone of compression is

favorable in maintaining bony contact; however, the zone of tension strives to pull the bone apart. This force must be neutralized when applying fixation. In the anterior mandible there are moments of torsion that are highest in the mandibular symphysis. According to Champy and colleagues, in symphysis the placement of 2 miniplates separated by 4 to 5 mm is necessary to neutralize the moments of torsion.

#### **IV. Treatment Option**

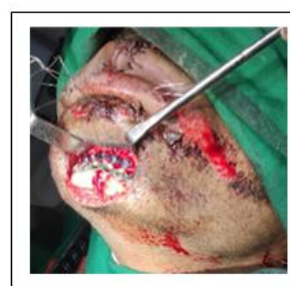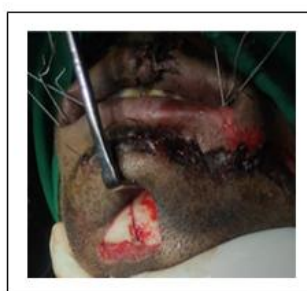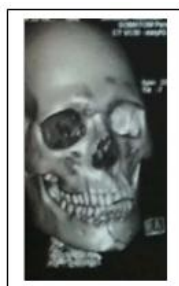Surgical treatment of Symphysis fracture of mandible can be done either by close reduction or open reduction. Closed reduction done by intermaxillary fixation with Erich arch bar fixed by 26 gauge wire or elastic. It also can be done by IMF screw placed in sound bone in the anterior and posterior vestibular regions, and provide a bone anchor for elastics or wires for IMF. Skeletal suspension wires can be placed within sound bone in the zygomatic buttress or piriform aperture region. Circummandibular wires can be placed proximal and distal to the fracture and on the contralateral side, and then secured to the maxillary skeletal fixation with connector wires.<sup>12</sup> Most adult mandibular body or parasymphysis fractures requires 4 to 6 weeks of stabilization. For those patients with minimally displaced mandibular fractures in the tooth-bearing area, 2 weeks may be sufficient.<sup>14</sup>

The objective of the internal fixation is to limit interfragmentary motion to achieve these requirements.<sup>9</sup> Healing time is directly related to the size of the gap between bone and interfragment motion. Two goals of rigid internal fixation with open reduction, are to stabilize bone fragments to minimize movement, in conjunction with having the smallest gap possible between the fracture margins.<sup>10-13</sup> Many choices for internal fixation of body and symphysis fractures are available, including lag screws, miniplates, trauma plates, and reconstruction plates. The application of any of these can be considered "rigid" fixation.

Since the 1978 publication by Champy and colleague<sup>12</sup> of 103 cases of mandibular osteosynthesis, the use of miniplates placed along the lines of osteosynthesis have been indicated as an effective treatment modality.<sup>7</sup> In the symphysis two plates are used, separated by 4 to 5 mm, to neutralize the moments of torsion. It is necessary to bend these plates so that they lie passively on bone before monocortical screws are placed. When there is lack of bony contact following fracture reduction because of bone loss or there is significant comminution, rigid plates may be placed along the inferior border of the mandible using bicortical screws. The thicker the plate, the more difficult it is to bend, so that it will lie flush with the bone on either side of the fracture. If the plate is not passively adapted to the underlying bone, the engaging of the screw will create pressure that displaces the fracture, resulting in a poor reduction and malocclusion. Moreover, the bone underlying the plate can resorb and the fixation can become loose. The introduction of locking plates and screws overcomes the need for passive adaptation. The screw locks into the plate, creating a rigid functional unit, and removes unfavorable pressure from the bone. This procedure decreases the probability of bone resorption, screw loosening, hardware failure, and fracture displacement. Lag screw and Trans osseous wiring also can be done as a treatment modality.

#### **V. Case History And Surgical Procedure**

A 23 year old male patient came to our hospital two days back with trauma to face due to road traffic accident. He was treated elsewhere for primary management of trauma and some cut injury on cheek and upper lip. On examination it was noticed that mandible fragment was mobile at right lateral incisor and canine interphase. Mild sublingual ecchymosis was noticed. Initially differential count was little bit higher so patient was admitted and treated by Intravenous antibiotic and intravenous dexamethasone for 3 days and then planned OT was done under GA. Mandible parasymphysis was exposed by an incision at submental region and after reduction and immobilization, two plate fixation done as per champys guideline. As it was an oblique fracture a properly contoured 6 hole 2.5 mm Ti ultralock plate fixed at lower border by 2.5 mm Ti cross slot screw and another 5 hole 2 mm Ti miniplate fixed at 4mm superior to previous one below the apices by 2 mm Ti cross slot screw. Suture was done in layers and skin closure done by stapler. Upper lip was repaired by 3-0 vicryl and 5-0 prolene. Pressure bandage given and postoperively fluid supplementation along with antibiotic and analgesic was given.



## VI. Conclusion

Mandible performs a number of important functions enabling a person to articulate, express, chew and eat. All of the above functions are highly important for leading a normal life. Open reduction & internal fixation remained the gold standard for the treatment of majority of the complex injuries. Conventional treatment modalities using miniplates fixation as per Champy's osteosynthesis line give good results to patient early recovery.

## Reference

- [1]. Banks P. Killip's fracture of the mandible. 4th ed. London : Wright ; 1991. p1
- [2]. Gruss JS, Phillips JH. (1989) Complex facial trauma: the evolving role of rigid fixation and immediate bone graft reconstruction. *Clin Plast Surg* : 1989 : 93
- [3]. Hobar PC (1992) Methods of rigid fixation . *Clin Plast Surg* : 19 : 31 – 39
- [4]. Madsen MJ, McDaniel CA, Haug RH (2008) A biomechanical evaluation of plating techniques used for reconstructing mandibular symphysis/parasymphysis fracture. *J oral Maxillofac Surg* 66 : 2012-2019
- [5]. Current Trends in the Management of Fracture Mandible: A Retrospective Study of 120 Cases Kaustubh Bhad<sup>1</sup> Shital Patel<sup>2\*</sup> Tushar Makwana<sup>3</sup>
- [6]. Saikrishna D, Sujeeth kumar Shetty : A comparison between 2.0mm standard and 2.0mm locking miniplates in the management of mandibular fractures. *J Maxillofac Oral Surg* 8 (2) : 145-149, (2009).
- [7]. Champy M, Lodde J, Schmitt J, et al. Mandibular osteosynthesis by miniature screwed plates via a buccal approach. *J Maxillofac Surg* 1978;6:14–21.
- [8]. Adeyemi M, Adeyemo W, Mobolanle O, et al. Is healing outcome of 2 weeks intermaxillary fixation different from that of 4 to 6 weeks intermaxillary fixation in the treatment of mandibular fractures? *J Oral Maxillofac Surg* 2012; 70(8):1896–902.
- [9]. Assael LA, Klotch DW, Manson PN, et al. Scientific and technical background. In: Prein J, editor. *Manual of internal fixation in the craniofacial skeleton*. Berlin: Springer-Verlag; 1998. p. 7–9.
- [10]. Ellis E. A study of 2 bone plating methods for fractures of the mandibular symphysis/body. *J Oral Maxillofac Surg* 2011;69:1978–87.
- [11]. Cawood JJ. Small plate osteosynthesis of mandibular fractures. *Br J Oral Maxillofac Surg* 1985;23: 77–91.
- [12]. Nakamura S, Takenoshita Y, Oka M. Complications of miniplate osteosynthesis for mandibular fractures. *J Oral Maxillofac Surg* 1994;52:233–8.
- [13]. Scolozzi P, Richter M. Treatment of severe mandibular fractures using AO reconstruction plates. *J Oral Maxillofac Surg* 2003;61:458–61.
- [14]. Management of Fractures of the Mandibular Body and Symphysis Reginald H.B. Goodday, DDS, MSc, FRCD(C), FICD Oral Maxillofacial Surg Clin N Am 25 (2013) 601–616

Dr. Partha Sundar Biswas. “Mandibular Parasymphysis Fracture and Its Management: A Case Report.” *IOSR Journal of Dental and Medical Sciences (IOSR-JDMS)*, vol. 18, no. 7, 2019, pp 07-09.